

# Lassa fever associated with effusive constrictive pericarditis and bilateral atrioventricular annular constriction: A case report

Osamu YANASE  
Takeshi MOTOMIYA  
Kohji WATANABE  
Yoshiki TOKUYASU  
Harumizu SAKURADA  
Tamotsu TEJIMA  
Yasunaga HIYOSHI  
Masaya SUGIURA  
Yukio YABATA\*  
Hiromichi KITAZUMI\*

## Summary

A case of Lassa fever associated with effusive constrictive pericarditis and bilateral atrioventricular annular constriction was reported.

A 49-year-old man, who had been diagnosed by indirect fluorescent antibody test as the first case of Lassa fever in Japan, was referred to the Hiroo Hospital because of syncope, progressive hepatomegaly, ascites and pericardial effusion in spite of pericardiocentesis and corticosteroid therapy. On admission, his blood pressure was 92/60 mmHg and he had a paradoxical pulse. Two-dimensional echocardiography revealed a localized pericardial effusion adjacent to the right ventricular wall and behind the left ventricular posterior wall. Bilateral atrioventricular annular constriction was also present. On pulsed Doppler echocardiography, the peak inflow velocities of the right and left ventricles increased during atrial systole. Right heart catheterization revealed a mean diastolic pressure gradient of 8 mmHg across the tricuspid valve. After pericardiectomy, a diastolic dip and plateau pattern became evident in the right ventricular pressure tracing, suggesting the presence of residual constriction.

---

東京都立広尾病院 循環器科  
東京都渋谷区恵比寿 2-34-10 (〒150)  
\*東京都立荏原病院 内科  
東京都大田区東雪谷 4-5-10 (〒145)

Department of Cardiology, Tokyo Metropolitan Hiroo General Hospital, Ebisu 2-34-10, Shibuya-ku, Tokyo 150  
\*Department of Internal Medicine, Tokyo Metropolitan Ebara General Hospital, Higashiyukigaya 4-5-10, Ohta-ku, Tokyo 145

Received for publication January 4, 1989; accepted May 8, 1989 (Ref. No. 36-203)

However, the atrioventricular annular constriction was no longer evident on two-dimensional echocardiography.

This is considered the first reported case of subacute effusive constrictive pericarditis caused by Lassa fever.

#### Key words

Lassa fever      Effusive constrictive pericarditis      Atrioventricular annular constriction

### Introduction

Lassa fever is an acute febrile disease first recognized in Lassa in northern Nigeria in 1969<sup>1)</sup>. It is now known to be widespread in West Africa where it is responsible for an estimated 300,000 infections and possibly 5,000 deaths a year<sup>2)</sup>. With the increased number of international travellers, the introduction of Lassa fever into other countries has become a worldwide problem<sup>3)</sup>.

Described here is the first known case of Lassa fever introduced into Japan, complicated with subacute effusive constrictive pericarditis and bilateral atrioventricular annular constriction.

### Case report

A 49-year-old engineer was admitted to the Hiroo Hospital on November 20, 1987 because of a syncopal attack, progressive hepatomegaly and ascites. On March 16, 1987, two days after returning to Japan from Sierra Leone in West Africa where he stayed for approximately two weeks, he developed a sore throat, general malaise and fever up to 38°C. He was first admitted to the Hospital of the Institute of Medical Science, University of Tokyo, and improved with medical therapy for two months. His discharge diagnosis was Lassa fever, based on an indirect fluorescent antibody test performed at the Centers for Disease Control (CDC) in Atlanta, Georgia, U.S.A.

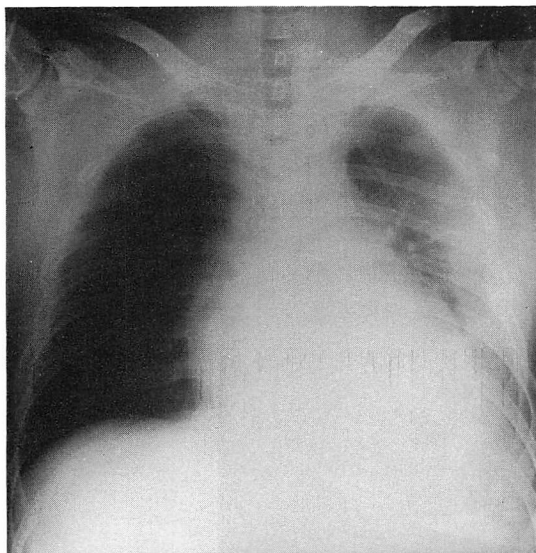
Two months after the discharge, he gradually developed general malaise, abdominal fullness, dyspnea, massive pericardial effusion and ascites. He was transferred to the Isolation Unit of Ebara Hospital on August 15, but a Lassa virus was not detected in his serum,

pericardial fluid or urine. Seroconversion to the Lassa virus was confirmed at CDC by antibody titers of 1:1280. Despite his temporary improvement after repeated pericardiocentesis and corticosteroid therapy, his main symptoms worsened in November, and he developed syncope on the day of his admission.

On physical examination, his blood pressure was 92/60 mmHg and he had a paradoxical pulse of 16 mmHg. His pulse was 112 per min, and regular. His face was edematous and his jugular veins were distended. Neither a friction rub nor a pericardial knock was audible. His liver was palpable 5 cm below the right costal margin and was tender. Ascites was also noted. Laboratory studies showed his hemoglobin to be 14.2 g/dl, white blood cells 7,900/cmm, platelets  $14.9 \times 10^4$ /cmm, serum aspartate aminotransferase 320 IU/l, serum alanine aminotransferase 314 IU/l, serum total bilirubin 3.2 mg/dl, and serum creatine kinase 62 IU/l. Blood urea nitrogen and serum creatinine were normal. Chest radiography showed the cardiothoracic ratio of 0.6 and left pleural effusion (**Fig. 1**). The electrocardiogram revealed low voltage in the limb leads, right-axis deviation, and Q waves in the precordial leads V<sub>1</sub>-V<sub>4</sub> (**Fig. 2**).

Two-dimensional echocardiography showed localized pericardial effusion behind the left ventricular posterior wall near the mitral annulus and adjacent to the right ventricular wall (**Fig. 3**). The right ventricular cavity and both the mitral and tricuspid annuli were narrowed. On pulsed Doppler echocardiography, the peak inflow velocities of both ventricles increased during atrial systole (**Fig. 4**).

Right heart catheterization showed a mean right atrial pressure of 22 mmHg; a right ven-



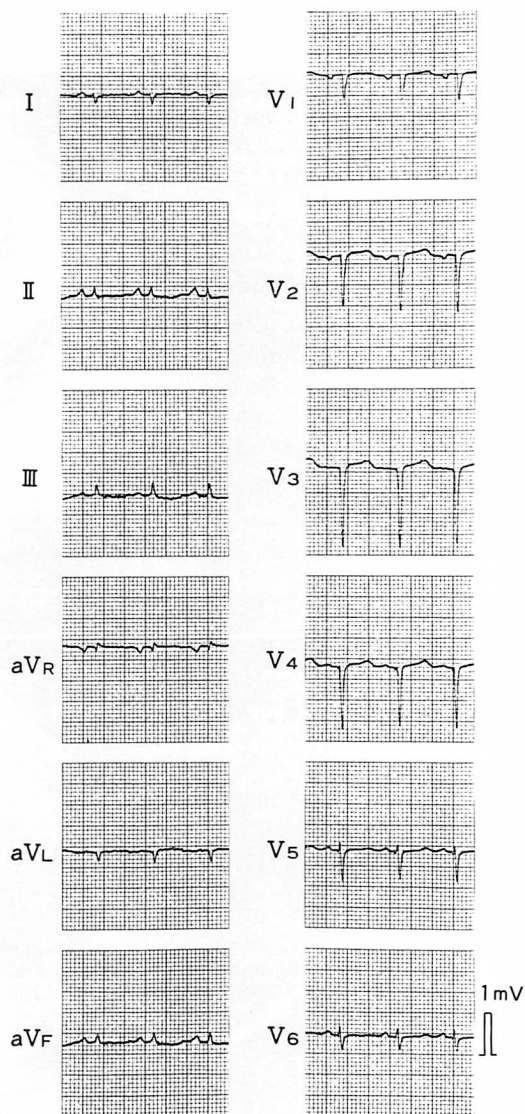
**Fig. 1. Chest radiograph on admission.**

Cardiothoracic ratio is 0.6 and left pleural effusion is seen.

tricular pressure of 29/14 mmHg; pulmonary artery pressure, 30/20 (mean 24) mmHg; mean pulmonary artery wedge pressure, 20 mmHg; and the cardiac index of 1.35 l/min/m<sup>2</sup>. There was a mean transtricuspid pressure gradient of 8 mmHg (**Fig. 5**).

Subacute effusive constrictive pericarditis accompanied by bilateral atrioventricular annular constriction was diagnosed, and pericardiectomy was performed on November 24. At surgery there was extensive thickening of the parietal and visceral pericardium up to 2 mm with some adhesions. Extensive pericardiectomy was performed and 250 ml bloody pericardial fluid was removed. Because of severe adhesion between the pericardium and myocardium, the visceral pericardium over the right side of the heart was only partially removed.

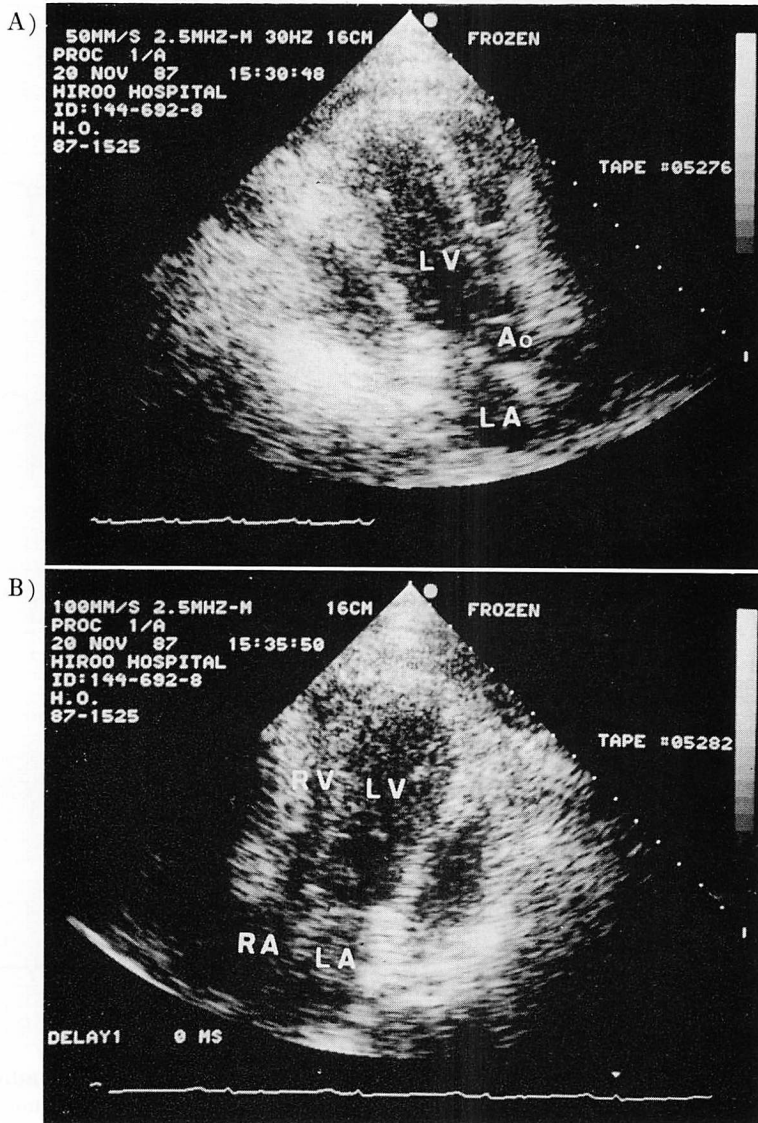
After pericardiectomy, the atrioventricular constriction was no longer evident on two-dimensional echocardiography (**Fig. 6**) and diastolic filling of the right and left ventricles was dependent mainly on early diastolic rapid filling



**Fig. 2. Electrocardiogram on admission.**

The electrocardiogram shows low voltage in the limb leads, right-axis deviation and QS pattern in the chest leads V<sub>1</sub>-V<sub>4</sub>.

on Doppler echocardiography (**Fig. 7**). Post-operative cardiac catheterization revealed a dip and plateau pattern on the right ventricular pressure tracing and a prominent y descent on the right atrial pressure tracing (**Fig. 8**).



**Fig. 3. Two-dimensional echocardiograms prior to pericardiectomy.**

A: Long-axis view: Localized pericardial effusion behind the left ventricular posterior wall and the narrowing of the mitral annulus are noted.

B: Four-chamber view: Localized pericardial effusion near the right ventricle and obliterated right ventricular cavity with narrow tricuspid annulus are also shown.

LV=left ventricle, LA=left atrium, Ao=ascending aorta, RV=right ventricle, RA=right atrium.

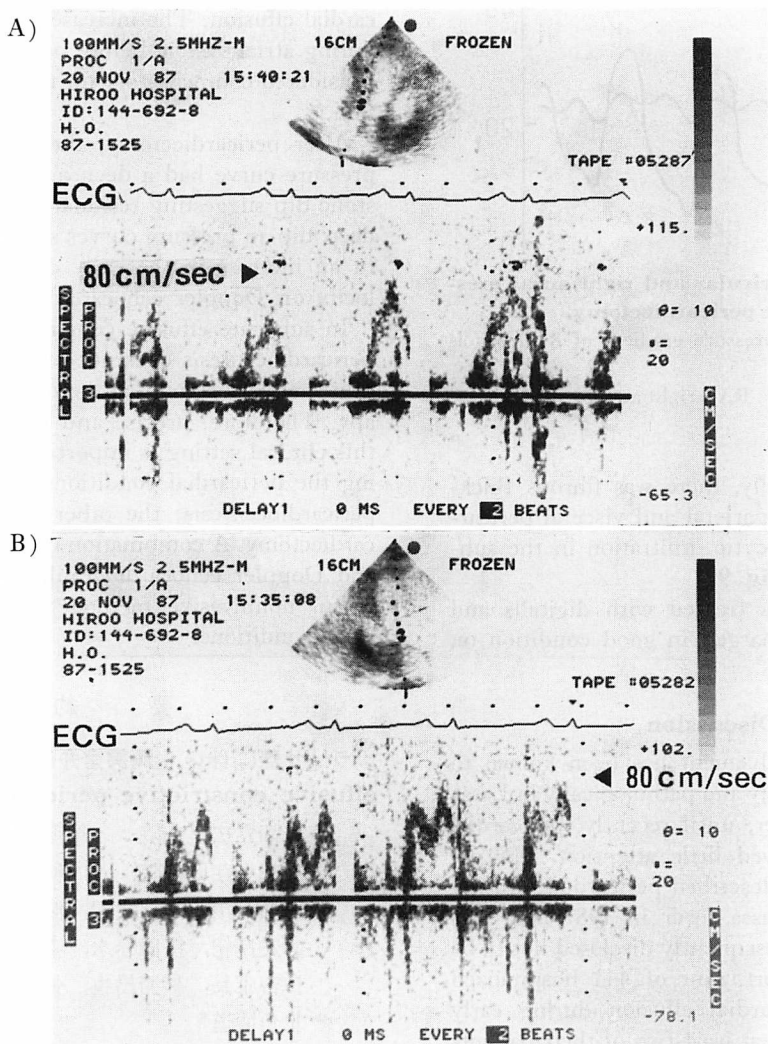
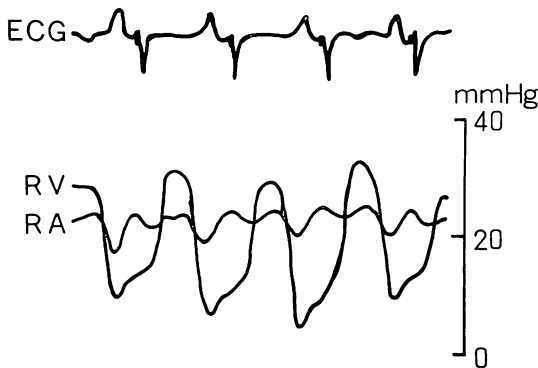


Fig. 4. Pulsed Doppler echocardiograms obtained in the ventricular inflow tracts prior to pericardiectomy.

A: Transtricuspid inflow velocity pattern shows an increase in filling velocity during atrial systole, although the rapid filling phase is not clearly defined.

B: Transmitral inflow velocity pattern shows an increase in filling velocity during atrial systole.



**Fig. 5. Right ventricular and right atrial pressure tracings before pericardiectomy.**

A mean diastolic pressure gradient of 8 mmHg is noted.

RV=right ventricle, RA=right atrium.

Histopathologically, there was fibrous thickening of both the parietal and visceral pericardium, and lymphocytic infiltration in the subepicardial tissue (Fig. 9).

The patient was treated with digitalis and diuretics and discharged in good condition on January 7, 1988.

### Discussion

Myocardial involvement has been known to be common clinically and pathologically in Lassa fever<sup>1,4,5</sup>. However, until recently, pericardial lesions have received little attention. McCormick et al.<sup>6</sup> first described pericardial effusion associated with Lassa fever in 1987, and this association was subsequently disclosed not to be rare. In their report, nine of 441 hospitalized patients had pericardial effusion during early convalescence, and at least two of their patients exhibited some evidence of tamponade with mild heart failure. However, their diagnoses of pericardial effusion were based merely on audible pericardial friction rubs.

In our case, the clinical and hemodynamic findings were compatible with subacute effusive constrictive pericarditis as first described by Hancock<sup>7</sup>. Another prominent finding was bilateral atrioventricular annular constriction re-

vealed by two-dimensional echocardiography and confirmed at surgery. This inflow obstruction seemed to be caused both by adhesive visceral pericardium and localized tense pericardial effusion. The increased inflow velocities during atrial systole before pericardiectomy are considered compensatory for the inflow obstruction.

After pericardiectomy, the right ventricular pressure curve had a deep and steep early diastolic dip suggesting residual constriction. This deep dip in pressure curves seems to be related to an increase in the early diastolic filling velocity on Doppler echocardiography.

In subacute effusive constrictive pericarditis, pericardiocentesis does not relieve the constriction; pericardiectomy is the only effective therapy. Therefore, precise and early diagnosis of this clinical setting is important in distinguishing the pericardial conditions; one relieved by pericardiocentesis; the other relieved by pericardiectomy. A combination of two-dimensional and Doppler echocardiography seems to be a useful noninvasive method for distinguishing these conditions.

### 要 約

ラッサ熱に伴い、両房室弁輪部狭窄を呈した **effusive constrictive pericarditis** の1症例

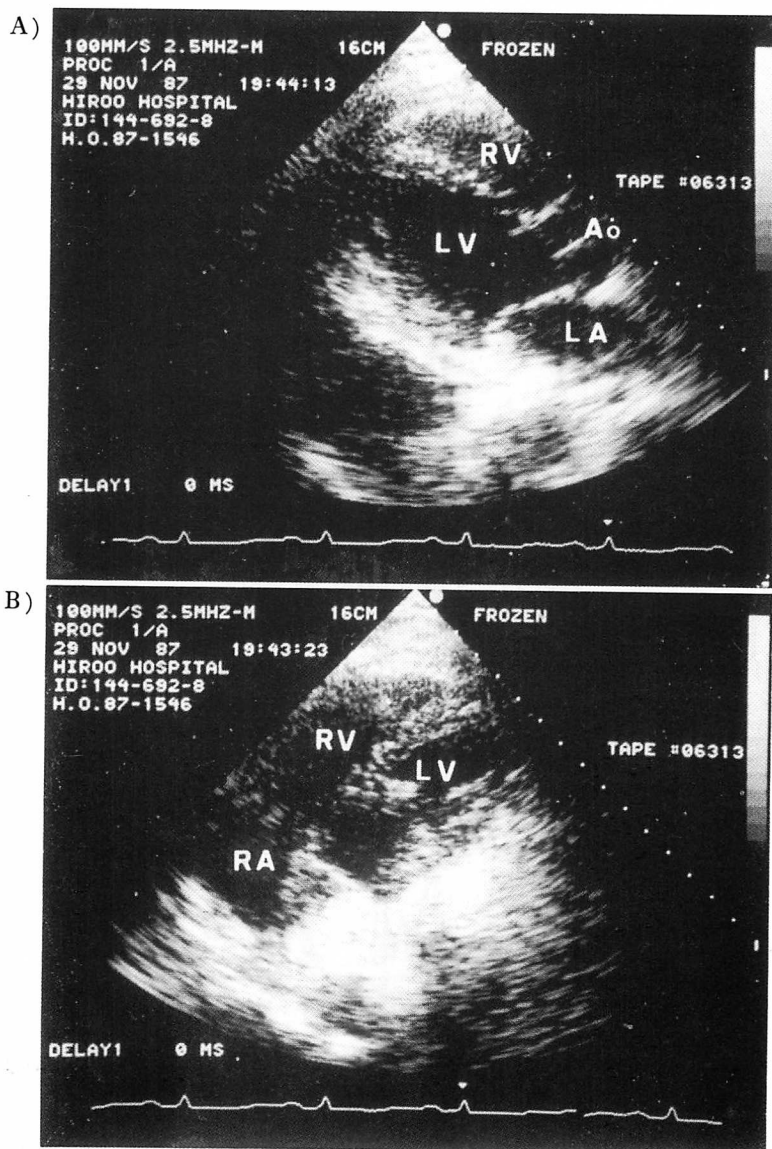
東京都立広尾病院 循環器科

\*東京都立荏原病院 内科

柳瀬 治, 本宮武司, 渡辺浩二,  
徳安良紀, 桜田春水, 手島 保,  
日吉康長, 杉浦昌也, 矢端幸夫\*,  
北角博道\*

左右両房室弁輪部狭窄を伴う滲出・収縮性心膜炎を呈したラッサ熱の1例を報告した。

症例は49歳, 男性。ウィルス抗体価よりラッサ熱と診断された本邦第1例である。合併した心膜液貯留に対し, 心膜腔穿刺, ステロイドにて治療中であつたが, 肝腫大と腹水が増強し, 失神発作が出現したため, 当科に入院した。血圧は92/60 mmHgで奇脈を呈し, 断層心エコー図では右



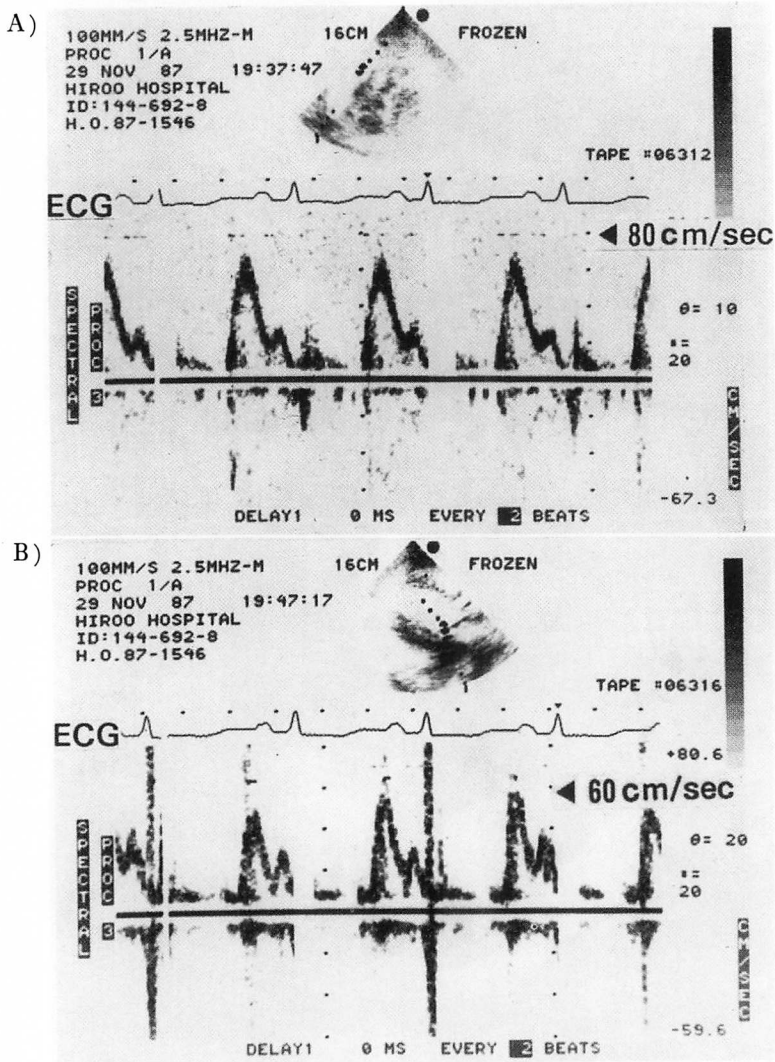
**Fig. 6. Postoperative two-dimensional echocardiograms.**

A: Long-axis view: Mitral annular constriction is no longer present. Echo-free space behind the left ventricle suggests pleural effusion.

B: Four-chamber view: Tricuspid annular constriction is shown to be relieved.

LV=left ventricle, LA=left atrium, Ao=ascending aorta, RV=right ventricle, RA=right atrium.

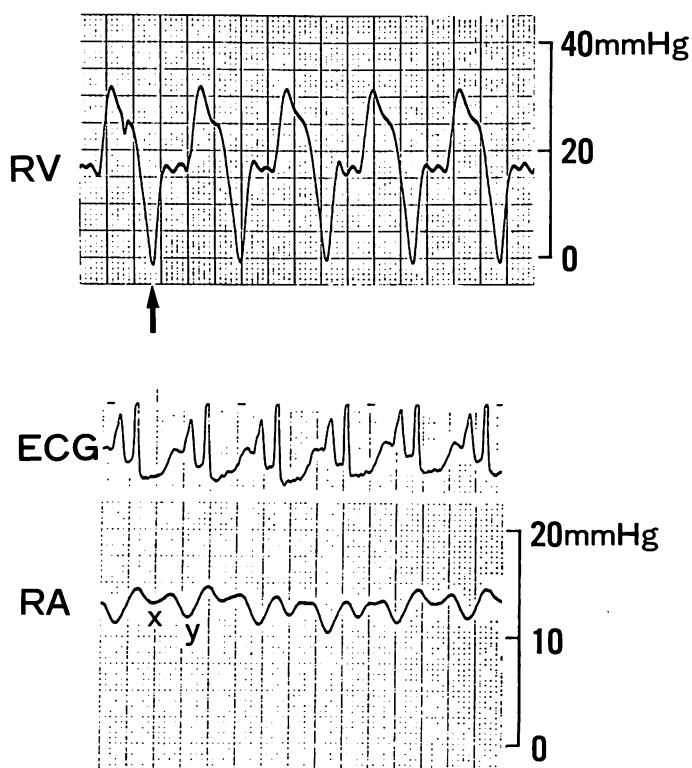




**Fig. 7. Postoperative pulsed Doppler echocardiograms obtained in the ventricular inflow tracts.**

The diastolic filling in the right (A) and left (B) ventricles depends mainly on early diastolic rapid filling.





**Fig. 8. Postoperative right ventricular and right atrial pressure tracings.**

A prominent dip and plateau pattern (arrow) and a predominant y descent are noted.

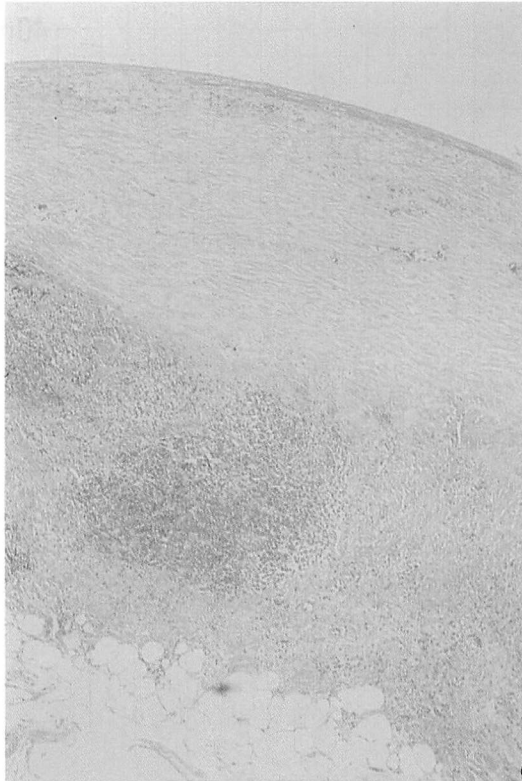RV=right ventricle, RA=right atrium, x=x descent, y=y descent.

室側および左室後壁側に限局性の心膜液貯留を認め、両房室弁輪部の狭窄を認めた。ドップラー法による流入血流速度波形上は、両室ともに、心房収縮期最大流入速度の増大を認めた。右心カテでは右房右室間に平均 8 mmHg の圧較差を認めた。心膜剝離術後、右室圧波形上 dip and plateau が明らかとなり、断層心エコー図では両房室弁輪部の狭窄は消失した。本例はラッサ熱による滲出・収縮性心膜炎の第 1 例と考えられるが、房室弁輪部狭窄を伴った点が注目された。

**Acknowledgement:** We thank Drs. T. Sugano, T. Maemura and S. Konno for providing us valuable surgical information.

#### References

- 1) Frame JD, Baldwin JM Jr, Gocke DJ, Troup JM: Lassa fever, a new virus disease of man from West Africa: I. Clinical description and pathological findings. *Am J Trop Med Hyg* **19**: 670-676, 1970
- 2) McCormick JB, Webb PA, Krebs JW, Johnson KM, Smith ES: A prospective study of the epidemiology and ecology of Lassa fever. *J Infect Dis* **155**: 437-444, 1987
- 3) Tilzey AJ, Webster M, Banatvala JE: Patients with suspected Lassa fever in London during 1984: Problems in their management at St. Thomas's Hospital. *Br Med J* **291**: 1554-1555, 1985
- 4) Leifer E, Gocke DJ, Bourne H: Lassa fever, a new virus disease of man from West Africa: II.



**Fig. 9. Histopathological findings of the excised epicardium.**

Fibrous thickening of the epicardium and lymphocytic infiltration in the subepicardial tissue are noted (Hematoxylin and Eosin, original magnification  $\times 50$ ).

Report of a laboratory-acquired infection treated with plasma from a person recently recovered from the disease. *Am J Trop Med Hyg* **19**: 677-679, 1970

- 5) Walker DH, McCormick JB, Johnson KM, Webb PA, Komba-Kono G, Elliott LH, Gardner JJ: Pathologic and virologic study of fatal Lassa fever in man. *Am J Pathol* **107**: 349-356, 1982

- 6) McCormick JB, King IJ, Webb PA, Johnson KM, O'Sullivan R, Smith ES, Trippel S, Tong TC: A case-control study of the clinical diagnosis and course of Lassa fever. *J Infect Dis* **155**: 445-455, 1987

- 7) Hancock EW: Subacute effusive-constrictive pericarditis. *Circulation* **43**: 183-192, 1971