

Quantification of Left Atrial Appendage Spontaneous Echo Contrast in Patients With Chronic Nonvalvular Atrial Fibrillation

Takahide ITO, MD
Michihiro SUWA, MD, FJCC
Tomomi NAKAMURA, MD
Sadae MIYAZAKI, MD
Ayaka KOBASHI, MD
Yasushi KITAURA, MD

Abstract

Objectives. The left atrial (LA) appendage is the most common site of thrombus formation in patients with atrial fibrillation, and integrated backscatter allows the quantitative assessment of LA spontaneous echo contrast (SEC). Integrated backscatter was used to examine the significance of measuring appendage SEC, specifically in relation to echocardiographic variables implying thromboembolism, in patients with chronic nonvalvular atrial fibrillation.

Methods. Fifty-two patients with chronic nonvalvular atrial fibrillation and no prior anticoagulant therapy (35 men, 17 women, mean age 66 ± 7 years) underwent transesophageal echocardiography with integrated backscatter analysis. The LA and LA appendage integrated backscatter intensity were measured with the regions of interest placed in the LA cavity and the appendage, respectively. The integrated backscatter intensity values for these two chambers (corrected "LA" and "LA appendage" integrated backscatter intensity, respectively) were corrected using values from the left ventricular cavity.

Results. The LA appendage integrated backscatter intensity values were available in 44 patients (85%). Overall, the corrected LA appendage integrated backscatter intensity was significantly increased compared with the corrected LA integrated backscatter intensity (2.8 ± 2.2 vs 2.0 ± 1.8 dB, $p < 0.001$). The corrected LA appendage integrated backscatter intensity was inversely correlated with the LA appendage velocity ($r = -0.37$, $p < 0.05$), but not with the LA dimension, appendage size, or left ventricular function. The corrected appendage integrated backscatter intensity (4.5 ± 2.3 vs 2.4 ± 1.9 dB, $p < 0.01$) and LA integrated backscatter intensity (3.2 ± 2.1 vs 1.7 ± 1.7 dB, $p < 0.05$) were higher in patients who had LA appendage thrombus ($n = 8$) than those who did not. With the corrected appendage integrated backscatter intensity set at ≥ 2.5 dB, the sensitivity for the presence of appendage thrombus was 88% and the specificity was 64%.

Conclusions. Patients with chronic nonvalvular atrial fibrillation had a denser SEC in the LA appendage compared with SEC in the main LA cavity. The severity of the appendage SEC was influenced by the LA appendage function rather than its size. Quantification of SEC in the appendage, rather than main LA cavity, was more valuable for assessing embolic potential.

J Cardiol 2001; 37(6): 325–333

Key Words

Atrial fibrillation

Echocardiography, transesophageal

Thromboembolism

大阪医科大学 第三内科: 〒569-8686 大阪府高槻市大学町2-7

The Third Division, Department of Internal Medicine, Osaka Medical College, Osaka

Address for correspondence: ITO T, MD, The Third Division, Department of Internal Medicine, Osaka Medical College, Daigaku-cho 2-7, Takatsuki, Osaka 569-8686

Manuscript received February 2, 2001; revised March 21, 2001; accepted March 21, 2001

INTRODUCTION

Spontaneous echo contrast (SEC) in the left atrial (LA) cavity appears as a "smoke-like" pattern caused by ultrasonic backscattering from erythrocyte aggregation, and is often detected by transesophageal echocardiography in patients with atrial fibrillation, mitral valve disease, or prior thromboembolism. The presence of SEC is associated with the development of LA thrombus and thromboembolic complications¹⁻⁴. In patients with nonvalvular atrial fibrillation, the LA appendage is the most frequent site of thrombus formation⁵⁻⁷, and depression of its function is significantly associated with the risk of thromboembolic events^{6,8-10}. However, no data are currently available on the clinical relevance of appendage SEC, which is separately assessed from SEC in the main LA cavity.

Recently, new echo technology has developed integrated backscatter, which allows the quantitative assessment of SEC. In patients with atrial fibrillation or sinus rhythm, Klein *et al.*¹¹ and later others^{12,13} demonstrated that the quantitative SEC value in the LA cavity was related to LA size, LA appendage velocity, LA thrombus, and hematological factors such as fibrinogen. This method also allows the quantification of appendage SEC by placing a region of interest in the appendage.

The present study used transesophageal echocardiography with integrated backscatter analysis in patients with chronic nonvalvular atrial fibrillation to examine the clinical significance of measuring appendage SEC, as related to echocardiographic variables that suggest the presence of thromboembolism.

METHODS

Patients

Fifty-two patients (35 men and 17 women, mean age 66 ± 7 years) with chronic nonvalvular atrial fibrillation who underwent transesophageal echocardiography were enrolled in this study. Since all patients were referred for the evaluation of potential risks of thromboembolism, no patients had received any anticoagulant therapy. The diagnosis of chronic nonvalvular atrial fibrillation was based on the electrocardiographic and echocardiographic findings. Chronic atrial fibrillation was documented at two separate occasions by electrocardiography and there was no evidence of rheumatic changes in the mitral valve apparatus. The predom-

inant causes of atrial fibrillation were hypertensive heart disease ($n = 13$), dilated cardiomyopathy ($n = 7$), alcohol abuse ($n = 2$), hypertrophic cardiomyopathy ($n = 1$), left atrial septal defect ($n = 1$), calcified aortic stenosis ($n = 1$), and constrictive pericarditis ($n = 1$). The remaining 26 patients had lone atrial fibrillation (no identifiable cardiac origin of atrial fibrillation). Four patients had a history of stroke.

Echocardiography

All patients gave informed consent to participate in the study before the induction of transesophageal echocardiography. Transthoracic echocardiography was performed immediately before transesophageal echocardiography. The left atrial dimension, left ventricular end-diastolic dimension, and left ventricular fractional shortening were determined using the standard M-mode criteria¹⁴. The severity of mitral regurgitation was semiquantitatively assessed using color-Doppler imaging¹⁵.

Transesophageal echocardiography was performed using a 5-MHz omniplane transducer attached to a commercially available echocardiographic system (SONOS 2500, Hewlett Packard, Inc.). Particular attention was paid to image the main LA cavity and LA appendage to assess the presence or absence of SEC and thrombus. SEC was identified as dynamic smoke-like echoes within the LA cavity, with a characteristic swirling motion distinct from white noise artifact, and was qualitatively graded as "none", "mild", and "severe", as described previously^{1,16}. The distribution of SEC over the LA cavity including the appendage was also visually assessed. In many cases, there was dense SEC in the appendage and/or around its outlet compared with the other parts of the LA chamber. LA thrombus was defined as an echo-dense mass attached to the LA wall, and particular care was taken to differentiate thrombus from normal structures such as pectinate muscles.

LA appendage size and function were assessed using two-dimensional and Doppler echocardiography. In the longitudinal plane, the maximal LA appendage area was measured by planimetry. In the same plane, LA appendage emptying velocity was recorded with the pulsed-Doppler interrogation of the LA appendage orifice, and the highest LA appendage emptying velocity per cardiac cycle, usually at end-diastole, was averaged over 5 consecutive beats. Since filling velocities were approx-

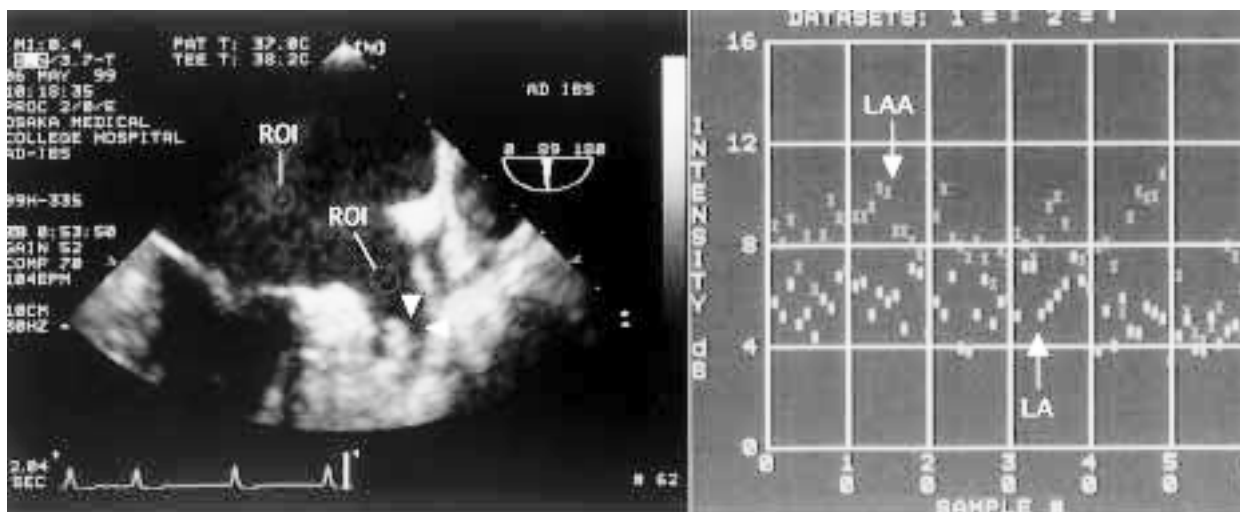


Fig. 1 Integrated backscattering images

Left: Transesophageal echocardiography integrated backscattering image. The region of interest (circle)s placed in the main LA cavity, LA appendage, and left ventricular cavity. Arrowheads indicate thrombus.

Right: Integrated backscattering curves for the LA cavity and LA appendage in a patient with spontaneous echo contrast.

ROI = region of interest; LAA = left atrial appendage; LA = left atrium (atrial)

imately equal in magnitude to the emptying velocities, they were not separately measured.

Analysis of integrated backscatter data

The SONOS 2500 echocardiography scanner includes an acoustic densitometry software program for integrated backscatter analysis. Transesophageal echocardiographic images were obtained showing the upper one- to two-thirds of the left ventricular cavity, the main LA cavity, and almost the whole LA appendage in one integrated backscatter image (Fig. 1). For the quantitative assessment of SEC, the analysis system was configured to analyze 62 frames of integrated backscatter image data during a 2-sec period from cineloop memory, which had been digitally saved to an optical disk for subsequent analysis.

The time-gain-compensation and receive gain were adjusted such that optimal visualization of the integrated backscatter image was established¹²; during the acquisition of integrated backscatter data, the smoothing filter for reducing noise in the time-intensity samples was preset to "off", and the lateral gain control was not used. The region of interest, a circle of 21 pixels, was placed in the main LA cavity, LA appendage, and left ventricular cavity (Fig. 1). When tracking SEC over the LA cavity, the region of interest was placed on the most

intense SEC^{11,12}). The integrated backscatter parameters obtained were values for the average image intensity (mean integrated backscatter intensity) and the peak-to-peak variability of the integrated backscatter signal in each region of interest, the former of which was used for analysis. Quantitative SEC values for the main LA cavity (corrected LA integrated backscatter intensity) and the LA appendage (corrected LA appendage integrated backscatter intensity) were corrected by the left ventricular integrated backscatter intensity values^{11,12}). The display graph was preset to span the integrated backscatter intensity values in the range from 0 to 64 dB. Three sets of the cineloop were obtained and a median value adopted for each region of interest.

Reproducibility

Interobserver and intraobserver variabilities of integrated backscatter data were assessed in 10 patients by two independent observers (S. M. and T. N.) without knowledge of the presence or absence of LA thrombi or the patient's background.

Statistical analysis

Differences in echocardiographic parameters between patients with and without LA thrombus were analyzed using the unpaired *t*-test. The quanti-

Table 1 Echocardiographic data of the study patients

Variables		Range
M-mode, two-dimensional, and Doppler data (n = 52)		
LA dimension (cm)	4.9 ± 0.6	4.8 - 0.6
LV diastolic dimension (cm)	5.2 ± 0.8	3.9 - 7.7
LV fractional shortening (%)	29 ± 9	10 - 43
Moderate to severe MR	2 (4%)	
LAA velocity (cm/sec) (n = 51)	32 ± 15	11 - 72
LAA size (cm ²)	4.5 ± 1.5	2.4 - 8.4
Qualitative SEC grade		
No SEC	26 (50%)	
Mild SEC	21 (40%)	
Severe SEC	5 (10%)	
LA thrombus (%)	9 (17%)	
IB data (n = 44)		
LV IB intensity (dB)	1.3 ± 0.1	1.2 - 1.7
LA IB intensity (dB)	3.3 ± 1.8	1.2 - 8.8
LAA IB intensity (dB)	4.0 ± 2.2	1.2 - 9.4

Continuous values are mean ± SD.

LV = left ventricular; MR = mitral regurgitation; SEC = spontaneous echo contrast; IB = integrated backscatter. Other abbreviation as in Fig. 1.

tative SEC values in the LA appendage vs main LA cavity within the same group were compared by paired *t*-test. Simple linear regression analysis was performed to evaluate the correlations between the quantitative SEC values and some echocardiographic parameters. Using a receiver operating characteristics curve¹⁷⁾, the best cutoff values were defined for the detection of LA thrombus. All data are expressed as mean ± SD, and a *p* value < 0.05 was considered significant.

RESULTS

Echocardiographic data of the patients are listed in **Table 1**. Of the 52 patients, 26 (50%) had SEC and 9 (17%) had LA thrombus; no thrombus was observed in the main LA cavity. In 26 patients with SEC, 6 had SEC exclusively within the appendage cavity and around its outlet, and their qualitative SEC grade was all "mild". Six of the patients (23%) with SEC had LA thrombus. The underlying disorders in the nine patients with LA thrombus were hypertensive heart disease (n = 3), dilated cardiomyopathy (n = 1), alcohol abuse (n = 1), hypertrophic cardiomyopathy (n = 1), atrial septal defect (n = 1), calcified aortic stenosis (n = 1), and

constrictive pericarditis (n = 1). Two patients had significant mitral regurgitation, and neither had SEC or thrombus.

The quantitative SEC value in the LA appendage was not available in eight patients for the following reasons: Almost complete obliteration of the appendage cavity due to vigorous appendage contraction (n = 4); increased reverberation artifact (e.g., reflection of the wall between the left upper lobe pulmonary vein and the LA appendage) (n = 3); and large LA appendage thrombus occupying its cavity (n = 1). Since all of these conditions precluded a region of interest kept constantly within the appendage cavity, the following analyses were performed on the remaining 44 patients (29 men and 15 women, mean age 66 ± 7 years).

Distribution of spontaneous echo contrast over the left atrial cavity

Overall, the corrected LA appendage integrated backscatter intensity was significantly increased compared with the corrected LA integrated backscatter intensity (2.8 ± 2.2 vs 2.0 ± 1.8 dB, *p* < 0.001; **Fig. 2**), indicating that there was dense SEC in the LA appendage as compared with the main LA cavity.

Relationship between quantitative spontaneous echo contrast values and other echocardiographic variables

Table 2 shows a coefficient matrix of the correlation between corrected LA/LA appendage integrated backscatter intensity values and echo-Doppler parameters. There was a weak but significant correlation between the corrected appendage integrated backscatter intensity and appendage velocity; but no relationship was observed between the corrected appendage integrated backscatter intensity and LA dimension, appendage size, or left ventricular fractional shortening. Similar findings were observed for the corrected LA integrated backscatter intensity. The corrected LA appendage integrated backscatter intensity (4.5 ± 2.3 vs 2.4 ± 1.9 dB, *p* < 0.01) was higher in patients who had LA appendage thrombus than those who did not, as was the corrected LA integrated backscatter intensity (3.2 ± 2.1 vs 1.7 ± 1.7 dB, *p* < 0.05; **Fig. 3**).

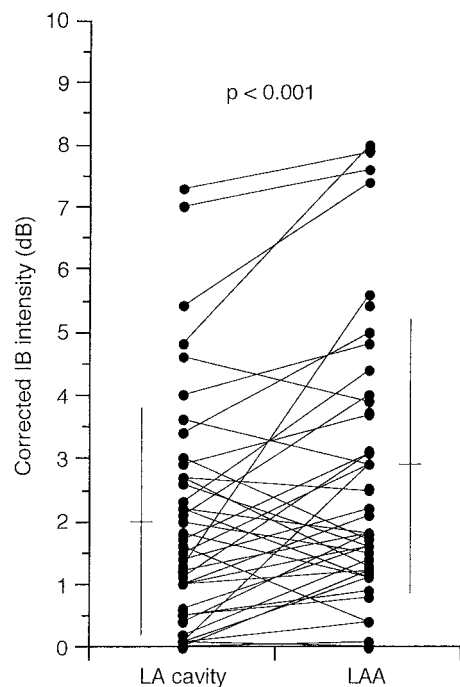


Fig. 2 Comparison of the corrected left atrial vs left atrial appendage integrated backscatter intensity values

Values are mean \pm SD.
Abbreviations as in Fig. 1, Table 1.

Left atrial versus left atrial appendage spontaneous echo contrast for identifying left atrial appendage thrombus

According to the receiver operator characteristic curves for both corrected LA and LA appendage integrated backscatter intensity values (Fig. 4), the latter had a larger area under the curve. The best cutoff point of the corrected appendage integrated backscatter intensity for the presence of appendage thrombus appeared to be between 2 and 3 dB. With the cutoff point set at ≥ 2.5 dB, for example, the sensitivity of LA appendage integrated backscatter intensity for the presence of appendage thrombus was 88% and the specificity was 64%.

Reproducibility

The mean differences of the interobserver variability for LA integrated backscatter intensity and LA appendage integrated backscatter intensity were 0.1 ± 0.1 dB (range 0.0 - 0.1) and 0.4 ± 0.4 dB (range 0.0 - 1.1), respectively. Likewise, those of the intraobserver variability were 0.0 ± 0.0 dB (range 0.0 - 0.1) and 0.5 ± 0.6 dB (range 0.0 - 1.6), respectively.

Table 2 Coefficient matrix for the correlations between quantitative spontaneous echo contrast values and other echocardiographic parameters

	Corrected LA IB intensity	Corrected LAA IB intensity
LA dimension	0.07	0.00
LV fractional shortening	0.11	0.18
LAA velocity	- 0.34*	- 0.37*
LAA size	0.08	0.09

* $p < 0.05$.
Abbreviations as in Fig. 1, Table 1.

DISCUSSION

Quantification of spontaneous echo contrast in the left atrial appendage

The present study demonstrated that the quantification of SEC in the LA appendage could identify patients at high risk for cardiogenic embolism. Although in some patients such quantification was impossible, those with good appendage function are unlikely to develop LA appendage thrombus. In this study, the corrected LA as well as LA appendage integrated backscatter intensity was related to the presence of LA thrombus, so the measurement of SEC in the main LA cavity does not necessarily lose its effectiveness for identifying high-risk patients. The main purpose of the present study was to examine the feasibility and clinical significance of measuring SEC in the appendage.

Blood stasis in the left atrial appendage

Although there have been numerous studies that describe LA SEC, little information is available on the distribution of SEC over the LA cavity. The only observation is that SEC develops in the LA appendage after successful cardioversion of atrial fibrillation in the situation called "atrial stunning"^{18,19}. This study observed that the most common pattern of distribution of SEC is chiefly over the appendage cavity to its outlet; our integrated backscatter data showed an increased LA appendage integrated backscatter intensity compared with LA integrated backscatter intensity. This finding also indicates that stagnation of blood is more likely to occur in the appendage than in the other atrial parts, further supporting the idea that the LA appendage is the most common site of

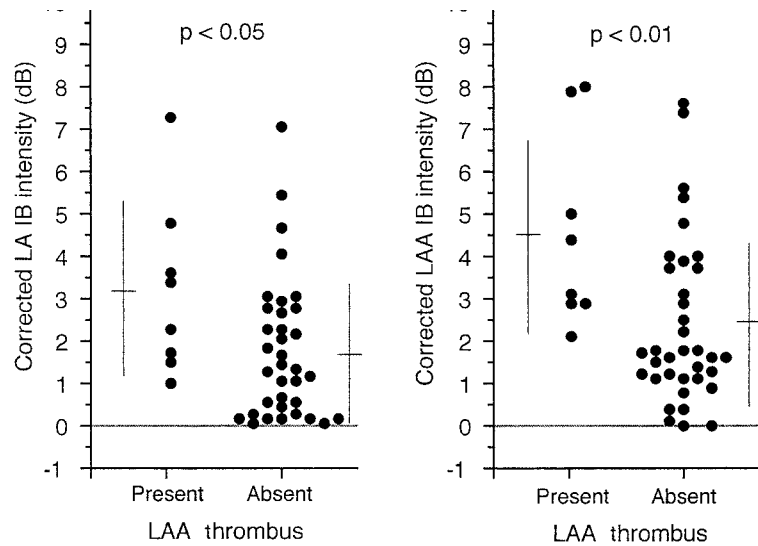


Fig. 3 Scatter plots of the comparison of the corrected left atrial and left atrial appendage integrated backscatter intensity values between patients with and without left atrial appendage thrombus. Values are mean \pm SD. Abbreviations as in Fig. 1, Table 1.

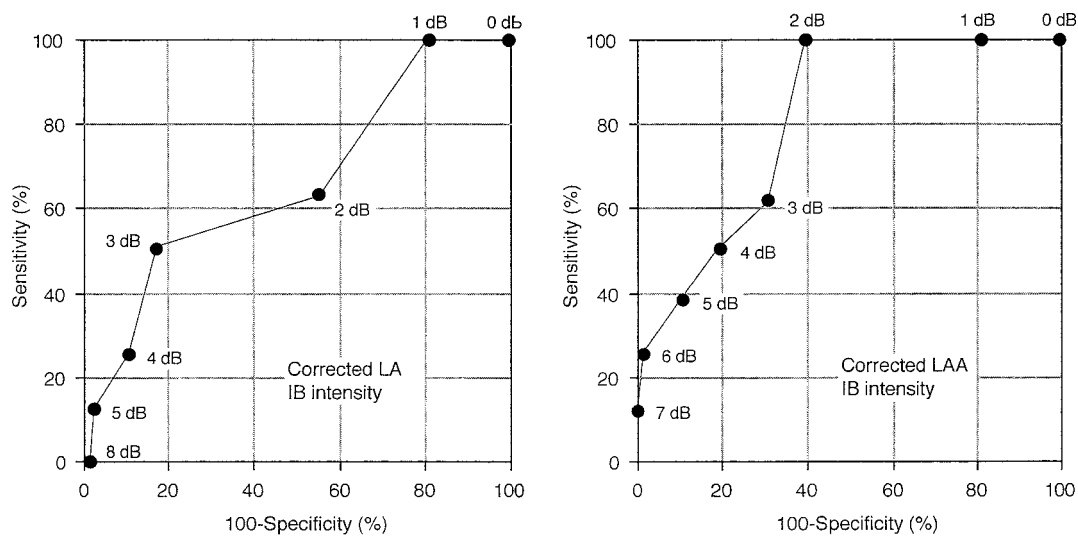


Fig. 4 Receiver operator characteristic curves for determining optimal sensitive and specific points of the corrected left atrial (left) and left atrial appendage (right) integrated backscatter intensity values related to the presence of left atrial appendage thrombus. Abbreviations as in Fig. 1, Table 1.

thrombus formation⁵⁻⁷).

Localized LA blood stasis has been indirectly shown in previous studies that used transesophageal echocardiography. Kato *et al.*²⁰), for example, observed that the LA appendage was not opacified by intravenous contrast agent in atrial fibrillation patients with LA enlargement and poor appendage function. Furthermore, Shively *et al.*²¹) demonstrated that in patients with atrial fibrillation or atrial flutter, blood velocity, assessed by pulsed-Doppler, was the lowest in the LA appendage and

the vicinity of the LA posterior wall, which was associated with the risk of stroke.

Relationship between left atrial appendage spontaneous echo contrast and cardiac function

In our study, the corrected LA appendage integrated backscatter intensity was correlated with the appendage velocity, but not with the LA or LA appendage size. This finding suggests that the functional status of the appendage is more important than its size in producing SEC. Reduced appendage

velocity is a marker of blood stasis^{6,8-10}). Currently, the corrected LA appendage integrated backscatter intensity had no relationship with the LA size, which was not in concordance with the previous studies^{11,12}). The absence of this relationship might be attributed to the relatively small number of patients or the differences in their characteristics. Although left ventricular dysfunction is considered to be one of the predictors of thromboembolism²²), none of the previous studies found any correlation between left ventricular function and SEC^{1,2,4}), as did the present study.

Clinical implications

One of the clinical goals is to find which group of patients with nonvalvular atrial fibrillation is at high risk for future thromboembolism. It is well known that SEC in the LA cavity is an important predictor of such complication in patients with atrial fibrillation¹⁻⁴). In our study, the corrected LA appendage integrated backscatter intensity, as compared with the corrected LA integrated backscatter intensity, was a more sensitive and specific parameter for determining LA appendage thrombus. Given that appendage thrombus is the strong predictor of thromboembolism²³), the measurement of appendage SEC could be a better method for identi-

fying high-risk patients and also an indication of specific antithrombotic therapy. Whether this index has any prognostic value, however, requires a large-scale prospective study.

Limitations

In the present study, only 2-sec integrated backscatter data were obtained for each region of interest, which is an inherent limitation in the currently available image acquisition system, although we acquired 3 sets of cine-loops from each patient. Because of the small number of patients, the influence of quantifying appendage SEC on previous stroke was not assessed using multivariate analysis that includes other potential predictors of this risk.

CONCLUSIONS

We attempted to quantify LA appendage SEC in patients with chronic nonvalvular atrial fibrillation, and found that SEC in the LA appendage is denser compared with SEC in the main LA cavity. The severity of appendage SEC was influenced by appendage function rather than appendage size. Quantification of SEC in the appendage, rather than main LA cavity, was more valuable for assessing embolic potential.

要 約

非弁膜症性心房細動患者における左心耳内モヤモヤエコーの定量的評価:

Integrated Backscatter を用いた検討

伊藤 隆英 諏訪 道博 中村 知美

宮崎 貞恵 小橋 文香 北 浦 泰

目 的: 非弁膜症性心房細動患者においては、左心耳は血栓の好発部位であり、血栓の存在が血栓塞栓症の発症につながることは周知の事実である。今回、integrated backscatter (IB) を用いて左心耳内モヤモヤエコーを定量化し、血栓塞栓症発症に関与するとされる心エコー図法の諸指標との関連について調べた。

方 法: 過去に抗凝固療法を受けていない非弁膜症性心房細動患者52例(男性35例、女性17例、平均年齢 66 ± 7 歳)を対象とした。経食道心エコー図法(使用装置: Hewlett Packard 製 SONOS 2500)を用い、IB画面上、関心領域を左房内、左心耳内、および左室内に設置し、各部位における平均IB値を測定した。左房および左心耳内モヤモヤエコーの定量値は左室のIB値との差とした。

結 果: 左心耳IB値が測定可能であった患者は44例(85%)であった。総じて、左心耳内モヤモヤエコー定量値は左房内のそれに比べて高値を示した(それぞれ 2.8 ± 2.2 vs 2.0 ± 1.8 dB, $p < 0.001$)。左心耳内モヤモヤエコーの定量値は、左心耳内血流速度と有意な負相関が認められたが($r = -0.37$, $p < 0.05$)、左房径、左心耳サイズ、および左室収縮能とは関連性を示さなかった。左心耳内(4.5 ± 2.3 vs 2.4 ± 1.9 dB, $p < 0.01$)と左房内(3.2 ± 2.1 vs 1.7 ± 1.7 dB, $p < 0.05$)モヤモヤエ

コーの定量値は、ともに左心耳内血栓が認められなかった患者に比べて、これが認められた患者(8例)において高値であった。また、左心耳内モヤモヤエコーの定量値2.5 dBをカットオフ値とすると、左心耳内血栓に対する感度は88%、特異度は64%であった。

結論: 非弁膜症性心房細動患者においては、左心耳内に血流がうっ滞する傾向があり、このうっ滞の程度は左房サイズよりむしろ左心耳機能に依存していた。左房内モヤモヤエコーの定量値に比べて、左心耳内モヤモヤエコーの定量値は血栓塞栓症発症の予知に有用な指標となりうる。

J Cardiol 2001; 37(6): 325 - 333

References

- 1) Black IW, Hopkins AP, Lee LC, Walsh WF: Left atrial spontaneous echo contrast: A clinical and echocardiographic analysis. *J Am Coll Cardiol* 1991; **18**: 398 - 404
- 2) Chimowitz MI, DeGeorgia MA, Poole RM, Hepner A, Armstrong WM: Left atrial spontaneous echo contrast is highly associated with previous stroke in patients with atrial fibrillation or mitral stenosis. *Stroke* 1993; **24**: 1015 - 1019
- 3) Leung DY, Black IW, Cranney GB, Hopkins AP, Walsh WF: Prognostic implications of left atrial spontaneous echo contrast in nonvalvular atrial fibrillation. *J Am Coll Cardiol* 1994; **24**: 755 - 762
- 4) Tsai LM, Chen JH, Fang CJ, Lin LJ, Kwan CM: Clinical implications of left atrial spontaneous echo contrast in non-rheumatic atrial fibrillation. *Am J Cardiol* 1992; **70**: 327 - 331
- 5) Collins LJ, Silverman DI, Douglas PS, Manning WJ: Cardioversion of nonrheumatic atrial fibrillation: Reduced thromboembolic complications with 4 weeks of precardioversion anticoagulation are related to atrial thrombus resolution. *Circulation* 1995; **92**: 160 - 163
- 6) Fatkin D, Kelly RP, Feneley MP: Relations between left atrial appendage blood flow velocity, spontaneous echocardiographic contrast and thromboembolic risk in vivo. *J Am Coll Cardiol* 1994; **23**: 961 - 969
- 7) Jaber WA, Prior DL, Thamilarasan M, Grimm RA, Thomas JD, Klein AL, Asher CR: Efficacy of anticoagulation in resolving left atrial and left atrial appendage thrombi: A transesophageal echocardiographic study. *Am Heart J* 2000; **140**: 150 - 156
- 8) Mügge A, Kuhn H, Nikutta P, Grote J, Lopes JA, Daniel WG: Assessment of left atrial appendage function by biplane transesophageal echocardiography in patients with nonrheumatic atrial fibrillation: Identification of a subgroup of patients at increased embolic risk. *J Am Coll Cardiol* 1994; **23**: 599 - 607
- 9) Garcia-Fernandez MA, Torrecilla EG, San-Roman D, Azevedo J, Bueno M, Moreno MM, Delcan JL: Left atrial appendage Doppler flow patterns: Implications on thrombus formation. *Am Heart J* 1992; **124**: 955 - 961
- 10) Pollick C, Taylor D: Assessment of left atrial appendage function by transesophageal echocardiography: Implications for the development of thrombus. *Circulation* 1991; **84**: 223 - 231
- 11) Klein AL, Murray RD, Black IW, Chandra S, Grimm RA, D Sa DP, Leung DY, Miller D, Morehead AJ, Vaughn SE, Thomas JD: Integrated backscatter for quantification of left atrial spontaneous echo contrast. *J Am Coll Cardiol* 1996; **28**: 222 - 231
- 12) Ito T, Suwa M, Kobashi A, Yagi H, Nakamura T, Miyazaki S, Kitaura Y: Integrated backscatter assessment of left atrial spontaneous echo contrast in chronic nonvalvular atrial fibrillation: Relation with clinical and echocardiographic parameters. *J Am Soc Echocardiogr* 2000; **13**: 666 - 673
- 13) Sakamoto S, Mizushige K, Takagi K, Ueda T, Ohmori K, Matsuo H: Effect of batroxobin on spontaneous echo contrast and hemorheology in left atrial appendage in atrial fibrillation assessed by transesophageal echocardiography. *Am J Cardiol* 1999; **84**: 816 - 819
- 14) Sahn DJ, DeMaria A, Kisslo J, Weyman A: Recommendations regarding quantitation in M-mode echocardiography: Results of a survey of echocardiographic measurements. *Circulation* 1978; **58**: 1072 - 1083
- 15) Miyatake K, Izumi S, Okamoto M, Kinoshita N, Asonuma H, Nakagawa H, Yamamoto K, Takamiya M, Sakakibara H, Mimura Y: Semiquantitative grading of severity of mitral regurgitation by real-time two-dimensional Doppler flow imaging technique. *J Am Coll Cardiol* 1986; **7**: 82 - 88
- 16) Beppu S, Nimura Y, Sakakibara H, Nagata S, Park YD, Izumi S: Smoke-like echo in the left atrial cavity in mitral valve disease: Its features and significance. *J Am Coll Cardiol* 1985; **6**: 744 - 749
- 17) Endreich LS, Lee ET: Use of relative operating characteristics analysis in epidemiology: A method for dealing with subjective judgement. *Am J Epidemiol* 1981; **114**: 649 - 662
- 18) Fatkin D, Kuchar DL, Thorburn CW, Feneley MP: Transesophageal echocardiography before and during direct current cardioversion of atrial fibrillation: Evidence for "atrial stunning" as a mechanism of thromboembolic complications. *J Am Coll Cardiol* 1994; **23**: 307 - 316
- 19) Grimm RA, Stewart WJ, Maloney JD, Cohen GI, Pearce GL, Salcedo EE, Klein AL: Impact of electrical cardioversion for atrial fibrillation on left atrial appendage function and spontaneous echo contrast: Characterization by simultaneous transesophageal echocardiography. *J Am Coll Cardiol* 1993; **22**: 1359 - 1366
- 20) Kato H, Nakanishi M, Maekawa N, Ohnishi T, Yamamoto M: Evaluation of left atrial appendage stasis in patients with atrial fibrillation using transesophageal echocardiography with an intravenous albumin-contrast agent. *Am J Cardiol* 1996; **78**: 365 - 369
- 21) Shively BK, Gelgand EA, Crawford MH: Regional left atrial stasis during atrial fibrillation and flutter: Determinants and relation to stroke. *J Am Coll Cardiol*

- 1996; **27**: 1722 - 1729
- 22) The Stroke Prevention in Atrial Fibrillation Investigators:
Predictors of thromboembolism in atrial fibrillation: .
Echocardiographic features of patients at risk. *Ann Intern
Med* 1992; **116**: 6 - 12
- 23) Zabaloitia M, Halperin JL, Pearce LA, Blackshear JL,

Asinger RW, Hart RG, for the Stroke Prevention in Atrial
Fibrillation Investigators: Transesophageal echocardiographic
correlates of clinical risk of thromboembolism in
nonvalvular atrial fibrillation. *J Am Coll Cardiol* 1998; **31**:
1622 - 1626