

Cardiovascular Imaging In-a-Month

A 68-Year-Old Female With Repetitive Palpitation

Tomohiro HARADA, MD

Eiji OHTAKI, MD, FJCC

Tetsuya SUMIYOSHI, MD, FJCC

Saichi HOSODA, MD, FJCC

CASE

A 68-year-old female had a history of thyroid goiter resection 35 years ago, and developed mild diabetes mellitus 3 years ago. She had complained of palpitations several times, which always disappeared within 1 hr. Her physician had treated her under a diagnosis of paroxysmal supraventricular tachycardia with sporadic administration of anti-arrhythmic agents for more than 10 years. More recently, she presented with frequent palpitations over a week. She consulted another physician. Electrocardiography (ECG) documented T wave inversions (Fig. 1). On admission, she was normotensive (blood pressure of 140/80 mmHg) and had a heart rate of 70 beats/min.

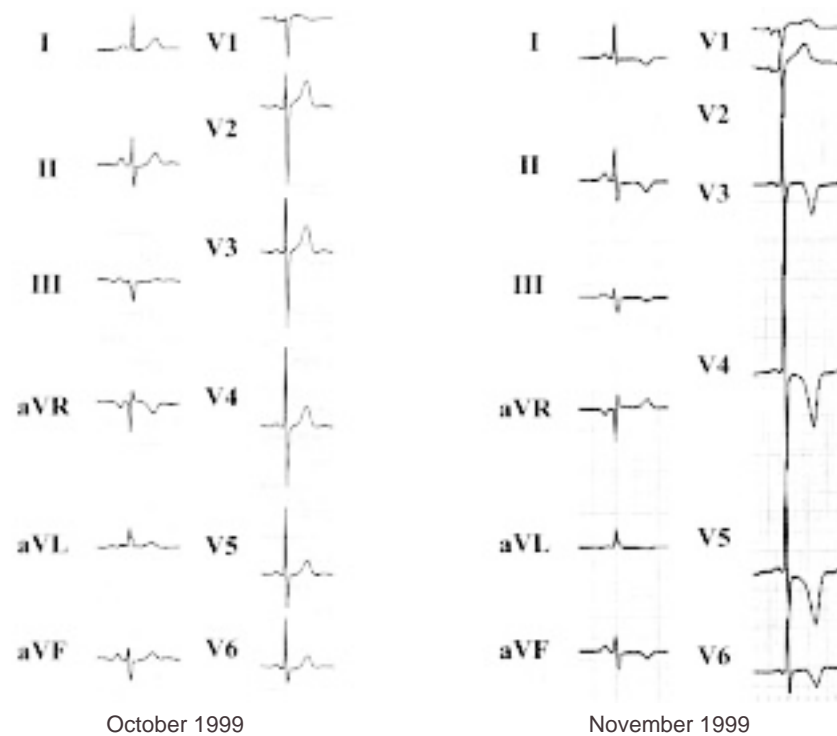


Fig. 1

日本心臓血圧研究振興会附属榊原記念病院 循環器内科(原田智浩, 大滝英二, 住吉徹哉, 細田瑛一): 〒151-0053 東京都渋谷区代々木2-5-4

Department of Cardiology, Sakakibara Heart Institute, Tokyo

Address for correspondence: OHTAKI E, MD, FJCC, Department of Cardiology, Sakakibara Heart Institute, Yoyogi 2-5-4, Shibuya-ku, Tokyo 151-0053

Manuscript received September 28, 2001; revised October 22, 2001; accepted October 27, 2001

Points for Diagnosis

During echocardiography, her heart rate gradually accelerated up to 170 beats/min, and then decreased to a normocardiac state within a few minutes. The daily ECG profile also revealed paroxysmal tachycardia with about 7 - 10 episodes per day even in the resting state (Fig. 2 - A). The profile of blood pressure monitoring showed transient asymptomatic elevation. Plasma and 24-hour urinary excretion catecholamine values are shown in Table 1. Computed tomography revealed a nodular mass in the right adrenal gland, which was enhanced and had a diameter of 31 × 30mm (Fig. 2 - B). The clonidine test, which mainly acts as a central α -adrenergic agonist and suppresses the release of catecholamine, had no effect even though

the systolic blood pressure decreased (Fig. 3).

Echocardiography showed hyper-dynamic wall motion (fractional shortening : 49%), but no ischemic asynergy. Doppler-derived transmitral flow revealed pseudonormalization (ratio of E to A : 1.3, deceleration time : 160msec; Fig. 2 - C) and pulmonary venous pattern showed atrial reversal flow of 130msec (Fig. 2 - D). Plasma B-type natriuretic peptide (BNP) level was elevated (276 pg/ml). ¹²³I-metaiodobenzylguanidine (MIBG) cardiac scintigraphy showed a defect in the infero-posterior region, and the washout rate remained high (32%), although thallium scintigraphy showed no evidence of myocardial ischemia. The diagnosis was adrenal pheochromocytoma.

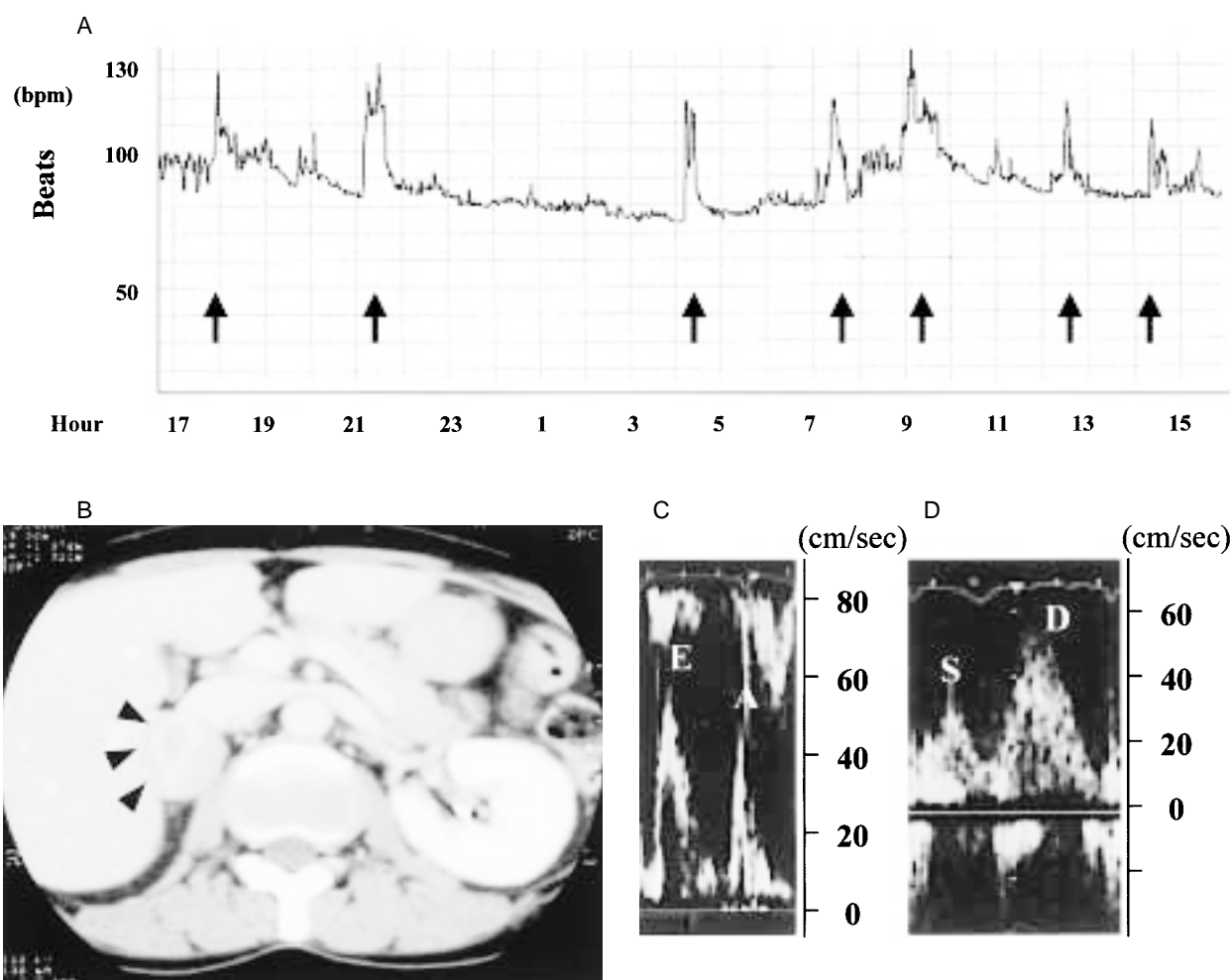


Fig. 2

Pheochromocytoma accounts for about 0.04 % of cases of hypertension¹). The symptomatic triad of headache, palpitation and perspiration has a specificity of 93.8% and a sensitivity of 90.9% in hypertensive patients²). Patients have a potentially curable cause of endocrine hypertension or hypertensive crisis, but if undetected, pheochromocytomas carry a high risk for morbidity and mortality, especially during surgical procedures and pregnancy³). About 10% of pheochromocytomas are malignant either at first operation or during follow-up³). The 10-year survival rate for malignant pheochromocytoma is 40%⁴). Therefore, the correct diagnosis

should be reached as soon as possible. Surgery should be considered under a diagnosis of pheochromocytoma.

A lot of cases actually tend to be overlooked, even if manifesting with typical symptoms. Secretion of dopamine or adrenaline could be higher than that of noradrenaline in patients without typical symptoms. Such an endocrinic profile, which depends on the pathological properties, location of the tumor or enzyme within the tumor, can affect the diagnostic timing. The present patient without the typical symptomatic triad was treated for paroxysmal arrhythmia for more than 10 years. However, the dopamine (or adrenaline) level was much higher than the noradrenaline level.

The condition was detected by the ECG changes that appeared as negative T waves. Typically, electrocardiography displays the normal or high voltages characteristic of left ventricular hypertrophy, or ST elevations in patients with pheochromocytoma⁵). However, our patient showed T wave inversions, although thallium scintigraphy showed no findings suggestive of myocardial ischemia.

The problem was that her condition might already have developed to latent heart failure. The elevated plasma BNP, pseudonormalization of the Doppler-derived transmitral flow and enhanced washout rate on the MIBG cardiac scintigram may suggest the presence of latent heart failure. Necropsy of patients with pheochromocytomas

Table 1 Serum levels of catecholamines and metabolites

		Cut-off value
Plasma		
Adrenaline(pg/ml)	330	< 170
Noradrenaline(pg/ml)	260	< 570
24-hour urinary excretion		
Adrenaline(µg/day)	195	< 23
Noradrenaline(µg/day)	248	< 120
Dopamine(µg/day)	4,800	< 1,000
Metanephline(µg/day)	2,900	< 200
Ratio of metanephline to creatinine	4.8	< 2.2
Normetanephline(µg/day)	690	< 280
Vanilmandelic acid(mg/day)	6.1	< 7.5

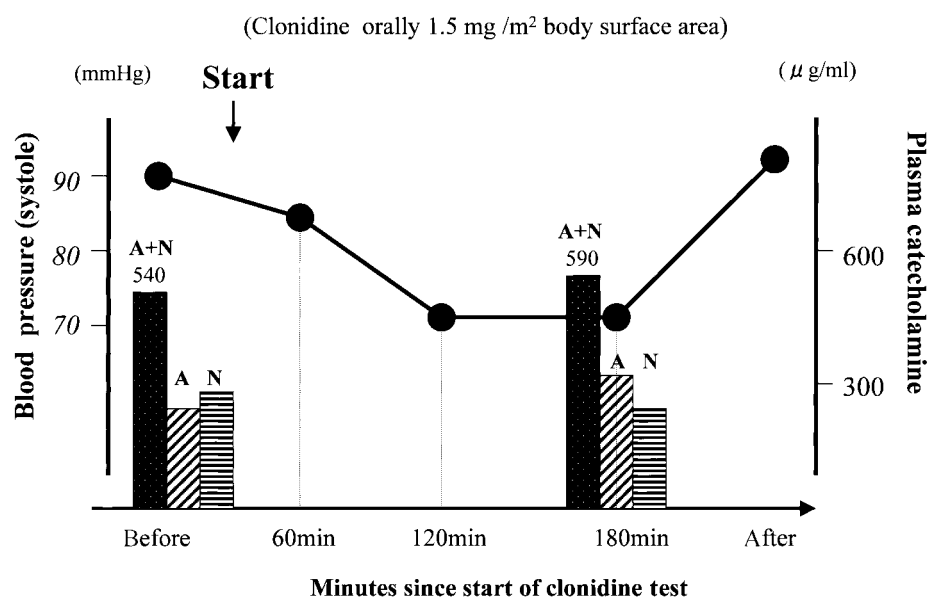


Fig. 3

who died of acute pulmonary edema showed evidence of myocardial damage¹⁾. Focal myofibril degeneration with loss of striation or extensive focal myocardial cell necrosis is generally reported¹⁾. Even in the earlier phases, diffuse edema or minor alterations in myocardial nuclei were noted¹⁾. These states can be described as "norepinephrine myocardium"⁴⁾ or "catecholamine-induced cardiomyopathy"⁴⁾.

This study suggests several important conclusions. First, normotensive patients with pheochromocytoma can deteriorate severely or die of advanced adrenergic myocardial damage, because the diagnosis is often delayed. Second, heart failure can easily occur if the left ventricular contractility is reduced. Therefore, pheochromocytoma should always be included in the differential diagnosis of cardiac diseases.

Diagnosis: Adrenal pheochromocytoma

References

- 1) Sardesai SH, Mourant AJ, Sivathandon Y, Farrow R, Gibbons DO: Pheochromocytoma and catecholamine induced cardiomyopathy presenting as heart failure. *Br Heart J* 1990; **63**: 234 - 237
- 2) Bravo EL, Gifford RW Jr: Current concepts: Pheo-

chromocytoma: Diagnosis, localization and management. *N Engl J Med* 1984; **311**: 1298 - 1303

- 3) Plouin PF, Gimenez-Roqueplo AP, La Batide Alanore A, Salenave S, Duclos JM: Recent progress in the diagnosis, prognostic evaluation and treatment of pheochromocytomas. *Rev Med Interne* 2000; **21**: 1075 - 1085 (in French with Eng abstr)
- 4) Kopf D, Goretzki PE, Lehnert H: Clinical management of malignant adrenal tumors. *J Cancer Res Clin Oncol* 2001; **127**: 143 - 155
- 5) Haas GJ, Tzagournis M, Boudoulas H: Pheochromocytoma: Catecholamine-mediated electrocardiographic changes mimicking ischemia. *Am Heart J* 1988; **116**: 1363 - 1365

Fig. 1 Electrocardiograms

The development of deep T wave inversion in the precordial leads is seen (right)

Fig. 2 Daily profile of heart rate monitoring (A) showing paroxysmal tachycardia (arrows: symptoms of palpitation), computed tomography scan (B) showing a large mass in the right side of the adrenal gland (arrowheads), and Doppler-derived transmittal flow (C) and pulmonary venous pattern (D)

Pseudonormalization (ratio of E to A: 1.3, deceleration time: 160 msec) and atrial reversal flow (130 msec) are noted.

Fig. 3 Changes induced by clonidine suppression test

Systolic blood pressure (solid circle) and plasma catecholamine levels (bars)

A = adrenaline; N = noradrenaline.