

Primary Cardiac Sarcoma Mimicking Benign Myxoma: A Case Report

Tasuku HASEGAWA, MD
Susumu NAKAGAWA, MD, FJCC
Masao CHINO, MD, FJCC*
Takamu KUNIHIRO, MD
Susumu UI, MD, FJCC
Mitsuru KIMURA, MD, FJCC

Abstract

A 53-year-old woman presented with a primary cardiac sarcoma mimicking benign myxoma manifesting as progressive heart failure. Transesophageal echocardiography disclosed two separate tumors in the left atrium which appeared just like myxoma, except for the origin and multiple growth profile. Three separate tumors were identified during the operation arising from the posterior wall of the left atrium, mitral valve orifice and left atrial free wall. The histological diagnosis was malignant undifferentiated sarcoma. Six months later, she noticed dyspnea and arm numbness due to local recurrence of cardiac tumor and brain metastasis. She died suddenly 6 months after the surgery during admission. The clinical and echocardiographic findings are crucial to discriminate malignant cardiac tumors from benign myxoma. Rapidly progressive clinical course, multiple tumor growth and non-septal attachment of the tumor all suggest a malignant profile of the primary cardiac tumors. Careful and precise preoperative evaluation, including echocardiographic survey of the tumor origin and multiple growth profile, are essential to identify malignant cardiac tumor.

J Cardiol 2002 Jun; 39(6): 321 - 325

Key Words

■Echocardiography, transesophageal

■Neoplasms (sarcoma, myxoma)

INTRODUCTION

The most common primary tumor of the heart is benign myxoma, followed by sarcoma¹⁾. However, these tumors are often difficult to discriminate preoperatively and the diagnosis mostly depends on the histological findings²⁾. We encountered a case of primary cardiac sarcoma mimicking benign myxoma, which illustrated the differential diagnosis between benign and malignant tumor in the heart.

CASE REPORT

A 53-year-old woman was transferred to our hos-

pital for removal of a cardiac tumor. Dyspnea and cough developed 4 weeks before admission, and became rapidly worse. She had been admitted to another hospital. Transthoracic echocardiography had shown an intracardiac mass in the left atrium. She had been diabetic and hypercholesterolemic for 15 years, which was controlled well by diet. She had no known history and no family history of cardiac disease.

On admission, she was orthopneic. The internal jugular vein was moderately distended at an angle of 45 degrees and bilateral basal rales were audible. Cardiac auscultation showed loud S₁, and grade / diastolic rumbling murmurs at the apex, radiat-

東京都済生会中央病院 循環器科: 〒108-0073 東京都港区三田1-4-17; *国立病院東京医療センター 循環器科, 東京
Department of Cardiology, Tokyo Saiseikai Central Hospital, Tokyo; *Department of Cardiology, National Tokyo Medical Center, Tokyo

Address for correspondence: HASEGAWA T, MD, Department of Cardiology, Tokyo Saiseikai Central Hospital, Mita 1-4-17, Minato-ku, Tokyo 108-0073

Manuscript received October 10, 2001; revised February 18, 2002; accepted March 6, 2002

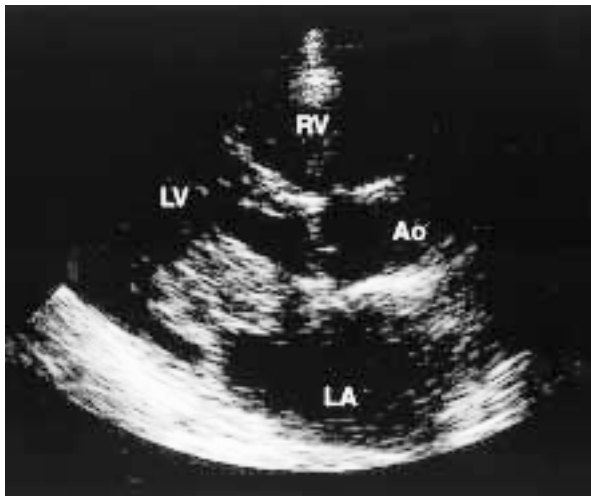


Fig. 1 Transthoracic echocardiogram in the parasternal long-axis view

A large mobile mass was observed in the left atrium, prolapsing into the mitral valve orifice in diastole. The tumor was not clearly visualized because of the poor image quality.

LV = left ventricle; RV = right ventricle; Ao = aorta; LA = left atrium.

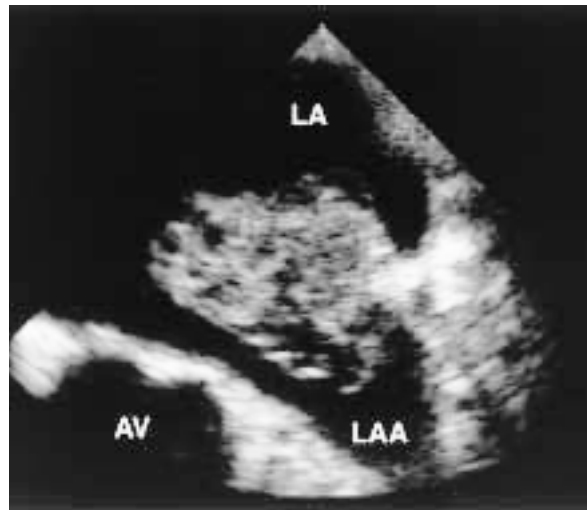


Fig. 2 Transesophageal echocardiogram (left atrial appendage view)

The stalk of the main tumor was clear and attached to the posterior free wall of the left atrium. The tumor size was 6 × 5 × 4 cm.

AV = aortic valve; LAA = left atrial appendage. Other abbreviation as in Fig. 1.

ing to the left lower sternum. Marked pedal edema and mildly distended abdomen with ascites were noted. Laboratory studies were normal except for elevated lactate dehydrogenase (1,336 IU/l). Electrocardiography on admission showed normal sinus rhythm of 88 beats/min. Chest radiography revealed venous redistribution patterns in both upper lung fields. She improved immediately after the dose of diuretics increased. Two weeks later, the dose of diuretics had to be doubled because of worsening heart failure.

Transthoracic echocardiography disclosed a large mass in the left atrium, which prolapsed into the left ventricle during diastole (Fig. 1). The attachment or origin was not clearly visualized. Transesophageal echocardiography demonstrated two separate masses in the left atrium. The larger mobile mass was pedunculated and attached to the posterior free wall of the left atrium (Fig. 2). This mass had prolapsed and obstructed transmitral blood flow. The smaller mass originated from the posterior mitral leaflet and looked immobile (Fig. 3). These two masses appeared clustered in shape, like benign myxoma.

The tumors were resected under a diagnosis of benign cardiac myxoma. Intraoperatively, three separate tumors were identified (Fig. 4). The first

originated from the posterior free wall of the left atrium, the second was attached to the atrial side of the posterior mitral leaflet, and the third arose from the left atrial posterior free wall just above the mitral valve. The third tumor was not identified preoperatively. The macroscopic appearance of all the tumors was soft, smooth, and lobulated, just like typical benign myxoma. The mitral valve was replaced by a prosthetic valve (SJM 19 mm) because of the tumor involvement. The histological diagnosis was undifferentiated sarcoma. She was discharged 3 weeks after the surgery.

Four months later, numbness of the left arm was suddenly noticed. Computed tomography of the head revealed multiple brain metastases. Soon after admission, worsening of dyspnea developed and transthoracic echocardiography identified local recurrence of the tumor in the left atrium. Her symptoms subsided transiently with medications, but she died 6 months after the surgery. Autopsy was not performed.

DISCUSSION

This case shows that the clinical and echocardiographic findings are essential to discriminate malignant cardiac tumor from benign myxoma.

Primary cardiac tumor is rare and only found in

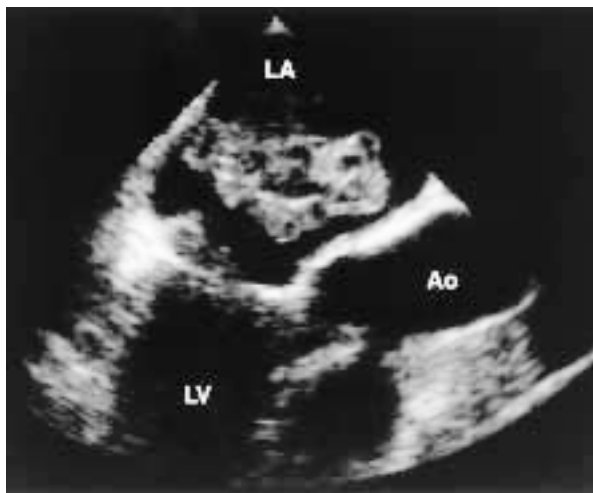


Fig. 3 Transesophageal echocardiogram (three-chamber view)

The tumor looked soft, smooth, and lobulated like benign myxoma. The other mass seemed to be attached to the posterior mitral leaflet.

Abbreviations as in Fig. 1.

0.0017 - 0.19% cases at autopsy¹). Three quarters of these tumors are benign, and nearly half of benign tumors are myxomas¹). Most malignant cardiac tumors are secondary. In surgical series, 77% of primary cardiac tumors were myxomas and only 10% were sarcomas²). Since almost all primary malignant tumors are sarcomas, the differential diagnosis of primary cardiac tumors should focus on discriminating benign myxomas and malignant sarcomas.

All primary tumors of the heart, whether malignant or benign, are potentially lethal as a result of intracavitary or valvular obstruction, peripheral embolization, and rhythm disturbances¹). Therefore, surgery should be performed as soon as possible after cardiac tumor is found¹). Surgical resection of benign myxoma results in complete cure in most cases, whereas resection of malignant sarcoma leads only to palliation of the symptoms and never contributes to long-term survival^{3,4}). Local recurrence and remote metastases of malignant sarcoma develop in a short period and the overall actuarial survival is 14% at 24 months after resection⁵). Patients with complete resection had a median survival of 24 months compared with only 10 months in all other patients⁵). Therefore, the preoperative differentiation of benign myxomas and malignant sarcomas is important for predicting the prognosis and applying additional therapy.

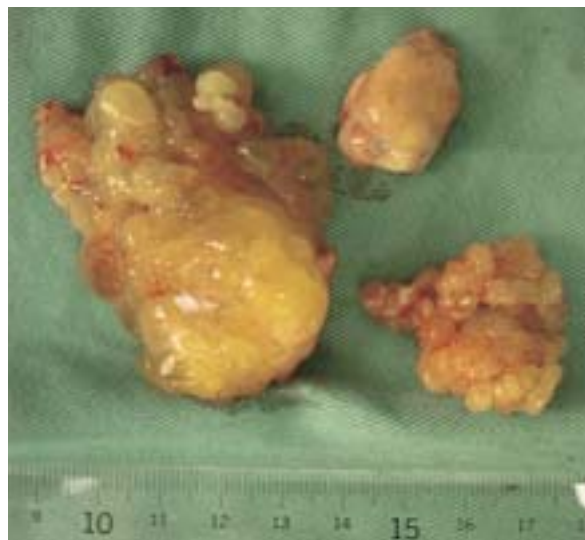

Fig. 4 Photographs of the resected tumors

The main tumor (left side) was $6 \times 5 \times 4$ cm in size, and was resected from the posterior free wall of the left atrium. The second tumor (upper right) was found at the posterior leaflet of the mitral valve, and was $1 \times 1 \times 1$ cm in size. The third tumor (lower right) was undetected preoperatively, was attached to the posterior free wall of the left atrium just above the mitral valve, and was $1 \times 1 \times 1$ cm in size.

Growth of a malignant tumor is so rapid that hemodynamic symptoms will appear prematurely. In fact, the time interval from symptom onset until final diagnosis is shorter for malignant cardiac sarcoma than benign myxoma. Average duration of symptoms was 15 months in benign myxomas, but 4.7 months in malignant sarcomas⁶). In the present case, we had to double the dose of diuretics twice before the operation because of worsening heart failure. Echocardiography showed the larger mass in the left atrium had prolapsed into the left ventricle and obstructed transmitral blood flow. Such progressive deterioration of the disease reflects the rapid tumor growth, and indicated malignant tumor.

The key diagnostic tool of cardiac tumors is transthoracic or transesophageal echocardiography⁷). About 90% of all myxomas originated from the left atrium and of these 70 - 90% were attached to the atrial septum around the fossa ovalis^{3,4,6,8}). On the other hand, malignant cardiac tumors are usually sporadic in origin. Angiosarcoma generally originates from the right atrium, and the majority of fibrosarcomas and malignant fibrous histiocytomas originate from the left atrium⁹). In our case, echocardiography showed two separate masses in

the left atrium. Both tumors arose from the posterior free wall of the left atrium and the mitral leaflet, not from the atrial septum. These locations are quite atypical of benign myxoma and also indicate malignant tumor.

Benign myxoma is usually a solitary tumor¹⁾. Four of 91 (4%) patients with myxoma had multiple masses in different cardiac chambers⁷⁾. In contrast, malignant cardiac sarcomas not infrequently form multiple masses. A clinical survey over 25 years at one institution showed that 5 of 21 patients (24%) with primary cardiac sarcoma had multiple origins of the tumor⁵⁾. In a series of surgical resections, 3 of 7 patients with primary cardiac sarcomas had multiple tumors in the heart, whereas only 1 of 57 patients with benign myxoma had two cardiac tumors⁴⁾. In the present case, at least two separate tumors were detected preoperatively in the left atrium. This finding also indicated a malignant tumor.

The echocardiographic appearances of cardiac tumors do not indicate the specific tumor type. Two-dimensional echocardiography shows two types of consistency even in benign myxomas⁸⁾. Eighteen of 25 cases with atrial myxoma had

deformable and jelly-like echocardiographic appearance, whereas the others were nondeformable and firm⁸⁾. The macroscopic appearance of deformable myxomas is gelatinous, papillary and friable, whereas the nondeformable tumors are smooth, firm and nonfriable⁸⁾. On the other hand, cardiac sarcomas have a wide range of cell differentiation⁹⁾, presumably because of the origin in an undifferentiated, pluripotential mesenchymal cell. Cardiac sarcomas often form intracavitary left atrial lesions with partial myxomatous change⁹⁾. These similarities make discrimination of benign myxoma from malignant sarcoma impossible by only the echocardiographic appearance.

In this case, the correct diagnosis of primary cardiac sarcoma could not be established preoperatively, although there were some indications of malignancy, including rapidly progressive clinical course, multiple tumor growth and non-septal attachment of the tumor. Correct identification of malignant cardiac tumor requires careful and precise preoperative evaluation, including echocardiographic survey of the tumor origin and multiple growth profile.

要 約

良性粘液腫に酷似していた心臓原発肉腫の1例

長谷川 祐 中川 晋 茅野 眞男
国 広 崇 宇井 進 木村 満

今回我々は心臓粘液腫と鑑別が困難であった心臓原発肉腫を経験したので報告する。症例は53歳、女性。急速に進行する心不全のため転院となった。経食道心エコー図法で左心房内に2つの腫瘍が認められた。腫瘍の付着部位と多発所見を除けば性状は粘液腫に酷似していた。術中所見では左房内に3つの腫瘍が認められ、左房後壁、僧帽弁後尖、左房後壁僧帽弁直上に付着していた。病理診断は分類不能型悪性肉腫であった。患者は一時退院したが、手術6ヵ月後、局所再発と脳転移により再入院となり、入院中に病棟で突然死した。本例は良性粘液腫と悪性肉腫の鑑別における、臨床所見・心エコー図所見の重要性を明示した点で教訓的である。急速に進行する心不全、心エコー図上の腫瘍の多発性、中隔以外への付着所見は、すべて悪性像を示唆するものである。心臓腫瘍の鑑別では正確かつ注意深い評価が求められるが、とくに心エコー図法で腫瘍の付着部位および腫瘍の多発性の有無を慎重に同定することが重要である。

J Cardiol 2002 Jun; 39(6): 321 - 325

References

- 1) Shapiro LM: Cardiac tumors : Diagnosis and management. *Heart* 2001 ; **85** : 218 - 222
- 2) Colucci WS, Schoen FJ: Primary tumors of the heart. *in Heart Disease: A Textbook of Cardiovascular Medicine* (ed by Braunwald E), 6th Ed. WB Saunders, Philadelphia, 2001 ; pp 1807 - 1822
- 3) Centofanti P, Di Rosa E, Deorsola L, Dato GMA, Patane F, La Torre M, Barbato L, Verzini A, Fortunato G, di Summa M: Primary cardiac tumors : Early and late results of surgical treatment in 91 patients. *Ann Thorac Surg* 1999 ; **68** : 1236 - 1241
- 4) Miralles A, Bracamonte L, Soncul H, Diaz del Castillo R, Akhtar R, Bors V, Pavie A, Gandjbackhch I, Cabrol C: Cardiac tumors : Clinical experience and surgical results in 74 patients. *Ann Thorac Surg* 1991 ; **52** : 886 - 895
- 5) Putnam JB Jr, Sweeney MS, Colon R, Lanza LA, Frazier OH, Cooley DA: Primary cardiac sarcomas. *Ann Thorac Surg* 1991 ; **51** : 906 - 910
- 6) Dein JR, Frist WH, Stinson EB, Miller DC, Baldwin JC, Oyer PE, Jamieson S, Mitchell RS, Shumway NE: Primary cardiac neoplasms : Early and late results of surgical treatment in 42 patients. *J Thorac Cardiovasc Surg* 1987 ; **93** : 502 - 511
- 7) Endo A, Ohtahara A, Kinugawa T, Mori M, Fujimoto Y, Yoshida A, Kuroda H, Mori T, Mashiba H, Shigemasa C: Characteristics of 161 patients with cardiac tumors diagnosed during 1993 and 1994 in Japan. *Am J Cardiol* 1997 ; **79** : 1708 - 1711
- 8) Fyke FE , Seqard JB, Edwards WD, Miller FA Jr, Reeder GS, Schattenberg TT, Schub C, Callahan JA, Tajik AJ: Primary cardiac tumors : Experience with 30 consecutive patients since the introduction of two-dimensional echocardiography. *J Am Coll Cardiol* 1985 ; **5** : 1465 - 1473
- 9) Burke A, Virmani R: Primary cardiac sarcomas : Tumors of the heart and great vessels. *in Atlas of Tumor Pathology*, 3rd series. Fascicle 12 Armed Forces Institute of Pathology, Washington DC, 1995 ; pp 127 - 170