

Evaluation of the Recurrence of Atrial Fibrillation After Pulmonary Venous Ablation

Hideko NAKASHIMA, MD
Koichiro KUMAGAI, MD, FJCC
Hiroo NOGUCHI, MD
Hideaki TOJO, MD
Tomoo YASUDA, MD
Keijiro SAKU, MD, FJCC

Abstract

Objectives. The mechanism of the recurrence of atrial fibrillation after pulmonary vein ablation was evaluated.

Methods. Eighty patients with atrial fibrillation underwent pulmonary vein ablation. If extrasystoles or atrial fibrillation initiations were frequent, focal ablation was performed at the site of the earliest activation. If the patient had little or no ectopy, all pulmonary veins with distinct and late pulmonary vein potentials were targeted for pulmonary vein isolation, which was achieved by minimal segmental ablation limited to the ostial site with the earliest pulmonary vein potentials.

Results. Focal ablation or pulmonary vein isolation was performed in 42 and 38 patients, respectively. After focal ablation, atrial fibrillation recurred in 23 patients and re-ablation was performed in 10: 7 at sites near the previous source, 2 at a different part of the same pulmonary vein, and 1 at a different pulmonary vein. After pulmonary vein isolation, atrial fibrillation recurred in 19 patients and re-ablation was performed in 14: 8 due to recovery of atrio-pulmonary vein conduction, 3 at non-pulmonary vein foci, 2 at pulmonary vein ostia proximal to the previous pulmonary vein isolation, and 1 at a different pulmonary vein.

Conclusions. After focal ablation, atrial fibrillation recurred from other foci in the same pulmonary vein or other pulmonary veins. Therefore, three or four pulmonary veins should be isolated. However, atrial fibrillation recurred after pulmonary vein isolation due to the recovery of atrio-pulmonary vein conduction or non-pulmonary vein foci. Further development of new mapping and ablation systems to detect the foci and create a complete lesion at the pulmonary vein ostium may be necessary.

J Cardiol 2002 Sep; 40(3): 87-94

Key Words

■ Atrial fibrillation ■ Ablation-catheter (pulmonary vein)

INTRODUCTION

Atrial fibrillation is a common and recurrent rhythm disorder usually poorly controlled by antiarrhythmic drugs. Focal atrial fibrillation is usually initiated by premature beats from the orifices of the pulmonary veins or from the myocardial sleeves inside the pulmonary veins, so radiofre-

quency catheter ablation of triggered foci could cure atrial fibrillation¹⁻⁴). However, detection of the exact focus is often difficult when atrial premature beats are infrequent, or each extrasystole may induce atrial fibrillation, necessitating repeated defibrillation. For these reasons, one catheter ablation technique uses applications of radiofrequency energy at segments of the pulmonary vein ostia,

福岡大学医学部 循環器科: 〒814-0180 福岡市城南区七隈7-45-1

Department of Cardiology, Fukuoka University School of Medicine, Fukuoka

Address for correspondence: KUMAGAI K, MD, FJCC, Department of Cardiology, Fukuoka University School of Medicine, Nanakuma 7-45-1, Jonan-ku, Fukuoka 814-0180

Manuscript received April 11, 2002; revised June 4, 2002; accepted June 25, 2002

guided by pulmonary vein potentials^{3,5}). However, previous studies of segmental pulmonary vein isolation found the recurrence rate is relatively high and a repeated ablation procedure is sometimes required¹⁻⁵). Therefore, the mechanism of the recurrence of paroxysmal atrial fibrillation after pulmonary venous ablation was evaluated.

SUBJECTS AND METHODS

Study population

The study population consisted of 80 patients (61 men and 19 women, mean age 60 ± 12 years) with paroxysmal atrial fibrillation refractory to medication (number of drugs, 3 ± 1 ; **Table 1**) who underwent electrophysiological study to identify the focal source of atrial fibrillation initiation. No structural heart disease was present in 35 patients. Hypertension was found in 30 patients, coronary artery disease in 8, mitral regurgitation in 4, and cardiomyopathy in 3. All antiarrhythmic drugs were discontinued for at least five half-lives before the study. Informed consent was obtained from all patients before the study.

Three multipolar electrode catheter (Daig Corp.) were positioned in the high right atrium, the His bundle area, and the distal coronary sinus. Pulmonary venous angiography was performed with an angiocatheter (Baxter Corp.) to determine the position of the catheters relative to the ostium of the pulmonary veins. After an atrial transseptal procedure, a long sheath (8-French, Daig Corp. SL-1) was passed into the left atrium through the foramen ovale.

Focal ablation

A sheath for three microcatheters (Trio Guide™ and Ensemble™ System, Cardiac Pathways Corp.) was then inserted into the SL-1 sheath and three 2-French quadripolar microcatheters were simultaneously passed into the left superior, left inferior and right superior pulmonary veins through this sheath (**Fig. 1**). After successfully placing the microcatheters in the pulmonary veins, the long sheath was pulled out into the right atrium, leaving the microcatheters in place (**Fig. 1**). Subsequently, a 7-French deflectable, quadripolar ablation catheter (Radii-T, Cardiac Pathways Corp.) was passed into the right inferior pulmonary vein directly through the foramen ovale, guided by the microcatheters (**Fig. 1**). Thus, electrograms could be acquired from all four pulmonary veins simultaneously.

Table 1 Patients receiving antiarrhythmic agents before and after ablation

	Before	After
Pilsicainide	62	8
Disopyramide	42	0
Flecainide	28	3
Cibenzoline	26	3
Aprindine	20	0
Beta-blocker	17	4
Bepidil	15	6
Pirmenol	14	0
Propafenone	9	0
Procainamid	9	0
Verapamil	8	1
Amiodarone	0	4

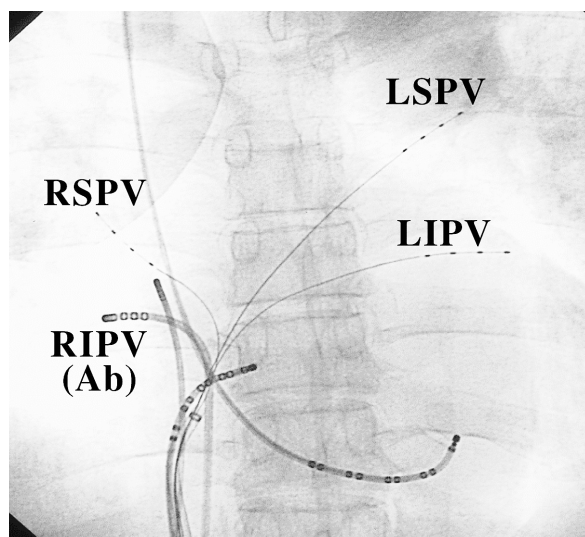


Fig. 1 Simultaneous mapping of all four pulmonary veins

Microcatheters were passed into the left superior, left inferior and right superior pulmonary veins, and an ablation catheter was passed into the right inferior pulmonary vein directly through the foramen ovale (posteroanterior view).

RSPV = right superior pulmonary vein; RIPV = right inferior pulmonary vein; Ab = ablation catheter; LSPV = left superior pulmonary vein; LIPV = left inferior pulmonary vein.

Bipolar intracardiac electrograms were recorded at a filter setting of 30 to 500 Hz and stored digitally on an EPMed system (Century Medical, Inc.) simultaneously with the surface electrocardiogram (ECG).

A programmed stimulator (SEC-3102, Nihon

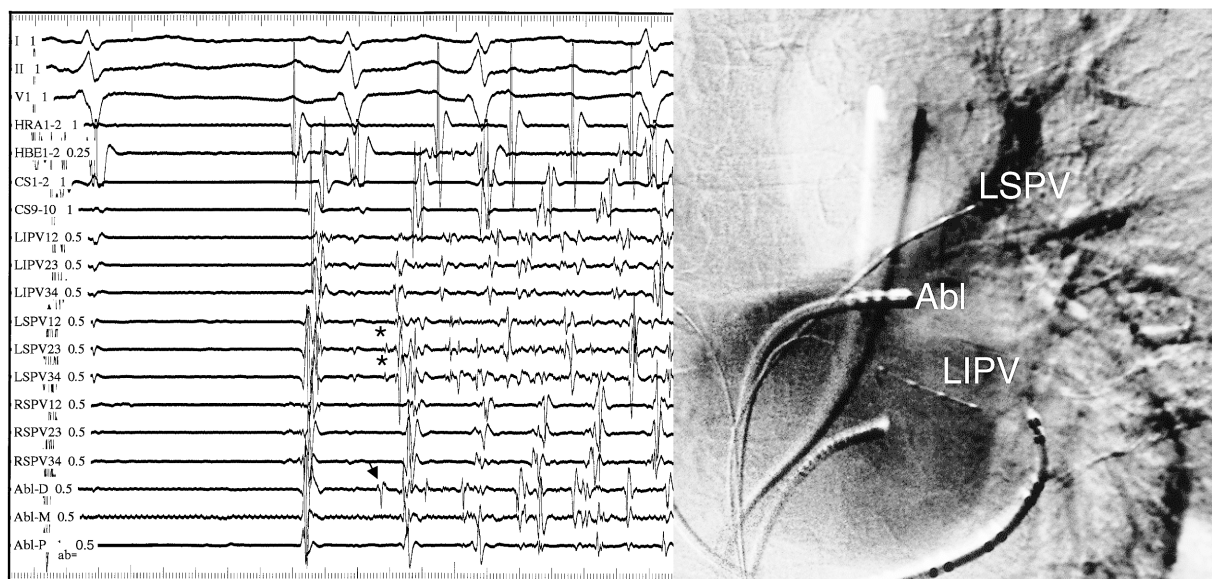


Fig. 2 Intracardiac electrogram tracings during the spontaneous onset of atrial fibrillation (left) and the successful ablation site (posteroanterior view, right)

If atrial fibrillation occurred reproducibly from the left superior pulmonary vein, the ablation catheter was moved to the left superior pulmonary vein and used to map the earliest local activity. The potential on the distal electrode pair of the ablation catheter (|) is earlier than that of microcatheters () Ablation of this site eliminated the atrial fibrillation.

HRA = high right atrium; HBE = His bundle electrogram; CS = coronary sinus; Abl = ablation catheter; D = distal; M = middle; P = proximal. Other abbreviations as in Fig. 1.

Koden) was used to deliver electrical stimuli at twice the diastolic threshold and 2 msec long. If atrial fibrillation did not occur spontaneously, burst atrial pacing or pharmacological agents or both were used to facilitate spontaneous atrial fibrillation. If the episode of induced atrial fibrillation was sustained for > 10 min, external cardioversion was attempted to defibrillate atrial fibrillation, and the spontaneous re-initiation of atrial fibrillation was monitored. Bipolar electrograms from the high right atrium, the His bundle area, the coronary sinus, and all four pulmonary veins during spontaneous atrial premature beats or atrial fibrillation initiations were recorded simultaneously. If extrasystoles or atrial fibrillation initiations were frequent, focal ablation was performed at the site of the earliest atrial activation (Fig. 2). The ablation site was selected on the basis of the earliest bipolar activity and/or a local unipolar QS pattern of the trigger atrial premature beats preceding atrial fibrillation from the pulmonary veins.

The three microcatheters used to map the trigger point of atrial fibrillation were left in the pulmonary veins to guide the ablation, and the ablation

catheter was inserted into the right inferior pulmonary vein and moved to the microcatheter with the earliest activity (Fig. 2). Moreover, one of the microcatheters with delayed activity was moved to the roof or bottom wall of the pulmonary vein with the earliest activity if necessary. If the patients had two or more trigger points in two or more pulmonary veins, ablation was performed sequentially. Radiofrequency pulses were delivered with the temperature preset to 50 °C (CABL-IT, Central Inc.) for 30 to 60 sec. The protocols used to induce spontaneous atrial fibrillation before ablation were repeated, and the effects of ablation were evaluated under isoproterenol infusion. Procedural success was defined as the inability to reinitiate atrial premature beats or atrial fibrillation with the same protocols used to induce atrial fibrillation before ablation.

Pulmonary venous isolation

If the patient had little or no ectopy, all pulmonary veins with distinct and late pulmonary vein potentials were targeted for pulmonary venous isolation. After a targeted pulmonary vein was identi-

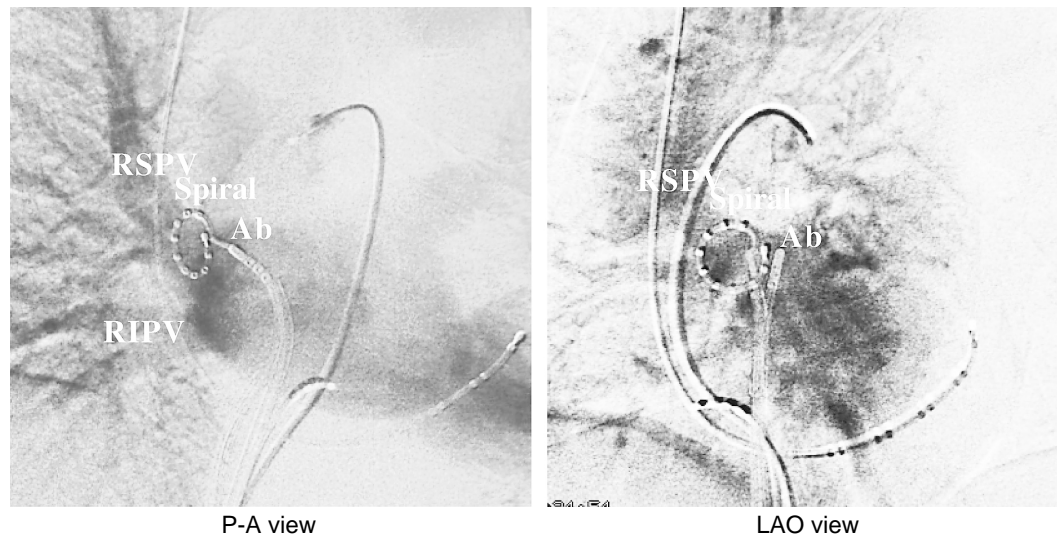


Fig. 3 Fluoroscopic appearance of a 10 pole circular catheter("Spiral SC")in the ostium of the right superior pulmonary vein

P-A = posteroanterior; LAO = left anterior oblique. Other abbreviations as in Fig. 1.

fied, a basket catheter(Constellation, EPT)or a circular 10-electrode catheter(" Spiral SC " ; Daig Corp.)was deployed in the pulmonary vein through a transseptal sheath(**Fig. 3**). Circumferential pulmonary vein electrograms were acquired simultaneously, and used to guide the ablation at ostial sites with the earliest pulmonary vein potentials during sinus rhythm for the right pulmonary veins or distal coronary sinus pacing for the left pulmonary veins. The source of ectopy as well as the electrical inputs from the atria to pulmonary vein could be determined. Radiofrequency pulses were delivered with the temperature preset to 50 ℃(CABL-IT, Central Inc.)with a power limit of 30W at ostial sites with the earliest pulmonary vein potentials while monitoring distal pulmonary vein potentials. If the activation sequence around the pulmonary vein ostium was changed, the bipole showing the new shortest atrio-pulmonary vein conduction was targeted(**Fig. 4**). The endpoint was determined as elimination of atrio-pulmonary vein conduction based on abolition of distal pulmonary vein potentials.

Follow-up

Heparin(500 U/hr)was continuously administered for 24 hr, and oral coumadin administration was continued for 1 month with an international normalized ratio level of about 2.0. Follow-up examination was continued for the patients at this institution, initially at 1 week and subsequently at

1-month intervals. Clinical examination, ECG and 24-hour Holter recordings were performed every 3 months and if symptoms suggested recurrence of arrhythmia. Transesophageal echocardiography was performed at 1 week, 3 and 6 months after ablation to assess thrombus or stenosis of the pulmonary veins. Ablation was considered successful if no recurrence of atrial fibrillation was present without drugs during the follow-up period.

RESULTS

Focal ablation

Focal ablation was performed in 42 patients. Ninety four of the 104 foci identified(90%)were located in the pulmonary vein: 34% in the left superior pulmonary vein, 32% in the right superior pulmonary vein, 21% in the left inferior pulmonary vein, and 3% in the right inferior pulmonary vein, and 10 foci(10%)were located in the atrial tissue: 6 in the right atrium, and 4 in the left atrium. The trigger points of atrial fibrillation were found in a single focus in 47% and multiple foci in 53%.

Atrial fibrillation recurred in 23 patients(55%) and re-ablation was performed in 10(24%): 7 in sites near the previous source, 2 in a different part of the same pulmonary vein, and 1 in a different pulmonary vein. Atrial fibrillation recurred at a median of 3 days(range, 1 to 60 days)after the first procedure. During the mean follow-up period of 21 ± 5 months, ablation eliminated atrial fibrilla-

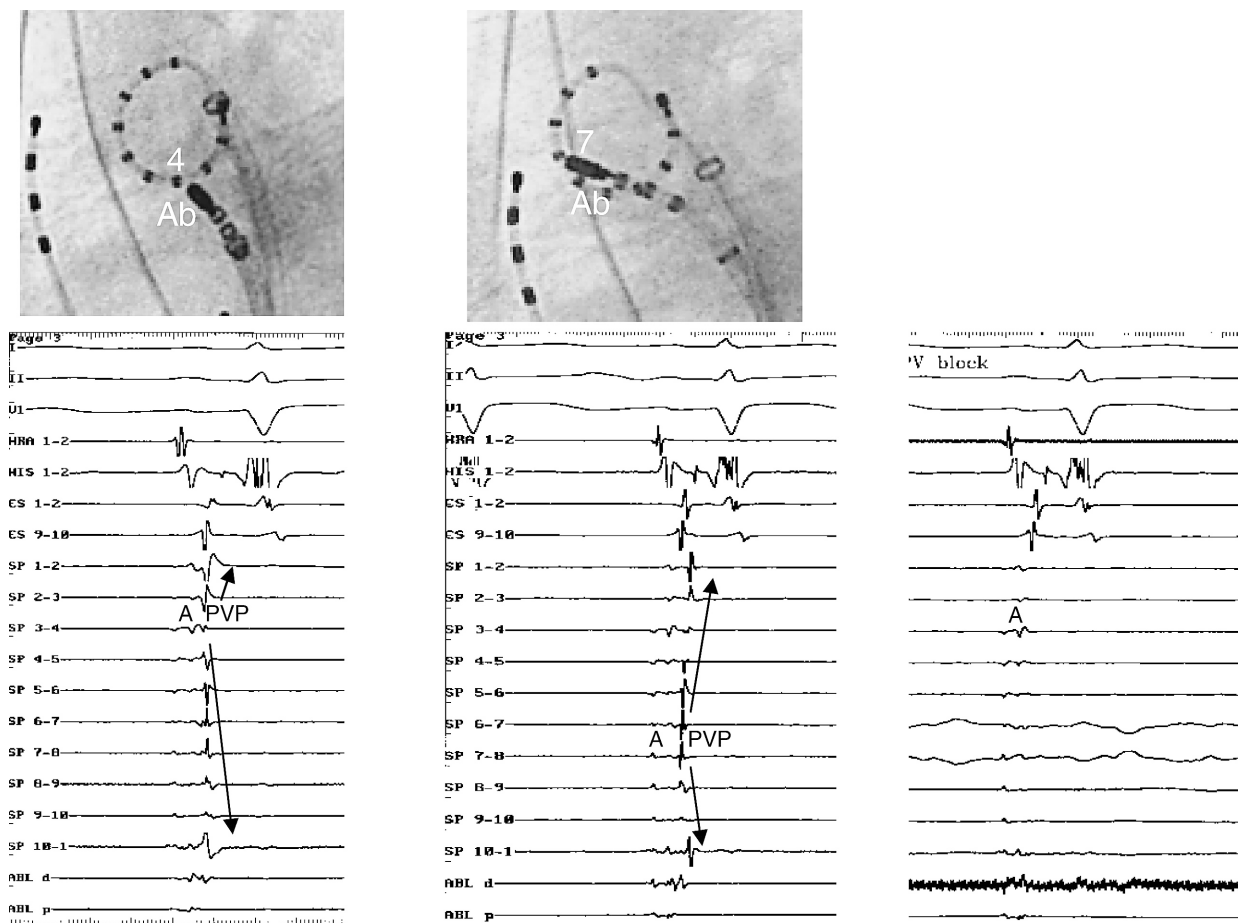


Fig. 4 Right superior pulmonary vein mapped using a circular catheter during sinus rhythm
Upper row: Ablation site. Lower row: Circumferential pulmonary vein potentials.
 Before ablation (left column), the earliest pulmonary vein potential is located in bipole 3 - 4 at the inferior wall of the vein. Local ablation proximal to this bipole changed in activation pattern with bipoles 6 - 7 and 7 - 8 becoming the earliest (middle column). Ablation of this secondary input blocked atrio-pulmonary venous conduction and eliminated all pulmonary vein potentials (right).
 A = atrial potential; PVP = pulmonary vein potential. Other abbreviation as in Fig. 1.

tion without drugs in 24 patients (57%) (Fig. 5). Two patients had pericardial effusion after successful ablation. However, the effusion disappeared spontaneously without drainage. No pulmonary vein stenosis was observed.

Pulmonary venous isolation

Pulmonary venous isolation was performed in 38 patients, and in 1 with recurrence of atrial fibrillation after focal ablation. One, two, three and four pulmonary veins were ablated in 9, 10, 18 and 1 patients, respectively. A total of 87 pulmonary veins, including 32 left superior, 31 right superior, 23 left inferior, and 1 right inferior pulmonary veins were ablated. The earliest pulmonary vein

potentials were localized to a segment of the circumference of the ostium, whereas the remaining perimeter was activated sequentially later. Ablation limited to a single segment blocked atrio-pulmonary vein conduction and abruptly eliminated all pulmonary vein potentials in 20 pulmonary veins (23%). Ablation of the secondary breakthrough eliminated all distal pulmonary vein potentials in 38 pulmonary veins (44%). Multiple radiofrequency applications to more than two segments were required to eliminate all distal pulmonary vein potentials in 29 pulmonary veins (33%). Pulmonary vein disconnection was achieved by less than three segmental ablations in 93% of all pulmonary veins. The electrical breakthrough points

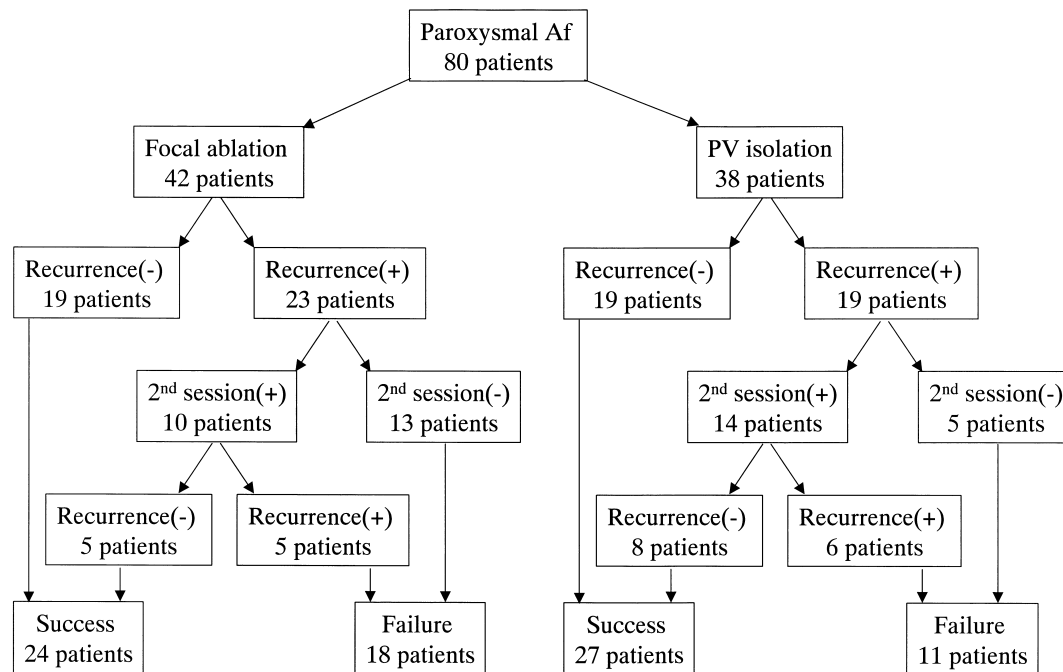


Fig. 5 Outcome of focal ablation and pulmonary vein isolation

Af = atrial fibrillation; PV = pulmonary vein.

were mainly located in the inferior wall in the superior pulmonary veins, and in the superior wall in the left inferior pulmonary vein.

Recurrence of atrial fibrillation was noted in 19 patients (50%) and re-ablation was performed in 14 (37%): 8 due to recovery of atrio-pulmonary vein conduction, 3 in non-pulmonary vein foci, 2 in pulmonary vein ostia proximal to previous pulmonary venous isolation, and 1 in a different pulmonary vein. Focal ablation was also performed in six patients with recurrence of atrial fibrillation from triggers. Atrial fibrillation recurred at a median of 3 days (range, 1 to 7 days) after the first procedure. Ablation eliminated atrial fibrillation without antiarrhythmic drugs in 27 (71%) patients during a follow-up period of 7 ± 5 months (Fig. 5). Four of 11 patients treated with antiarrhythmic drugs were free of symptomatic atrial fibrillation (Table 1). One patient had pericardial effusion after successful ablation. However, the effusion disappeared spontaneously without drainage. No complications including pulmonary vein stenosis were observed during follow-up.

DISCUSSION

Focal sources that trigger atrial fibrillation are located in the pulmonary veins, and radiofrequency

catheter ablation has been demonstrated to eliminate these pulmonary vein foci¹⁻³). Focal ablation targeting the site responsible for triggering atrial fibrillation results in cure of atrial fibrillation in 50% to 70% of patients¹⁻³). However, most patients require second procedures due to the recurrence of atrial fibrillation from a nearby or another focus in the same pulmonary vein or other pulmonary veins. Localization of the exact focus may be difficult because atrial premature beats may be infrequent, or each extrasystole may induce atrial fibrillation, necessitating repeated cardioversion. The premature beats that arise within the muscle sleeves of the pulmonary veins often are multifocal and may not manifest during an electrophysiological study. Therefore, present mapping and ablation techniques seem to have significant limitations.

Given the difficulty in precisely locating and ablating these triggers, an alternative approach that simply seeks to isolate electrically the pulmonary vein from the left atrium seems logical. Pulmonary venous isolation can be achieved at electrophysiological breakthroughs from the left atrium to the pulmonary vein⁵). As reported previously⁵), > 90% of pulmonary veins were electrically disconnected from the left atrium by targeting only certain segments of the ostial circumference, as guided by pul-

monary vein potentials. The results confirm that there are isolated fascicles that travel from the left atrium into the muscle sleeves that surround the pulmonary veins and that ablation of these fascicles, as opposed to circumferential ablation at the ostium, is sufficient to isolate the veins. The inability to isolate pulmonary veins may be attributable to anatomic variations in the geometry of the ostia that limit the optimal recording of pulmonary vein potentials with the decapolar ring catheter. In prior studies of segmental pulmonary vein isolation, only the pulmonary veins found to generate triggers of atrial fibrillation were isolated, and a large percentage of patients required additional ablation procedures^{3,5}.

In the present study, pulmonary vein isolation procedures targeted only the pulmonary veins that seemed to be arrhythmogenic. The right inferior pulmonary vein is often difficult to manipulate with a decapolar ring catheter, because it has the smallest muscle sleeve², so was not routinely isolated. However, in one patient, a focal source that triggered atrial fibrillation was located in the right inferior pulmonary vein, so this vein was also isolated. In half of the patients in the present study, three to four pulmonary veins were isolated. In another study⁶, the left superior, right superior, and left inferior pulmonary veins were always isolated and the right inferior pulmonary vein was also isolated whenever feasible. This approach was empiric and not based on identification of the arrhythmogenic pulmonary veins. A second pulmonary vein isolation procedure was performed in only 9% of the patients in that study, compared with 37% of patients in the present study. Therefore, more reliable results may be possible with empiric isolation of all pulmonary veins than with isolation of only the pulmonary veins that seem to be arrhythmogenic during the ablation procedure.

In the patients in this study who underwent a second procedure, recovery of conduction through the surrounding pulmonary veins was the most common reason for recurrent atrial fibrillation after pulmonary vein isolation. Possibly, some of the fasci-

cles were too thick to be ablated with conventional radiofrequency energy limited to 30 W. This would explain why a saline-irrigated ablation catheter, which creates deeper lesions than a conventional ablation catheter, was needed to isolate about 10% of pulmonary veins in a prior study⁵. Recovery of atrio-pulmonary vein conduction may have been prevented if the power of the radiofrequency energy applications had not been limited to 30 W. However, a conservative approach to ablation was favored to minimize the risk of pulmonary vein stenosis.

Another reason for recurrence of atrial fibrillation after pulmonary vein isolation was unmasked foci from the pulmonary vein ostial edge or atrial tissue. This is consistent with prior studies that have demonstrated that the foci that trigger paroxysmal atrial fibrillation arise from areas other than the pulmonary veins in 5% to 15% of patients^{1,2}. Pulmonary vein isolation must be supplemented by some other type of ablation procedure directed at the atrial tissue. The ideal catheter ablation strategy remains to be determined.

CONCLUSIONS

After focal ablation, atrial fibrillation recurred from other foci in the same pulmonary vein or other pulmonary veins. Therefore, three or four pulmonary veins should be isolated. Pulmonary veins can be electrically isolated from the left atrium by conventional applications of radiofrequency energy along segments of the ostia, guided by pulmonary vein potentials. Generally, three or four pulmonary veins can be isolated without creating pulmonary vein stenosis and the risk of other serious complications is low. However, atrial fibrillation recurred after pulmonary vein isolation due to the recovery of atrio-pulmonary vein conduction or non-pulmonary vein foci. Further development of new mapping systems including non-contact mapping to detect the foci and ablation systems including irrigation or laser catheters to create a complete lesion easily at the pulmonary vein ostium may be necessary.

要 約

肺静脈アブレーション後の心房細動の再発に関する検討

中島 英子 熊谷浩一郎 野口 博生
東條 秀明 安田 智生 朔 啓二郎

目的: 肺静脈アブレーション後の心房細動の再発の機序を検討した。

方法: 対象は肺静脈アブレーションを施行した心房細動80例である。心房細動が頻回に発生した場合は、心房細動発生時の最早期興奮部位に対し局所アブレーションを行った。心房細動が発生しない場合は、明らかに心房波から分離した肺静脈電位を有する肺静脈に対し電氣的肺静脈隔離法を行った。肺静脈開口部全周の肺静脈電位を同時記録し、肺静脈電位が最早期の開口部局所のみを焼灼した。エンドポイントは局所アブレーションでは心房細動の消失、肺静脈隔離法では肺静脈電位の消失あるいは心房-肺静脈間伝導ブロックの作成とした。

結果: 42例に局所アブレーションを行い、38例に肺静脈隔離法を行った。局所アブレーション後の23例で心房細動が再発し、そのうち10例で2回目のセッションを施行した。再発は前回の起源近傍からが7例、同じ肺静脈の異なる部位からが2例、異なる肺静脈からが1例であった。肺静脈隔離法後の19例で心房細動が再発し、そのうち14例で2回目のセッションを施行した。再発は心房-肺静脈間伝導の回復が8例、肺静脈以外の心房自由壁からが3例、前回の肺静脈隔離部位より近位の入口部縁からが2例、前回、肺静脈隔離法を行わなかった肺静脈からが1例であった。

結論: 局所アブレーション後、同じ肺静脈の異なる部位や異なる肺静脈から心房細動が再発した。そのため、3ないし4本の肺静脈に肺静脈隔離法を行う必要があると考えられた。しかし、肺静脈隔離法後、心房-肺静脈間伝導の回復や肺静脈以外の心房自由壁から心房細動が再発した。今後、起源部位を瞬時に同定するマッピング法と肺静脈開口部を完全に焼灼できるアブレーションシステムの開発が必要と考えられた。

J Cardiol 2002 Sep; 40(3): 87-94

References

- 1) Haissaguerre M, Jais P, Shah DC, Takahashi A, Hocini M, Quiniou G, Garrigue S, Le Mouroux A, Le Metayer P, Clementy J: Spontaneous initiation of atrial fibrillation by ectopic beats originating in the pulmonary veins. *N Engl J Med* 1998; **339**: 659 - 666
- 2) Chen SA, Hsieh MH, Tai CT, Tsai CF, Prakash VS, Yu WC, Hsu TL, Ding YA, Chang MS: Initiation of atrial fibrillation by ectopic beats originating from the pulmonary veins: Electrophysiological characteristics, pharmacological responses, and effects of radiofrequency ablation. *Circulation* 1999; **100**: 1879 - 1886
- 3) Haissaguerre M, Jais P, Shah DC, Garrigue S, Takahashi A, Lavergne T, Hocini M, Peng JT, Roudaut R, Clementy J: Electrophysiological end point for catheter ablation of atrial fibrillation initiated from multiple pulmonary venous foci. *Circulation* 2000; **101**: 1409 - 1417
- 4) Kumagai K, Gondo N, Matsumoto N, Noguchi H, Tojo H, Yasuda T, Nakashima H, Saku K: New technique for simultaneous catheter mapping of pulmonary veins for catheter ablation in focal atrial fibrillation. *Cardiology* 2000; **94**: 233 - 238
- 5) Haissaguerre M, Shar DC, Jais P, Hocini M, Yamane T, Deisenhofer I, Chauvin M, Garrigue S, Clementy J: Electrophysiological breakthroughs from the left atrium to the pulmonary veins. *Circulation* 2000; **102**: 2463 - 2465
- 6) Oral H, Knight BP, Tada H, Ozaydin M, Chugh A, Hassan S, Scharf C, Lai SWK, Greenstein R, Pelosi F Jr, Stickberger SA, Morady F: Pulmonary vein isolation for paroxysmal and persistent atrial fibrillation. *Circulation* 2002; **105**: 1077 - 1081