

Myocardial Enhancement on Magnetic Resonance Imaging With Gadolinium-Diethylenetriamine Pentaacetic Acid and Improvement of Left Ventricular Function in Patients With Dilated Cardiomyopathy

Masafumi AKISAWA, MD
 Yoshihisa MATSUMURA, MD
 Hiroaki KITAOKA, MD
 Naohito YAMASAKI, MD
 Jun TAKATA, MD
 Yoshinori DOI, MD, FJCC

Abstract

Objectives. This study evaluated the significance of myocardial gadolinium-diethylenetriamine pentaacetic acid (Gd-DTPA) enhancement on magnetic resonance imaging for the improvement of left ventricular function in patients with dilated cardiomyopathy.

Methods. Twenty-seven patients with dilated cardiomyopathy (mean age 59 ± 11 years) were studied. The magnitude of myocardial Gd-DTPA enhancement was quantitatively assessed using signal intensity ratio and compared to changes in left ventricular function and adverse cardiac events during a relatively long follow-up period.

Results. Regional high signal intensity ratio, defined as \geq mean + 2SD in seven normal subjects, was found in 14 patients: in three or more regions out of five myocardial regions analyzed in six patients (extensive enhancement) and in only one or two regions in eight patients (limited enhancement). The remaining 13 patients had no high signal ratio in any of the five regions analyzed (no enhancement). During the follow-up period of 3.9 ± 1.9 years, four patients died of cardiac causes. The incidence of cardiac death was 33.3% in patients with extensive enhancement, 12.5% in those with limited enhancement and 7.7% in those without enhancement, but there was no statistical difference. Mild improvement in fractional shortening was observed in patients without enhancement during the follow-up ($19 \pm 4\%$ vs $27 \pm 10\%$, $p = 0.03$).

Conclusions. Evaluation of myocardial Gd-DTPA enhancement on magnetic resonance imaging may provide useful prognostic information for patients with dilated cardiomyopathy.

J Cardiol 2002 Oct; 4(4): 145-152

Key Words

■ Cardiomyopathies, dilated ■ Prognosis ■ Magnetic resonance imaging (Gd-DTPA)

INTRODUCTION

Idiopathic dilated cardiomyopathy usually has a

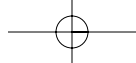
poor prognosis¹⁻⁴). However, some patients with dilated cardiomyopathy show an improvement in left ventricular systolic function⁵⁻¹¹). The clinical

高知医科大学 老年病科・循環器科 〒783-8505 高知県南国市岡豊町小蓮

Department of Medicine and Geriatrics, Kochi Medical School, Kochi

Address for correspondence: DOI Y, MD, FJCC, Department of Medicine and Geriatrics, Kochi Medical School, Kohasu, Oko-cho, Nankoku, Kochi 783-8505

Manuscript received March 8, 2002; revised August 19, 2002; accepted August 19, 2002



characteristics including hemodynamic variables determined at initial diagnosis are not associated with improvement in left ventricular systolic function^{5,7,8}), although pharmacological stress echocardiography with low dose dobutamine may be useful for predicting the recovery of systolic function¹²).

Magnetic resonance imaging with gadolinium-diethylenetriamine pentaacetic acid (Gd-DTPA) administration may have a potential role in characterizing abnormal myocardial tissue such as myocardial fibrosis, ischemia and degeneration of myocytes¹³⁻¹⁷), and is useful for assessing the severity of myocardial changes and left ventricular dysfunction in dilated and hypertrophic cardiomyopathy¹⁸⁻²³). However, the prognostic value of this noninvasive method is not known. This study assessed magnetic resonance imaging with Gd-DTPA administration as a method for predicting the recovery of systolic function and evaluating the clinical outcome in patients with dilated cardiomyopathy.

SUBJECTS AND METHODS

Patients population

This study included 27 consecutive patients with dilated cardiomyopathy (21 men and 6 women, aged 26 to 76 years [mean \pm SD, 59 \pm 11 years]) and seven healthy volunteers, seven men aged 26 to 33 years [mean \pm SD, 31 \pm 3 years]. All patients were in New York Heart Association Class (n = 23) or (n = 4) at the initial evaluation. A history was taken carefully from all the patients, followed by a physical examination, blood test, chest radiography, standard electrocardiography, 24-hour ambulatory Holter monitoring, echocardiography, and cardiac catheterization, including coronary angiography and biplane left ventriculography. Patients with acute myocarditis, significant coronary artery stenosis, valvular disease, or left ventricular end-diastolic volume below 85 ml/m² were excluded.

Magnetic resonance imaging

All magnetic resonance images were obtained with a commercially available 1.5-tesla superconducting magnet scanner (SIGNA, General Electric). The imaging sequence used was electrocardiography (ECG)-gated spin-echo with a flip angle of 90° and echo time of 20 msec. The repetition time was dependent on the heart rate, and equivalent to the R-R interval of the ECG. Imaging was done during systole using a trigger delay of

231 \pm 76 (mean \pm SD, range 55 - 385) msec after the R wave of the ECG. Imaging was taken in the left ventricular long-axis plane, which corresponded to the left ventriculogram in the 30° right anterior oblique projection. A multislice technique was used with a slice thickness of 10 mm (2.5 mm gap between slices). A matrix size of 256 \times 128 pixels was used for reconstruction. After the baseline magnetic resonance imaging, the imaging was repeated with the same pulse sequences 10 min after intravenous administration of 0.1 mM/kg of Gd-DTPA. The baseline and Gd-DTPA-enhanced images were then compared using the long-axis image for analysis.

Image analysis

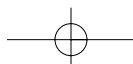
Quantitative evaluation of contrast enhancement was performed by computer assisted determination of the signal intensity. Regions of interest with an area of 0.92 cm² were used for analysis. Six regions of interest were chosen, five in the left ventricular myocardium and one in the skeletal muscles of an upper limb. The signal intensity was measured for each region, taking care not to include signals from intracavitary flow or epicardial fat. The corrected signal intensity of the myocardium was calculated by dividing the signal intensity of the myocardium by that of skeletal muscles^{24,25}). The signal intensity ratio of the myocardium was calculated as follows:

$$\text{Signal intensity ratio} = \frac{\text{Post-contrast corrected signal intensity}}{\text{Pre-contrast corrected signal intensity}}$$

The mean value of the signal intensity ratios was calculated by dividing the sum of the regional signal intensity ratio by the number of regions in each subject. One of 135 regions was excluded due to poor visualization.

Echocardiography

TOSHIBA SSH160A ultrasound equipment with a 2.5- or 3.75-MHz transducer was used to derive standard views for the comprehensive, two-dimensional, spectral pulsed-wave Doppler, and color flow Doppler studies. The standard technique was employed for measuring the size of the left ventricle. Left ventricular fractional shortening was calculated as previously described²⁶). Left ventricular inflow velocities were obtained from the apical four-chamber view, using pulsed-wave Doppler echocardiography, by placing the sample volume at the leaflet tips of the mitral valve²⁷). The Doppler measurements included the left ventricular inflow



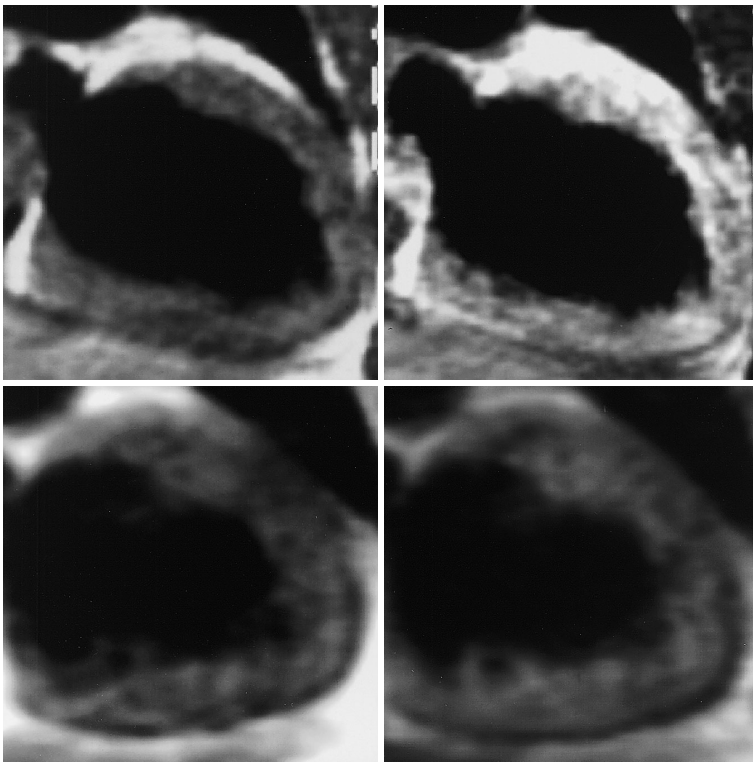


Fig. 1 Magnetic resonance images

Upper row: Vertical long-axis magnetic resonance images of a patient with extensive Gd-DTPA enhancement, obtained before (*left*) and after (*right*) injection of Gd-DTPA. Increased signal intensity was observed in the anteroapical region.

Lower row: Vertical long-axis magnetic resonance images of a patient without Gd-DTPA enhancement, obtained before (*left*) and after (*right*) injection of Gd-DTPA. No significant increase in signal intensity was observed.

Gd-DTPA = gadolinium-diethylenetriamine pentaacetic acid.

early (E) and late (A) diastolic peak velocities, as well as the E/A ratio for each cardiac cycle.

Holter electrocardiography

All patients underwent 24-hour ambulatory ECG monitoring. Nonsustained ventricular tachycardia was defined as ≥ 3 consecutive ventricular premature complexes at a mean rate of more than 120 beats/min.

Cardiac catheterization

Left heart catheterization and coronary angiography were performed in all patients. Biplanar left ventriculography was performed in the 30° right anterior oblique and 60° left anterior oblique projections. Significant coronary artery stenosis was defined as $\geq 50\%$ reduction of the luminal diameter in the left anterior descending, left circumflex or right coronary arteries.

Follow-up

The mean (\pm SD) follow-up period was 3.9 ± 1.9 years. Clinical outcome was obtained in all patients. Follow-up echocardiography was obtained in all patients except four patients with Gd-DTPA enhancement who died during the follow-up.

Statistical analysis

Results are expressed as mean \pm SD. A chi-square test was used to compare categorical variables, and Student's *t*-test to compare continuous variables. A paired *t*-test was used to compare the changes in signal intensity. A *p* value < 0.05 was considered statistically significant.

RESULTS

Signal intensity ratio of the myocardium

The signal intensity ratio of the five myocardial regions ranged from 1.013 ± 0.011 to 1.021 ± 0.019 in patients with dilated cardiomyopathy, and from 1.005 ± 0.009 to 1.009 ± 0.006 in healthy volunteers. The mean value of signal intensity ratio was higher in patients with dilated cardiomyopathy than in healthy volunteers (1.016 ± 0.011 vs 1.006 ± 0.007 , $p < 0.05$).

Gd-DTPA enhancement in dilated cardiomyopathy

High signal intensity ratio was defined as a regional signal intensity ratio \geq mean + 2SD of seven normals, as reported previously¹⁸). In patients with dilated cardiomyopathy, 36 myocardial regions had a high signal intensity ratio (Gd-DTPA enhancement), whereas 98 myocardial regions were without enhancement (Fig. 1). Fourteen

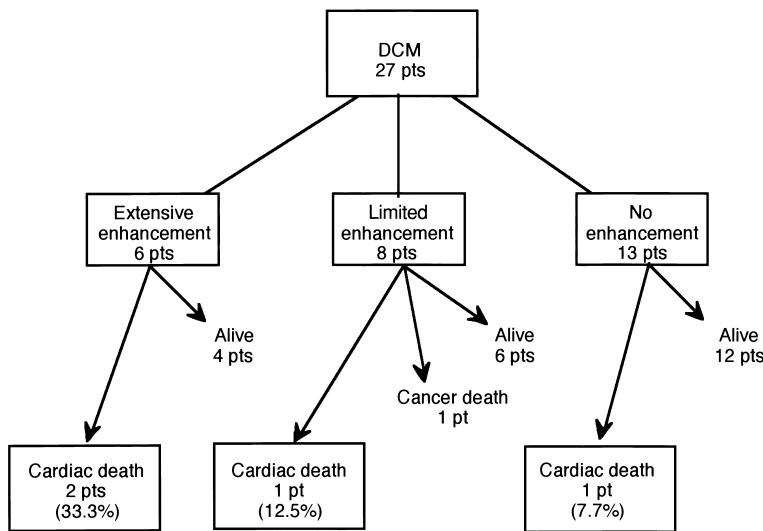
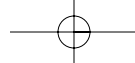


Fig. 2 Results of magnetic resonance imaging with Gd-DTPA and clinical outcome in 27 patients with dilated cardiomyopathy
 DCM = dilated cardiomyopathy; p(s) = patient(s). Other abbreviation as in Fig. 1.

Table 1 Baseline and echocardiographic characteristics

	Enhancement (n = 14)	No enhancement (n = 13)	p value
Age(yr)	60 ± 9	58 ± 13	NS
Male	11(79)	10(77)	NS
LVDd(mm)	63 ± 6	61 ± 5	NS
LVDs(mm)	53 ± 7	49 ± 6	NS
FS(%)	16 ± 5	19 ± 4	0.05
E(cm/sec)	68 ± 38	51 ± 14	NS
E/A	1.4 ± 1.1	0.8 ± 0.3	NS
Medication			
Digitalis	10(71)	10(77)	NS
Diuretics	12(86)	11(85)	NS
ACE-inhibitor	11(79)	11(85)	NS
Beta-blocker	2(14)	4(31)	NS
Antiarrhythmic drugs	5(36)	2(15)	NS

Continuous values mean ± SD. () : %.

LVDd = left ventricular diastolic dimension; LVDs = left ventricular systolic dimension; FS = fractional shortening; E = early diastolic peak velocity; A = late diastolic peak velocity; ACE = angiotensin converting enzyme.

patients had Gd-DTPA enhancement in at least one region, of whom six patients had Gd-DTPA enhancement in three or more regions(extensive enhancement)and eight patients in one or two regions(limited enhancement). The remaining 13 patients had no regional high signal intensity ratio in any of the five regions(no enhancement; **Fig. 2**). Basic and echocardiographic characteristics are shown in **Table 1**. Fractional shortening was better in patients without enhancement at the baseline ($p < 0.05$). Other variables did not show any dif-

ference between the two groups.

Adverse clinical outcome

During the follow-up period of 3.9 ± 1.9 years (0.5 - 7.1 years), four patients died of cardiac causes; three from heart failure and one from sudden death. One patient died of malignant disease. There were no differences in the use of cardioactive medications between patients with Gd-DTPA enhancement and those without enhancement(**Table 1**). The incidence of cardiac death was not statistically

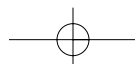


Table 2 Changes in left ventricular function in patients with and without Gd-DTPA enhancement

	Extensive and limited enhancement (n = 10)		No enhancement (n = 13)	
	Baseline	Follow-up	Baseline	Follow-up
LVDd (mm)	63 ± 5	63 ± 15	61 ± 5	57 ± 7
LVDs (mm)	52 ± 6	52 ± 17	49 ± 6	42 ± 11*
FS (%)	17 ± 3	18 ± 7	19 ± 4	27 ± 10**

Values are mean ± SD. Follow-up echocardiography was not obtained in four patients who died during the follow-up

*p = 0.09, **p = 0.03

Abbreviations as in Fig. 1, Table 1.

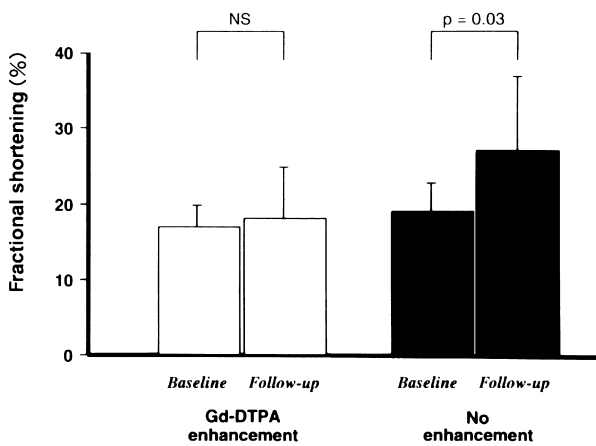


Fig. 3 Changes in fractional shortening in patients with Gd-DTPA enhancement (extensive plus limited) and in those without enhancement during the follow-up period of 3.9 ± 1.9 years

Abbreviation as in Fig. 1.

different in patients with extensive enhancement (33.3%), compared to those with limited enhancement (12.5%) and those without enhancement (7.7%; Fig. 2)

Changes in left ventricular function

Follow-up echocardiography showed no significant difference in left ventricular diastolic and systolic dimensions, and fractional shortening at the initial evaluation between patients with extensive or limited enhancement and those without enhancement (Table 2). At the last follow-up, a significant improvement in fractional shortening was observed in patients without enhancement (19 ± 4% → 27 ± 10%, p = 0.03) compared to those with enhancement (Fig. 3), although left ventricular size showed no significant change in either group.

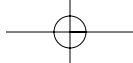
Ventricular tachycardia

Ventricular tachycardia was found by Holter ECG in three of six patients with extensive enhancement (50%), in three of eight patients with limited enhancement (38%), and in three of 13 patients without enhancement (23%).

DISCUSSIONS

The most important finding of this study is that fractional shortening improved with medical therapy in dilated cardiomyopathy patients without myocardial Gd-DTPA enhancement during the relatively long follow-up period. Also, two of the six patients with extensive myocardial enhancement at baseline died of cardiac causes.

Dilated cardiomyopathy, which is usually characterized by dilated left ventricle and impaired pump function, has a poor prognosis¹⁻⁴. Early retrospective studies from tertiary referral centers found mortality rates were 25% to 30% at 1 year and approximately 50% at 5 years^{1,2}. However, more recent observations suggest a better prognosis, with a 5-year mortality of 20%^{3,4}. Referral bias, earlier detection of the disease, and better treatments with angiotensin converting enzyme-inhibitors and beta-blockades may be related to this improvement in prognosis. Although the majority of deaths occur within 2 to 3 years of the onset of symptoms, some patients may have a prolonged period of clinical stability. Moreover, spontaneous improvement in left ventricular systolic function occurs in 20% to 45% of patients with dilated cardiomyopathy⁵⁻⁷. This improvement in left ventricular function is independent of the hemodynamic parameters determined at the initial examination^{5,7,8}. Although the extent of myocardial fibrosis in endomyocardial biopsies has been helpful in



assessing later improvement in left ventricular function⁸⁻¹¹), the noninvasive prediction of such improvement is desirable and of clinical importance, particularly in relation to the indication for heart transplantation²⁸).

Gd-DTPA is rapidly distributed from the intravascular to the extracellular fluid compartment by biological membranes due to its hydrophilicity, charge and molecular weight, and is then excreted unchanged through the kidney²⁴). About 50% of the injected Gd-DTPA is cleared from the capillaries during the first pass. Gd-DTPA with a biological half-life of 20 min is largely washed out in the normal tissue by 10 - 15 min after injection. Gd-DTPA enhancement is influenced by regional Gd-DTPA concentration and proton density^{24,29}). Gd-DTPA concentration may be related to several factors, including differences in the blood flow, vascular permeability, and interstitial structure. The effect of enhancement is determined by the amount of vascularization, cellular damage, and size of the extracellular space of the myocardium.

Magnetic resonance imaging with Gd-DTPA is useful for myocardial tissue characterization in patients with myocardial infarction, and hypertrophic and dilated cardiomyopathy¹⁷⁻²³). A case of hypertrophic cardiomyopathy showed high signal intensity of the hypertrophic ventricular wall²⁰). This high signal intensity of the myocardium was also found in patients with hypertrophic cardiomyopathy and impaired left ventricular function^{22,23}). Myocardial fibrosis and subendocardial ischemia are thought to be the cause of increased signal intensity in the myocardium. Extensive myocardial Gd-DTPA enhancement has been correlated to impaired systolic and diastolic function in patients with dilated cardiomyopathy, so the Gd-DTPA enhancement of the myocardium may indicate advanced myocardial changes such as extensive

and severe fibrosis^{18,19}). The absence of such myocardial enhancement in magnetic resonance imaging may suggest less severe myocardial changes, as indicated by the present study. The prediction of adverse clinical outcome based on magnetic resonance imaging with Gd-DTPA seems difficult and larger studies are needed to define the significance of extensive myocardial Gd-DTPA enhancement in the prediction of adverse outcome in patients with dilated cardiomyopathy.

The limitations of this study include the small number of patients studied. Myocardial enhancement was quantified on a long-axis view of the magnetic resonance imaging. Changes in myocardial intensity were distributed more or less uniformly over the entire myocardium in patients with dilated cardiomyopathy, although focal processes may have affected our quantitative analysis. Also, myocardial biopsies were not performed, although we excluded patients with clinical indications of myocarditis or secondary myocardial disease.

In conclusion, magnetic resonance imaging with Gd-DTPA may be useful for myocardial tissue characterization and the noninvasive prognosis in patients with dilated cardiomyopathy. Absence of myocardial Gd-DTPA enhancement is suggestive of a prolonged period of clinical stability and future improvement of left ventricular systolic function. Such clinical information, together with information from low dose dobutamine stress echocardiography, is particularly useful when clinicians have to decide whether or not heart transplantation is needed.

Acknowledgments

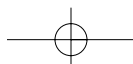
We thank Professor Shoji Yoshida and Dr. Akihiro Sawada, Department of Radiology, Kochi Medical School, for their pertinent advice throughout the study.

要 約

拡張型心筋症における磁気共鳴画像心筋ガドリニウム - ジエチレントリアミン 五酢酸造影効果と左室機能改善

秋澤 雅史 松村 敬久 北岡 裕章
山崎 直仁 高田 淳 土居 義典

目 的: 拡張型心筋症における磁気共鳴画像心筋ガドリニウム(Gd)-ジエチレントリアミン五酢酸(DTPA)造影効果と左室機能改善の関連性について検討する。



方 法: 拡張型心筋症患者 27 例(平均年齢 59 ± 11 歳)を対象として, 磁気共鳴画像の心筋 Gd-DTPA 造影効果の程度を定量的に評価し, 長期経過観察後の左室機能変化および心事故との関連性を検討した.

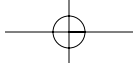
結 果: 心筋の信号強度の増強(正常 7 例の平均 + 2 標準偏差以上と定義)は, 解析を行った長軸画像 5 領域の中で, 14 例の患者にみられた. そのうち, 6 例では 3 領域以上に信号強度の増強(広範囲造影)が認められた. 8 例では 2 領域以下(小範囲造影)であった. 残り 13 例では, 5 領域いずれにも信号強度の増強は認められなかった(非造影). 3.9 ± 1.9 年の経過観察で, 4 例の心臓死が確認された. 心臓死の頻度は 3 群間で有意差を認めなかったが, 広範囲造影群(33.3%)で小範囲造影群(12.5%)ないし非造影群(7.7%)より多い傾向を認めた. また, 左室短縮率は非造影群でのみ改善を示した($19 \pm 4\%$ vs $27 \pm 10\%$, $p = 0.03$).

結 論: 磁気共鳴画像における Gd-DTPA 造影効果の定量評価は, 拡張型心筋症患者の予後を評価するうえで, 臨床的に有用な情報を提供するものと考えられる.

J Cardiol 2002 Oct; 40(4): 145 - 152

References

- 1) Fuster V, Gersh BJ, Giuliani ER, Tajik AJ, Brandenburg RO, Frye RL: The natural history of idiopathic dilated cardiomyopathy. *Am J Cardiol* 1981; **47**: 525 - 531
- 2) Ikram H, Williamson HG, Won M, Crozier IG, Wells EJ: The course of idiopathic dilated cardiomyopathy in New Zealand. *Br Heart J* 1987; **57**: 521 - 527
- 3) Sugrue DD, Rodeheffer RJ, Codd MB, Ballard DJ, Fuster V, Gersh BJ: The clinical course of idiopathic dilated cardiomyopathy: A population-based study. *Ann Intern Med* 1992; **117**: 117 - 123
- 4) Abelmann WH: Classification and natural history of primary myocardial disease. *Prog Cardiovasc Dis* 1984; **27**: 73 - 94
- 5) Francis GS, Johnson TH, Ziesche S, Berg M, Boosalis P, Cohn JN: Marked spontaneous improvement in ejection fraction in patients with congestive heart failure. *Am J Med* 1990; **89**: 303 - 307
- 6) Steimle AE, Stevenson LW, Fonarow GC, Hamilton MA, Moriguchi JD: Prediction of improvement in recent onset cardiomyopathy after referral for heart failure. *J Am Coll Cardiol* 1994; **23**: 553 - 559
- 7) Cross AM Jr, Steenbergen C, Higginbotham MB: Recovery of left ventricular function in acute nonischemic congestive cardiomyopathy. *Am Heart J* 1995; **129**: 24 - 30
- 8) Figulla HR, Rahlf G, Nieger M, Luig H, Kreuzer H: Spontaneous hemodynamic improvement or stabilization and associated biopsy findings in patients with congestive cardiomyopathy. *Circulation* 1985; **71**: 1095 - 1104
- 9) Yamada T, Fukunami M, Ohmori M, Iwakura K, Kumagai K, Kondoh N, Minamino T, Tsujimura E, Nagareda T, Katoh K, Hoki N: Which subgroup of patients with dilated cardiomyopathy would benefit from long-term β -blocker therapy?: A histologic viewpoint. *J Am Coll Cardiol* 1993; **21**: 628 - 633
- 10) Regan TJ: Alcoholic cardiomyopathy. *Prog Cardiovasc Dis* 1984; **27**: 141 - 152
- 11) Schwarz F, Mall G, Zebe H, Blickle J, Derks H, Manthey J, Kubler W: Quantitative morphologic findings of the myocardium in idiopathic dilated cardiomyopathy. *Am J Cardiol* 1983; **51**: 501 - 506
- 12) Kitaoka H, Takata J, Yabe T, Hitomi N, Furuno T, Doi YL: Low dose dobutamine stress echocardiography predicts the improvement of left ventricular systolic function in dilated cardiomyopathy. *Heart* 1999; **81**: 523 - 527
- 13) Weinmann HJ, Brasch RC, Press WR, Wesbey GE: Characteristics of gadolinium-DTPA complex: A potential NMR contrast agent. *AJR Am J Roentgenol* 1984; **142**: 619 - 624
- 14) Brasch RC, Weinmann HJ, Wesbey GE: Contrast-enhanced NMR imaging: Animal studies using gadolinium-DTPA complex. *AJR Am J Roentgenol* 1984; **142**: 625 - 630
- 15) Carr DH, Brown J, Bydder GM, Steiner RE, Weinmann HJ, Speck U, Hall AS, Young IR: Gadolinium-DTPA as a contrast agent in MRI: Initial clinical experience in 20 patients. *AJR Am J Roentgenol* 1984; **143**: 215 - 224
- 16) Brown JJ, Higgins CB: Myocardial paramagnetic contrast agents for MR imaging. *AJR Am J Roentgenol* 1988; **151**: 865 - 871
- 17) de Roos A, Doornbos J, van der Wall EE, van Voorthuisen AE: MR imaging of acute myocardial infarction: Value of Gd-DTPA. *AJR Am J Roentgenol* 1988; **150**: 531 - 534
- 18) Matsumura Y, Takata J, Sawada A, Furuno T, Yoshida S, Doi YL: Magnetic resonance imaging in dilated cardiomyopathy: Significance of extensive myocardial gadolinium-DTPA enhancement. *J Noninvas Cardiol* 1999; **3**: 154 - 160
- 19) Koito H, Suzuki J, Ohkubo N, Ishiguro Y, Iwasaka T, Inada M: Gadolinium-diethylenetriamine pentaacetic acid enhanced magnetic resonance imaging of dilated cardiomyopathy: Clinical significance of abnormal high signal intensity of left ventricular myocardium. *J Cardiol* 1996; **28**: 41 - 49 (in Jpn with Eng abstr)
- 20) Farmer D, Higgins CB, Yee E, Lipton MJ, Wahr D, Ports T: Tissue characterization by magnetic resonance imaging in hypertrophic cardiomyopathy. *Am J Cardiol* 1985; **55**: 230 - 232
- 21) Tsukihashi H, Ishibashi Y, Shimada T, Hatano J, Tanabe K, Ooyake N, Morioka S, Moriyama K: Changes in gadolini-



- um-DTPA enhanced magnetic resonance signal intensity ratio in hypertrophic cardiomyopathy. *J Cardiol* 1994; **24**: 185 - 191(in Jpn with Eng atstr)
- 22) Nishimura T, Nagata S, Sakakibara H: Magnetic resonance imaging in familial hypertrophic cardiomyopathy associated with abnormal thallium perfusion and cardiac enzyme. *Jpn Circ J* 1988; **52**: 395 - 400
- 23) Koito H, Suzuki J, Nakamori H, Ohkubo N, Wakayama Y, Iwasaka T, Inada M, Katoh T: Clinical significance of abnormal high signal intensity of left ventricular myocardium by gadolinium-diethylenetriamine pentaacetic acid enhanced magnetic resonance imaging in hypertrophic cardiomyopathy. *J Cardiol* 1995; **25**: 163 - 170(in Jpn with Eng abstr)
- 24) Schmiedl U, Moseley ME, Ogan MD, Chew WM, Brasch RC: Comparison of initial biodistribution patterns of Gd-DTPA and albumin-(Gd-DTPA)using rapid spin echo MR imaging. *J Comput Assist Tomogr* 1987; **11**: 306 - 313
- 25) Williams CT, Stack JP, Loveday B, Waston Y, Isherwood I: Magnetic resonance imaging of the mini-pig heart: The effect of gadolinium-DTPA on normal myocardium. *Br J Radiol* 1988; **61**: 596 - 599
- 26) Sahn DJ, DeMaria A, Kisslo J, Weyman A, The committee on M-mode standardization of the American Society of Echocardiography: Recommendations regarding quantitation of M-mode echocardiography: Results of a survey of echocardiographic measurements. *Circulation* 1978; **58**: 1072 - 1083
- 27) Appleton CP, Hatle LK, Popp RL: Relation of transmittal flow velocity patterns to left ventricular diastolic function: New insights from a combined hemodynamic and Doppler echocardiographic study. *J Am Coll Cardiol* 1988; **12**: 426 - 440
- 28) Dec GW, Fuster V: Idiopathic dilated cardiomyopathy. *N Engl J Med* 1994; **331**: 1564 - 1575
- 29) Schaefer S, Malloy CR, Katz J, Parkey RW, Buja LM, Willerson JT, Peshock RM: Gadolinium-DTPA-enhanced nuclear magnetic resonance imaging of reperfused myocardium: Identification of the myocardial bed at risk. *J Am Coll Cardiol* 1988; **12**: 1064 - 1072

