

## Cardiovascular Imaging In-a-Month

### Diastolic Musical Murmur Changing With Cardiac Cycle

Naoyuki SATA, MD

Yukinori MORIYAMA, MD

Naokazu HAMADA, MD

\*

Takashi HORINOUCHI, MD

Kenkichi MIYAHARA, MD

#### CASE

A 48-year-old man with a cardiac murmur was referred and admitted to our hospital. The patient had been suffering from exertional dyspnea for a year. Auscultation detected a Levine / diastolic musical murmur, which was variable in intensity with each cardiac cycle, in the right sternal border of the third intercostal area (Fig. 1). No arrhythmia was observed.

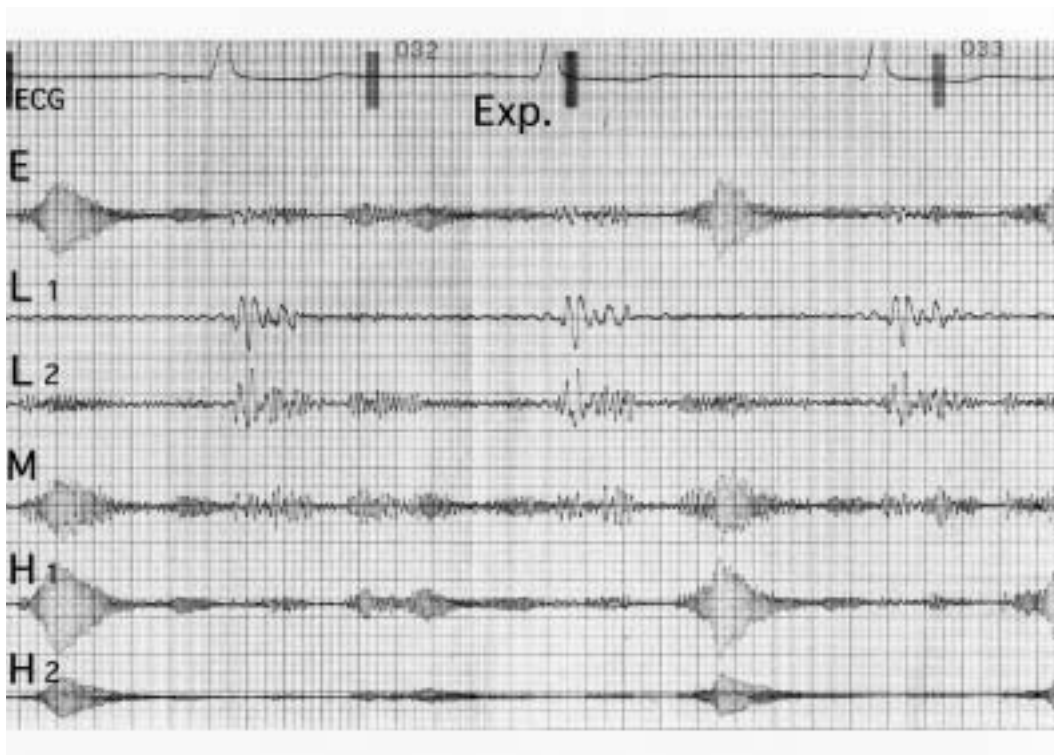

Fig. 1

新杏病院 循環器科(佐多直幸, 濱田直和, 堀之内尚志, 宮原健吉), \*心臓血管外科(森山由紀則): 〒 890 - 0073 鹿児島県鹿児島市宇宿3 - 41 - 1

Divisions of Cardiology and \* Cardiovascular Surgery, Shinkyo Hospital, Kagoshima

Address for correspondence: SATA N, MD, Division of Cardiology, Shinkyo Hospital, Usuki 3 - 41 - 1, Kagoshima, Kagoshima 890 - 0073

Manuscript received February 20, 2003; revised March 3, 2003; accepted March 8, 2003

### Points for Diagnosis

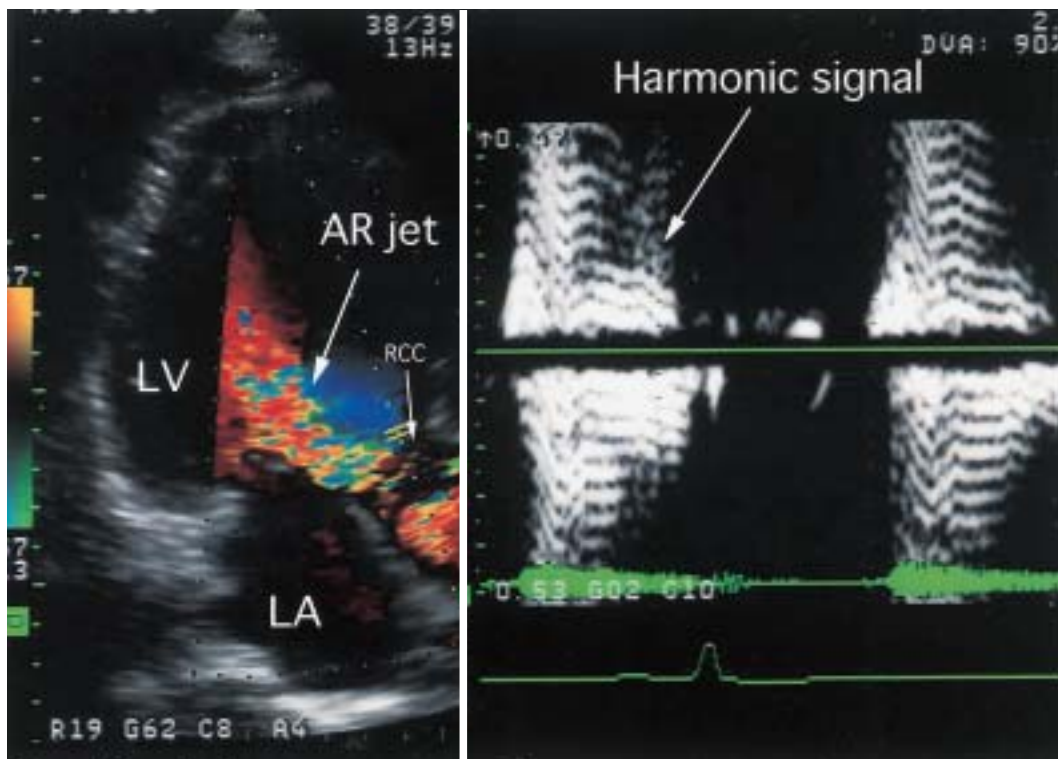
Phonocardiography showed irregular waveform changes of the diastolic murmur with each cardiac cycle under normal sinus rhythm, and even in the expiration or inspiration phases. The changing pattern was not affected by deep breathing or postural change. Transthoracic echocardiography demonstrated prolapse of the right coronary cusp of the aortic valve, and color flow imaging showed a localized and distinct regurgitant jet from the right coronary cusp toward the anterior mitral leaflet. Pulsed-wave Doppler echocardiography detected the harmonic signal only at the right coronary cusp ( **Fig. 2** ). Aortography revealed Sellers grade aortic regurgitation. Aortic valve replacement was performed with a mechanical prosthetic valve. Intraoperatively, prolapse of the redundant right coronary cusp was seen. However, no commissural ruptures or fenestrations were observed in the cusps. Histological examination of the excised specimen showed mild and extensive myxoid change ( **Fig. 3** )

Although the intensity and pitch of diastolic murmur in aortic regurgitation differs among individuals, it is rare that the form of the murmur changes irregularly under normal sinus rhythm and the same posture<sup>1,2</sup>). We previously reported a case of aortic regurgitation with an irregular musical murmur caused by the presence of vibratory thinned cusps and the Venturi effect induced by a localized regurgitant jet<sup>3</sup>). Presumably the same mechanism caused the wave form change of the musical murmur in the present case.

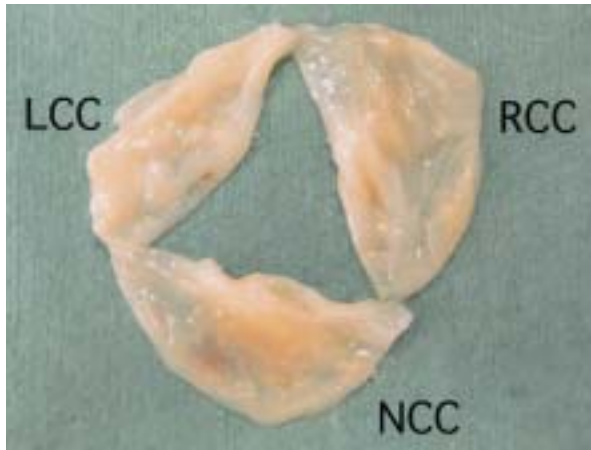
In view of our clinical experience, the presence of thinned, redundant and prolapsed aortic cusps influenced by a localized regurgitant blood flow may be very important in the generation of this type of musical murmur.

**Diagnosis:** Aortic valve prolapse due to myxomatous degeneration

**Key Words:** Aortic regurgitation ; Phonocardiography



**Fig. 2**



**Fig. 3**

**Fig. 1 Phonocardiogram recorded during holding breath in the expiratory phase**

Irregular change in the intensity and pitch of a diastolic murmur was recorded.

ECG = echocardiogram; Exp. = expiratory phase.

**Fig. 2 Color (left) and pulsed-wave (right) Doppler echocardiograms**

Color flow imaging showed a localized and distinct regurgitant jet from the right coronary cusp toward

**References**

- 1) Ueda H, Kaito G, Sakamoto T: Clinical Phonocardiography. Nanzando, Tokyo, 1963; pp 451 - 480 (in Japanese)
- 2) Dressler W, Rubin R: Complex shape and variability of the diastolic murmur of aortic regurgitation. Am J Cardiol 1966; **18**: 616 - 621
- 3) Miyahara K, Amitani S, Sohara H, Kurose M, Iwamura H, Toyohira H, Taira A: Chaotic musical murmur in aortic regurgitation. Jpn Circ J 1996; **60**: 993 - 997

the anterior mitral leaflet. The harmonic signal was observed only at the right coronary cusp.

LV = left ventricle; LA = left atrium; AR = aortic regurgitation; RCC = right coronary cusp.

**Fig. 3 Macroscopic findings of the excised valve**

There were no commissural ruptures or fenestrations in the cusps.

LCC = left coronary cusp; NCC = non-coronary cusp. Other abbreviation as in Fig. 2.