

New Noninvasive Diagnosis of Myocardial Ischemia of the Left Circumflex Coronary Artery Using Coronary Flow Reserve Measurement by Transthoracic Doppler Echocardiography: Comparison With Thallium-201 Single Photon Emission Computed Tomography

Kohei FUJIMOTO, MD
Hiroyuki WATANABE, MD, FJCC
Takeshi HOZUMI, MD, FJCC
Ryo OTSUKA, MD
Kumiko HIRATA, MD
Hiroyuki YAMAGISHI, MD
Minoru YOSHIYAMA, MD,

FJCC

Abstract

Objectives. The usefulness of coronary flow reserve measurement in the left circumflex coronary artery by transthoracic Doppler echocardiography to detect myocardial ischemia was compared with exercise thallium-201 single photon emission computed tomography (SPECT).

Methods. Transthoracic Doppler echocardiography was performed in 110 patients with suspected coronary artery disease. Color Doppler signals of the left circumflex coronary artery flow in the apical four-chamber view were identified, and the velocities at rest and during hyperemia recorded for calculation of coronary flow reserve by the pulsed Doppler method. All patients underwent SPECT within 1 week of the transthoracic Doppler echocardiographic study.

Results. Coronary flow reserve in the left circumflex coronary artery was measured in 79 (72%) of 110 patients. SPECT revealed reversible perfusion defect in the left circumflex coronary artery territories in 12 of 69 patients excluding those with multivessel disease. Coronary flow reserve < 2.0 had a sensitivity of 92% and specificity of 96% for reversible perfusion defect detected by SPECT.

Conclusions. Noninvasive coronary flow reserve measurement in the left circumflex coronary artery by transthoracic Doppler echocardiography can estimate myocardial ischemia in the left ventricular lateral regions.

J Cardiol 2004 Mar; 43(3): 109-116

Key Words

■ Doppler ultrasound (coronary flow velocity, coronary flow reserve)

■ Blood flow

■ Coronary artery disease ■ Echocardiography, transthoracic

大阪市立大学大学院医学研究科 循環器病態内科学: 〒545-8585 大阪市阿倍野区旭町1-4-3

Department of Internal Medicine and Cardiology, Osaka City University Graduate School of Medicine, Osaka

Address for correspondence: WATANABE H, MD, FJCC, Department of Internal Medicine and Cardiology, Osaka City University Graduate School of Medicine, Asahimachi 1-4-3, Abeno-ku, Osaka 545-8585

Manuscript received August 28, 2003; revised October 27, 2003; accepted October 28, 2003

INTRODUCTION

Noninvasive diagnosis of ischemic heart disease at relatively low cost has recently become an important clinical issue. Stress echocardiography is widely used, but the limitation of this method is the low sensitivity for the individual coronary arteries; the sensitivity for detecting coronary artery disease in the left circumflex coronary artery (LCX) is low compared with the other coronary arteries¹⁻³. More sensitive information on coronary flow abnormality could be important for the noninvasive diagnosis of coronary artery disease.

Coronary flow reserve (CFR) is an important physiological index which reflects the severity of coronary narrowing. CFR measurement previously required invasive^{4,5}, semi-invasive⁶ or radioactive exposure methods^{7,8}, subsequent clinical experience and improvements in transthoracic Doppler echocardiography (TTDE) have allowed noninvasive examination as the choice for ischemic heart disease^{9,10}. However, the potential for identifying ischemia of the LCX has never been investigated.

The present study evaluated the usefulness of CFR measurement in the LCX by TTDE compared with exercise thallium-201 (²⁰¹Tl) single photon emission computed tomography (SPECT).

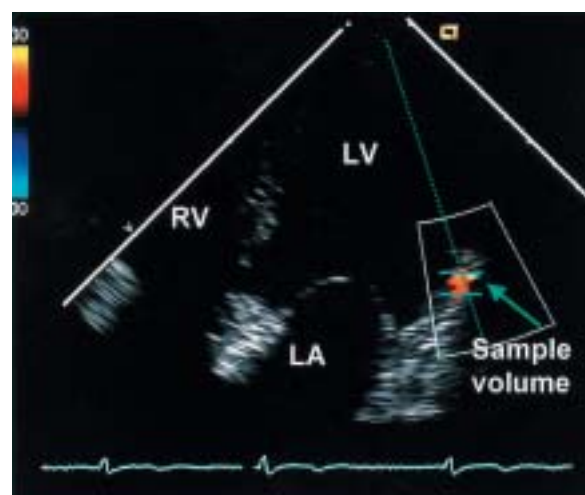
SUBJECTS AND METHODS

Study population

This study included 110 consecutive patients (92 men, mean age 62 ± 10 years) with suspected ischemic heart disease who were scheduled for coronary angiography. Exclusion criteria were left ventricular wall motion abnormality, left ventricular hypertrophy, cardiomyopathy, previous cardiac surgery, atrial fibrillation, and significant valvular heart disease. All patients continued administration of anti-ischemic medication (nitrates, beta blockers, calcium antagonists) and antiplatelet agents (aspirin 81 mg) on the day of the echocardiographic study. We obtained informed consent from all participants to the study protocol, which was approved by the Committee for the Protection of Human Subjects in Research at Osaka City University Graduate School of Medicine.

Coronary flow reserve measurement by transthoracic Doppler echocardiography

We used a commercially available high-resolution ultrasound system (ACUSON Sequoia 512,



Apical four-chamber view

Fig. 1 Color Doppler imaging of the left circumflex coronary artery in the apical four-chamber view. RV = right ventricle; LV = left ventricle; LA = left atrium.

Siemens Medical Solutions USA, Inc.) using a 3V2C probe (2 - 3 MHz, Doppler frequency 2.0 MHz). For color flow mapping, the velocity range was set at ± 12 to ± 30 cm/sec. The color gain was adjusted to provide optimal images. Doppler flow signals of the LCX were identified as linear color signals persisting during diastole on the base to mid portion of the left ventricular lateral region in the apical four-chamber view as far as possible (Fig. 1). The mid to distal LCX in the left ventricular lateral region is most likely to be detected in the apical four-chamber view. Doppler spectral tracings of the flow velocities were recorded by fast Fourier transformation analysis with a sample volume positioned on the most clearly visualized color signals. Holding the transducer in the same position as far as possible, the flow velocities were recorded at rest and during hyperemia induced by intravenous infusion of adenosine triphosphate (0.14 mg/kg/min) for 2 min. Heart rate, blood pressure and electrocardiographic monitoring were continuous throughout the test. All velocity recordings were continuously recorded on half-inch S-VHS videotape and stopped frames were also stored digitally on magneto-optical disks (540 MB) for subsequent off-line analysis.

CFR was calculated as the ratio of hyperemic to basal mean diastolic flow velocities which were obtained off-line by contouring the spectral Doppler signals at baseline and at peak hyperemic

conditions using analysis software incorporated in the ultrasound system. Each measurement was averaged over three consecutive cardiac cycles. Each study was analyzed by two experienced operators who were unaware of the patient's data. Normal CFR was defined as ≥ 2.0 on the basis of the results of previous studies which had evaluated flow velocities in the distal left anterior descending artery^{5,11}).

Echocardiographic contrast enhancement

Echocardiographic contrast agent (Levovist, Schering) was administered to obtain spectral Doppler signals in the event of unsuccessful visualization or unclear recording of the flow spectrum. On the basis of a previous study¹²), the echocardiographic contrast agent was administered intravenously at 300 mg/ml by intravenous infusion of 7 ml at 1 ml/min, using an infusion pump. The infusion rate was adjusted in the range of 2.0 to 0.5 ml/min according to the quality and entity of the Doppler signal enhancement achieved.

Exercise thallium-201 SPECT

SPECT was performed within 1 week of the CFR studies. All patients performed symptom-limited exercise on a bicycle ergometer in the sitting position. Nitrates, beta blockers and calcium channel blockers were withheld on the morning of the test. Twelve-lead electrocardiography and blood pressure measurements were obtained at baseline and every minute during exercise. The initial workload was 50 W, which was increased by 25 W every 2 min until the end point was reached, marked by excessive fatigue, dyspnea, dizziness, angina, hypotension, diagnostic ST segment depression (> 1.5 mm horizontal or downsloping or > 2.0 mm upsloping) or significant arrhythmia. At peak exercise, a dose of 111 MBq of ²⁰¹Tl was injected intravenously. The initial images were obtained immediately after the termination of exercise, and delayed images were obtained 4 hr later.

SPECT was performed using a single-head gamma scintillation camera equipped with a low energy, all-purpose, parallel-hole collimator. Thirty-two equidistant projections were acquired over 180° from the right anterior oblique to left posterior oblique view at 25 sec/projection.

The lateral including posterior segments on the SPECT images were considered to be the LCX territories. The SPECT images were analyzed individ-

ually by two experienced nuclear physicians who had no knowledge of the angiographic or echocardiographic data. Disagreements in interpretation were resolved by consensus of the two physicians. The patients were considered to have myocardial ischemia if ²⁰¹Tl SPECT revealed perfusion defects with redistribution on delayed imaging.

Coronary angiography

Coronary angiography was performed in all patients by using standard techniques within 1 week of the CFR studies. Angiographic data were subsequently analyzed by an experienced investigator who had no knowledge of the patient's data. The severity of coronary stenosis was visually determined and expressed as the percentage lumen diameter stenosis. Stenosis was considered significant if there was $> 75\%$ diameter stenosis in at least one projection. Electrical calipers were used when necessary.

Doppler guide wire study

In a subgroup of 14 randomly selected patients, coronary flow velocity measurements were obtained within 10 min after the administration of intracoronary nitroglycerin after routine diagnostic angiography simultaneously with Doppler recording of the coronary flow velocity in the LCX territories by TTDE. All patients received an additional 2,000 IU bolus of intravenous heparin. A 0.014-inch (0.36 mm) Doppler-tipped angioplasty guide wire (FlowWire, Cardiometrics Inc.) was inserted into the distal LCX. After satisfactory baseline flow velocity signals were obtained, hyperemic flow velocity data were continuously acquired during continuous administration of adenosine triphosphate (0.14 mg/kg/min) intravenously. The mean CFR was calculated as the ratio of hyperemic to basal mean coronary flow velocities. All studies were recorded on 0.5-inch S-VHS videotape for subsequent off-line analysis.

Statistical analysis

On the basis of the ²⁰¹Tl SPECT data for the LCX territories, the patients were classified into Group A (abnormal perfusion) and Group B (normal perfusion). Parametric data were presented as the mean value \pm SD. Categorical variables were compared using the Fisher exact test. Echocardiographic and hemodynamic variables during adenosine infusion in Groups A and B were

evaluated by two-way repeated measures analysis of variance (ANOVA); testing for group effect, adenosine effect, and interaction. The Fisher protected least-significant difference test was used for post-hoc testing. Mean CFR values for Groups A and B were compared by the unpaired *t*-test. $p < 0.05$ was considered significant. The sensitivity, specificity, positive predictive value and negative predictive value of CFR were calculated in the conventional way, as a predictor of abnormal perfusion on the ^{201}Tl SPECT image. Interobserver and intraobserver variabilities were assessed for CFR measurements in eight randomly selected patients. Interobserver variability was calculated as the SD of the differences between the measurements of two independent observers unaware of the patient's data and expressed as a percentage of the average value. Intraobserver variability was calculated as the SD of the differences between the first and second determinations, 15 min apart, for a single observer and expressed as a percentage of the average value. Linear regression analysis was used to compare TTDE with the Doppler guide wire method for the assessment of CFR, and an analysis of the differences of the measurements between TTDE and Doppler guide wire was performed according to the technique of Bland and Altman.

RESULTS

Adequate spectral Doppler recordings of the LCX were obtained in 79 of 110 patients (72%). To test the accuracy of CFR measurement by TTDE compared with the results of SPECT in patients with single-vessel disease, we excluded 10 of the 79 patients with multivessel disease according to angiographic findings, because the sensitivity of SPECT for diagnosis of multivessel disease is low^{13,14}). Therefore, the remaining 69 patients comprised the study group. No significant difference in age or sex were found between Groups A and B (Table 1). The results of the two-way repeated measures ANOVA for group and adenosine effect are summarized in Table 2.

Thallium-201 SPECT

All patients in this study performed exercise tests until the end points were reached. Twelve of the 69 patients qualitatively exhibited abnormal perfusion in the LCX territories on ^{201}Tl SPECT and were classified as Group A. The remainder of the patients ($n = 57$) had no abnormal perfusion in the

Table 1 Comparison of clinical data in Groups A and B

	Group A ($n = 12$)	Group B ($n = 57$)	<i>p</i> value
Age (year)	64 ± 8	60 ± 10	NS
Sex (M/F)	10/2	53/4	NS
SBP (mmHg)			
Baseline	129 ± 15	126 ± 13	NS
Hyperemia	126 ± 16	120 ± 15	NS
DBP (mmHg)			
Baseline	73 ± 8	73 ± 10	NS
Hyperemia	70 ± 8	70 ± 11	NS
HR (beats/min)			
Baseline	70 ± 14	68 ± 12	NS
Hyperemia	73 ± 13	72 ± 12	NS

Continuous values are mean ± SD.

Group A: with abnormal perfusion. Group B: with normal perfusion.

M = male; F = female; SBP = systolic blood pressure; DBP = diastolic blood pressure; HR = heart rate.

Table 2 Results of two-way repeated measures analysis

	Group (<i>p</i> value)	Adenosine (<i>p</i> value)	Interaction (<i>p</i> value)
SBP	0.53	< 0.01	0.34
DBP	0.19	< 0.01	0.99
HR	0.57	< 0.01	0.67
MDV	< 0.01	< 0.01	< 0.01

MDV = mean diastolic velocity. Other abbreviations as in Table 1.

LCX territories and were classified as Group B; normal perfusion ($n = 27$) in all regions or abnormal perfusion in the other regions ($n = 30$). The peak heart rate and rate-pressure product were similar in Groups A and B for all exercise tests.

Hemodynamic data

No patient developed serious adverse effects, such as angina, atrioventricular block, nausea, flushing or palpitations, during the administration of adenosine triphosphate. Two-way repeated measures ANOVA showed no significant differences or interaction in terms of heart rate, systolic blood pressure and diastolic blood pressure between Groups A and B during administration of adenosine (Tables 1 and 2).

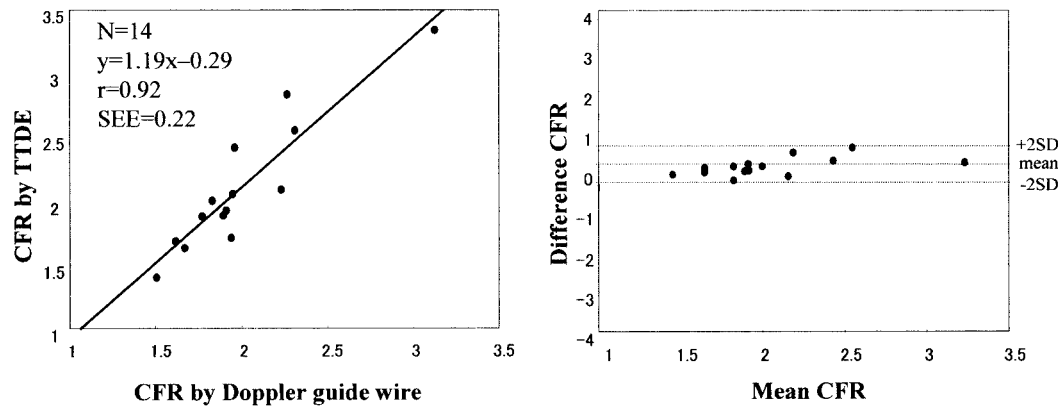


Fig. 2 Regression (left) and difference (right) plots comparing coronary flow reserve measured by the transthoracic Doppler echocardiography and Doppler guide wire methods
CFR = coronary flow reserve; TTDE = transthoracic Doppler echocardiography.

Coronary angiography

Coronary angiography demonstrated significant coronary stenosis in the LCX in 11 patients of Group A and in four patients of Group B. There were discrepancies between coronary angiography findings, SPECT findings and CFR measurement by TTDE in one patient of Group A and in four patients of Group B. In the patient of Group A with $CFR < 2.0$, coronary angiography revealed no significant stenosis in the LCX, in which the left ventricular lateral segments were perfused by the right coronary artery with significant stenosis. In Group B, two patients had $CFR < 2$ that reflected coronary narrowing in a small branch of the postero-lateral coronary artery, and two patients had $CFR > 2$ even with significant stenosis on coronary angiography.

Comparison with Doppler guide wire study

CFR obtained from TTDE was highly correlated with that from Doppler guide wire measurements ($r = 0.92$, $y = 1.19x - 0.29$, $SEE = 0.22$; **Fig. 2**). The mean difference between these methods was 0.10 ± 0.22 for CFR measurements.

Coronary flow reserve measured by transthoracic Doppler echocardiography versus thallium-201 SPECT

An increase in coronary flow velocity was observed in all patients within 1 min of the start of adenosine infusion. The contour of flow velocity remained stable throughout the infusion period and returned to the baseline rapidly after cessation of adenosine infusion. There was no significant differ-

Table 3 Coronary flow velocity and reserve in Groups A and B

	Group A	Group B	p value
MDV (cm/sec)			
Baseline	20.2 ± 3.9	20.0 ± 4.9	NS
Hyperemia	32.6 ± 9.1	56.0 ± 13.9	< 0.01
CFR	1.6 ± 0.5	2.9 ± 0.6	< 0.01

Values are mean \pm SD.

Explanation of the groups and abbreviations as in Tables 1, 2, Fig. 2.

ence between Groups A and B in coronary flow velocity measurements at baseline (**Table 3**). However, mean diastolic flow velocities increased significantly during hyperemia in Group B, as compared with those in Group A ($p < 0.01$; **Fig. 3**). Two-way ANOVA showed a significant group effect and interaction in mean diastolic flow velocities during hyperemia (**Table 2**). Thus, mean CFR measured by TTDE demonstrated significant differences between Groups A and B (mean CFR 1.6 ± 0.5 vs 2.9 ± 0.6 , respectively; $p < 0.01$).

Only one patient in Group A had mean $CFR \geq 2.0$, whereas two patients in Group B had mean $CFR < 2.0$ (**Fig. 4**). Mean $CFR < 2.0$ predicted a reversible perfusion defect in the LCX territories, with sensitivity of 92%, specificity of 96%, positive predictive value of 85% and negative predictive value of 98%.

Observer variability

Interobserver and intraobserver variabilities for measurement of Doppler velocity recording were

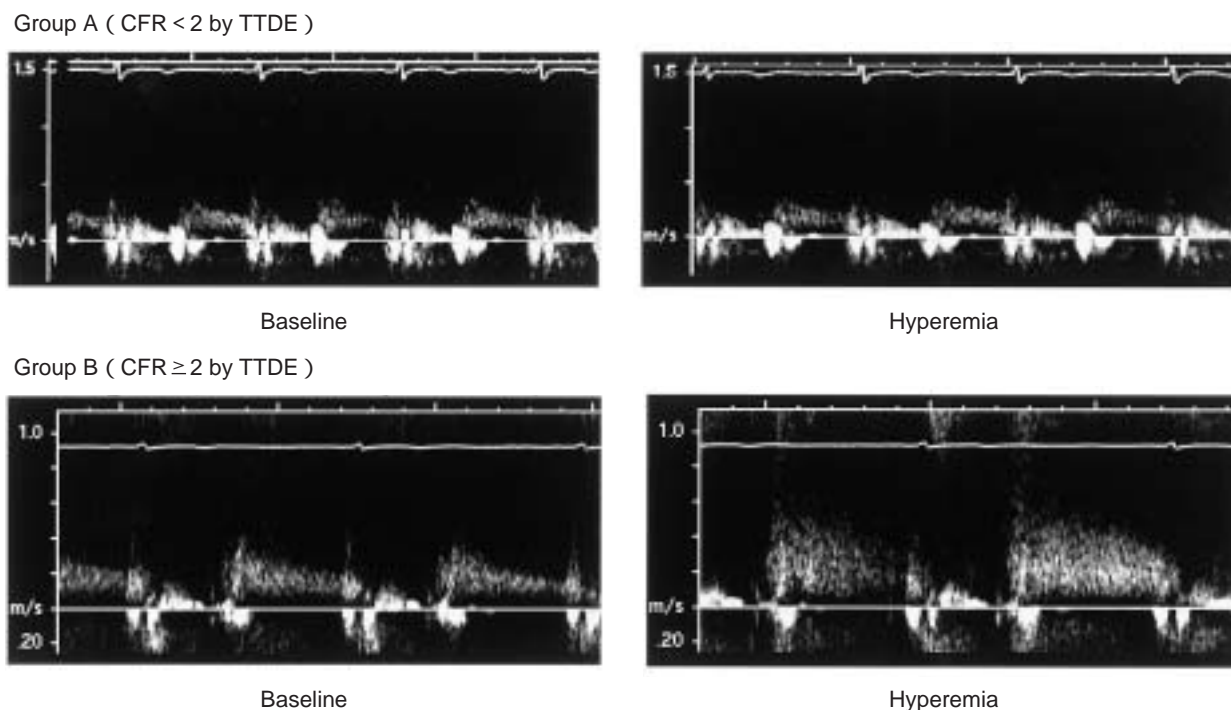


Fig. 3 Spectral Doppler signals at the baseline (*left column*) and during hyperemia (*right column*) in a patient of Group A with abnormal myocardial perfusion in the left circumflex artery territories (*upper row*) and in a patient of Group B with normal perfusion in the left circumflex artery territories (*lower row*)

Explanation of the groups and abbreviations as in Table 1, Fig. 2.

	CFR < 2.0	CFR ≥ 2.0	
Group A	11	1	12
Group B	2	55	57
	13	56	69

Fig. 4 Plot showing good correlation between coronary flow reserve measurements and the results of thallium-201 single photon emission computed tomography

There was overall agreement in 66 (96%) of 69 patients. Explanation of the groups and abbreviation as in Table 1, Fig. 2.

5.3% and 4.4%, respectively.

DISCUSSION

The accuracy of CFR measurement on the LCX by TTDE was compared to the results of ^{201}Tl SPECT. CFR < 2.0 was found to be associated with perfusion abnormality in the LCX territories by ^{201}Tl SPECT.

Coronary flow reserve measurement in the left circumflex coronary artery

CFR is an important diagnostic parameter for functional coronary artery stenosis^{5,11,15-17}). Previously, the measurement of this parameter needed the invasive Doppler guide wire or Doppler catheter^{4,5}), semi-invasive transesophageal echocardiography⁶), or positron emission tomography^{7,8}). However, CFR measurement has now become non-invasive, because recent technological advances in TTDE can obtain this parameter noninvasively^{9,18}). In the left anterior descending artery territories, CFR measurement has been proven to provide data equivalent to the results of ^{201}Tl SPECT¹⁰). However, the potential in detecting coronary artery disease in the LCX remained unclear. Thus, we investigated whether this technique is suitable for diagnosis of ischemia in the LCX. We found CFR measurement by TTDE in the LCX also provides data equivalent to the result of ^{201}Tl SPECT.

The success in detecting CFR in the LCX depends on the following factors. First, use of a low frequency transducer, not a high frequency trans-

ducer, in contrast to left anterior descending artery flow measurements. The color Doppler signals in the LCX are located in the far field in the apical four-chamber view, so it is often difficult to obtain good echocardiographic images using a high frequency transducer. Second, echo contrast agent was administered intravenously to enhance Doppler signals in patients with low signal to noise ratio. Without contrast agent, the feasibility of CFR measurement in the LCX will be reduced.

Utility of coronary flow reserve measurement by transthoracic Doppler echocardiography

Stress echocardiography evaluates myocardial ischemia by detecting wall motion abnormalities, and is used most frequently in the clinical setting as a noninvasive, simple and relatively low cost test for angina pectoris. Although this test achieved sufficient accuracy to detect myocardial ischemia in patients with multivessel disease, the accuracy for ischemia in each region is not sufficiently high; and the sensitivity for ischemia in the LCX territories is the lowest compared with other regions¹⁻³). Use of CFR measurement in the LCX by TTDE with contrast agent could overcome the limitation of stress echocardiography.

Limitations

First, the number of patients included in this study is small. Actually, there were only 12 patients with abnormal perfusion in the LCX territories. A larger number of patients should be included in future studies. Second, compared with the success rate of CFR measurement by TTDE in the left anterior descending artery, the feasibility of this technique was not sufficiently high even with contrast agent. In addition to the distance between signals and the echo probe, artifacts from the lung could affect coronary flow recordings on the LCX. More technical progress in TTDE is needed. Finally, two patients of Group B showed normal perfusion in the LCX territory on ²⁰¹Tl SPECT, although coronary angiography demonstrated significant stenosis in the LCX. This may be one of the limitations of this study. Even with these limitations, the sensitivity and specificity in detection of myocardial ischemia in the left ventricular lateral regions is sufficiently high for use in daily clinical practice.

CONCLUSIONS

Noninvasive CFR measurement in the LCX by TTDE can estimate myocardial ischemia in the left ventricular lateral regions.

要 約

経胸壁ドプラ心エコー図を用いた冠血流予備能による左回旋枝領域の心筋虚血の新しい非侵襲的診断法: タリウム-201 運動負荷心筋シンチグラフィーとの比較

藤本 浩平 渡辺 弘之 穂積 健之 大塚 亮
平田久美子 山岸 広幸 葭山 稔 吉川 純一

目的: 心筋虚血検出における経胸壁ドプラ心エコー図による左回旋枝での冠血流予備能の有用性をタリウム-201 運動負荷シンチグラフィーと比較することにより検討する。

方法: 連続した110例の冠動脈疾患を疑われた患者を対象とした。経胸壁心エコー図により心尖部四腔像にて左回旋枝血流のカラードプラ信号を検出し、パルスドプラ法により安静時と反応性充血時の冠血流速度波形を記録し、冠血流予備能を計測した。すべての患者で心筋シンチグラフィーが行われた。

結果: 110例のうち79例(72%)で左回旋枝での冠血流予備能が測定可能であった。心筋シンチグラフィーでは、多枝病変患者を除いた69例中12例で、左回旋枝領域に可逆的な血流欠損が示された。2.0未満の冠血流予備能の心筋シンチグラフィーによる可逆的な血流欠損に対する感度と特異度は、それぞれ92%, 96%であった。

結論: 経胸壁心エコー図による冠血流予備能を左回旋枝に適用すれば左室側壁の虚血が推定しうる。

J Cardiol 2004 Mar; 43(3): 109 - 116

References

- 1) Takeuchi M, Araki M, Nakashima Y, Kuroiwa A: Comparison of dobutamine stress echocardiography and stress thallium-201 single-photon emission computed tomography for detecting coronary artery disease. *J Am Soc Echocardiogr* 1993; **6**: 593 - 602
- 2) Senior R, Sridhara BS, Anagnostou E, Handler C, Raftery EB, Lahiri A: Synergistic value of simultaneous stress dobutamine sestamibi single-photon-emission computerized tomography and echocardiography in the detection of coronary artery disease. *Am Heart J* 1994; **128**: 713 - 718
- 3) Ho FM, Huang PJ, Liao CS, Lee FK, Chieng PU, Su CT, Lee YT: Dobutamine stress echocardiography compared with dipyridamole thallium-201 single-photon emission computed tomography in detecting coronary artery disease. *Eur Heart J* 1995; **16**: 570 - 575
- 4) Yoshida K, Akasaka T, Yoshikawa J: Assessment of coronary stenosis severity by a Doppler guidewire. *Jpn Circ J* 1994; **58** (Suppl 4): 1192 - 1196 (in Japanese)
- 5) Miller DD, Donohue TJ, Younis LT, Bach RG, Aguirre FV, Wittry MD, Goodgold HM, Chaitman BR, Kern MJ: Correlation of pharmacological ^{99m}Tc-sestamibi myocardial perfusion imaging with poststenotic coronary flow reserve in patients with angiographically intermediate coronary artery stenoses. *Circulation* 1994; **89**: 2150 - 2160
- 6) Redberg RF, Sobol Y, Chou TM, Malloy M, Kumar S, Botvinick E, Kane J: Adenosine-induced coronary vasodilation during transesophageal Doppler echocardiography: Rapid and safe measurement of coronary flow reserve ratio can predict significant left anterior descending coronary stenosis. *Circulation* 1995; **92**: 190 - 196
- 7) Gould KL, Goldstein RA, Mullani NA, Kirkeeide RL, Wong WH, Tewson TJ, Berridge MS, Bolomey LA, Hartz RK, Smalling RW, Fuentes F, Nishikawa A: Noninvasive assessment of coronary stenoses by myocardial perfusion imaging during pharmacologic coronary vasodilation: Clinical feasibility of positron cardiac imaging without a cyclotron using generator-produced rubidium-82. *J Am Coll Cardiol* 1986; **7**: 775 - 789
- 8) Uren NG, Melin JA, De Bruyne B, Wijns W, Baudhuin T, Camici PG: Relation between myocardial blood flow and the severity of coronary-artery stenosis. *N Engl J Med* 1994; **330**: 1782 - 1788
- 9) Hozumi T, Yoshida K, Ogata Y, Akasaka T, Asami Y, Takagi T, Morioka S: Noninvasive assessment of significant left anterior descending coronary artery stenosis by coronary flow velocity reserve with transthoracic color Doppler echocardiography. *Circulation* 1998; **97**: 1557 - 1562
- 10) Daimon M, Watanabe H, Yamagishi H, Muro T, Akioka K, Hirata K, Takeuchi K, Yoshikawa J: Physiologic assessment of coronary artery stenosis by coronary flow reserve measurements with transthoracic Doppler echocardiography: Comparison with exercise thallium-201 single photon emission computed tomography. *J Am Coll Cardiol* 2001; **37**: 1310 - 1315
- 11) Voudris V, Athanassopoulos G, Vassilikos V, Avramides D, Manginas A, Michalis A, Cokkinos DV: Usefulness of flow reserve in the left internal mammary artery to determine graft patency to the left anterior descending coronary artery. *Am J Cardiol* 1999; **83**: 1157 - 1163
- 12) Caiati C, Montaldo C, Zedda N, Montisci R, Ruscazio M, Lai G, Cadeddu M, Meloni L, Iliceto S: Validation of a new noninvasive method of contrast-enhanced transthoracic second harmonic echo Doppler for the evaluation of coronary flow reserve: Comparison with intracoronary Doppler flow wire. *J Am Coll Cardiol* 1999; **34**: 1193 - 1200
- 13) Chae SC, Heo J, Iskandrian AS, Wasserleben V, Cave V: Identification of extensive coronary artery disease in women by exercise single-photon emission computed tomographic (SPECT) thallium imaging. *J Am Coll Cardiol* 1993; **21**: 1305 - 1311
- 14) Christian TF, Miller TD, Bailey KR, Gibbons RJ: Noninvasive identification of severe coronary artery disease using exercise tomographic thallium-201 imaging. *Am J Cardiol* 1992; **70**: 14 - 20
- 15) Joye JD, Schulman DS, Lasorda D, Farah T, Donohue BC, Reichek N: Intracoronary Doppler guide wire versus stress single-photon emission computed tomographic thallium-201 imaging in assessment of intermediate coronary stenoses. *J Am Coll Cardiol* 1994; **24**: 940 - 947
- 16) Tron C, Donohue TJ, Bach RG, Aguirre FV, Caracciolo EA, Wolford TL, Miller DD, Kern MJ: Comparison of pressure-derived fractional flow reserve with poststenotic coronary flow velocity reserve for prediction of stress myocardial perfusion imaging results. *Am Heart J* 1995; **130**: 723 - 733
- 17) Deychak YA, Segal J, Reiner JS, Rohrbeck SC, Thompson MA, Lundergan CF, Ross AM, Wasserman AG: Doppler guide wire flow-velocity indexes measured distal to coronary stenoses associated with reversible thallium perfusion defects. *Am Heart J* 1995; **129**: 219 - 227
- 18) Hozumi T, Yoshida K, Akasaka T, Asami Y, Ogata Y, Takagi T, Kaji S, Kawamoto T, Ueda Y, Morioka S: Noninvasive assessment of coronary flow velocity and coronary flow velocity reserve in the left anterior descending coronary artery by Doppler echocardiography: Comparison with invasive technique. *J Am Coll Cardiol* 1998; **32**: 1251 - 1259