

Inhibition of Rho-Kinase by Fasudil Prevents Anginal Attacks Associated With Spastic Angina: A Case Report

Junko HIROKI, MD
Yoshihiro FUKUMOTO, MD
Hiroaki SHIMOKAWA, MD, FJCC
Yoshitaka HIROOKA, MD
Akira TAKESHITA, MD, FJCC

Abstract

An 86-year-old woman was admitted with unstable angina pectoris. Plain old balloon angioplasty (POBA) was performed for 90% stenosis at segment 7 of the left coronary artery with concomitant treatment with nitrate, calcium antagonists, and nicorandil. Five days after POBA, she again suffered chest pain at rest with ST depression by electrocardiography, despite increased doses of calcium-antagonist and nicorandil. Coronary arteriography showed no evidence of restenosis (50%) at the POBA site. The involvement of coronary artery spasm was considered and intravenous treatment with a Rho-kinase inhibitor, fasudil, was started, which resulted in disappearance of the anginal attacks. She refused to continue the fasudil treatment on day 5, which resulted in reappearance of anginal attacks. Third coronary angiography showed a 90% restenosis at POBA site and percutaneous coronary intervention was again performed. This case suggests that a Rho-kinase inhibitor is potentially effective to prevent anginal attacks in spastic angina.

J Cardiol 2004 Oct; 44(4): 161 - 164

Key Words

■ Unstable angina (spastic)

■ Vasodilator agents (Rho-kinase inhibitor)

INTRODUCTION

The rupture of vulnerable plaques in the coronary arteries mainly triggers acute coronary syndromes, such as unstable angina and acute myocardial infarction¹). Coronary artery spasm is also important in the occurrence of cardiovascular events including acute coronary syndromes²). We recently demonstrated that Rho-kinase is a novel therapeutic target for the treatment of cardiovascular diseases such as coronary vasospasm³). The Rho-kinase inhibitor, fasudil, suppresses coronary artery spasm in patients with vasospastic angina⁴), but the potential for the treatment of acute coronary syndromes remains to be examined. Here we report a patient with unstable angina pectoris in whom

fasudil was effective for controlling anginal attacks.

CASE REPORT

An 86-year-old woman with unstable angina pectoris was admitted to our hospital, complaining of worsening chest pain on mild exertion and diminishing after 10 minutes' rest. She had hypertension and had taken diltiazem hydrochloride (90 mg/day) for 20 years. Her height was 150 cm and weight was 50 kg. Her blood pressure was 150/90 mmHg. Physical examination found ejection systolic murmur (Levine /) at the fourth right sternal border and loud bruit in the abdomen. Chest radiography showed mild cardiomegaly (cardiothoracic ratio 56%). Electrocardiography indicated normal sinus rhythm and left axis deviation without

九州大学大学院医学研究院 循環器内科: 〒812-8582 福岡市東区馬出3-1-1

Department of Cardiovascular Medicine, Kyushu University Graduate School of Medical Sciences, Fukuoka

Address for correspondence: FUKUMOTO Y, MD, Department of Cardiovascular Medicine, Kyushu University Graduate School of Medical Sciences, Maidashi 3-1-1, Higashi-ku, Fukuoka 812-8582

Manuscript received March 1, 2004; revised April 26, 2004; accepted May 17, 2004

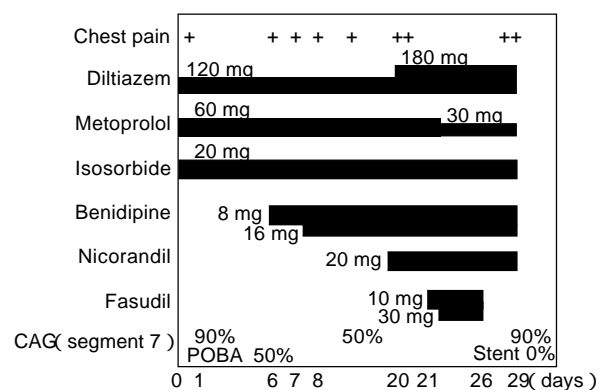


Fig. 1 In-hospital course of a patient with unstable angina, showing chest symptoms, antianginal medical treatment, and coronary intervention
CAG = coronary angiography; POBA = plain old balloon angioplasty.

abnormal ST-T changes. Mild exercise test induced an ischemic ST-segment depression with a negative U wave in leads $V_3 - V_5$. Echocardiography revealed no left ventricular wall motion abnormality, mild aortic regurgitation, and minimal mitral regurgitation. During the first week after admission, she repeatedly suffered from chest pain either on exertion or at rest, which worsened day by day.

Antianginal treatment was started with isosorbide dinitrate (20 mg/day), diltiazem hydrochloride (120 mg/day), and metoprolol (60 mg/day ; **Fig. 1**). Coronary angiography showed a 90% stenosis at segment 7 of the left coronary artery (**Fig. 2 - A**). Plain old balloon angioplasty (POBA) of the stenotic segment was performed which reduced the stenosis to 25% (**Fig. 2 - B**). Five days after the procedure,

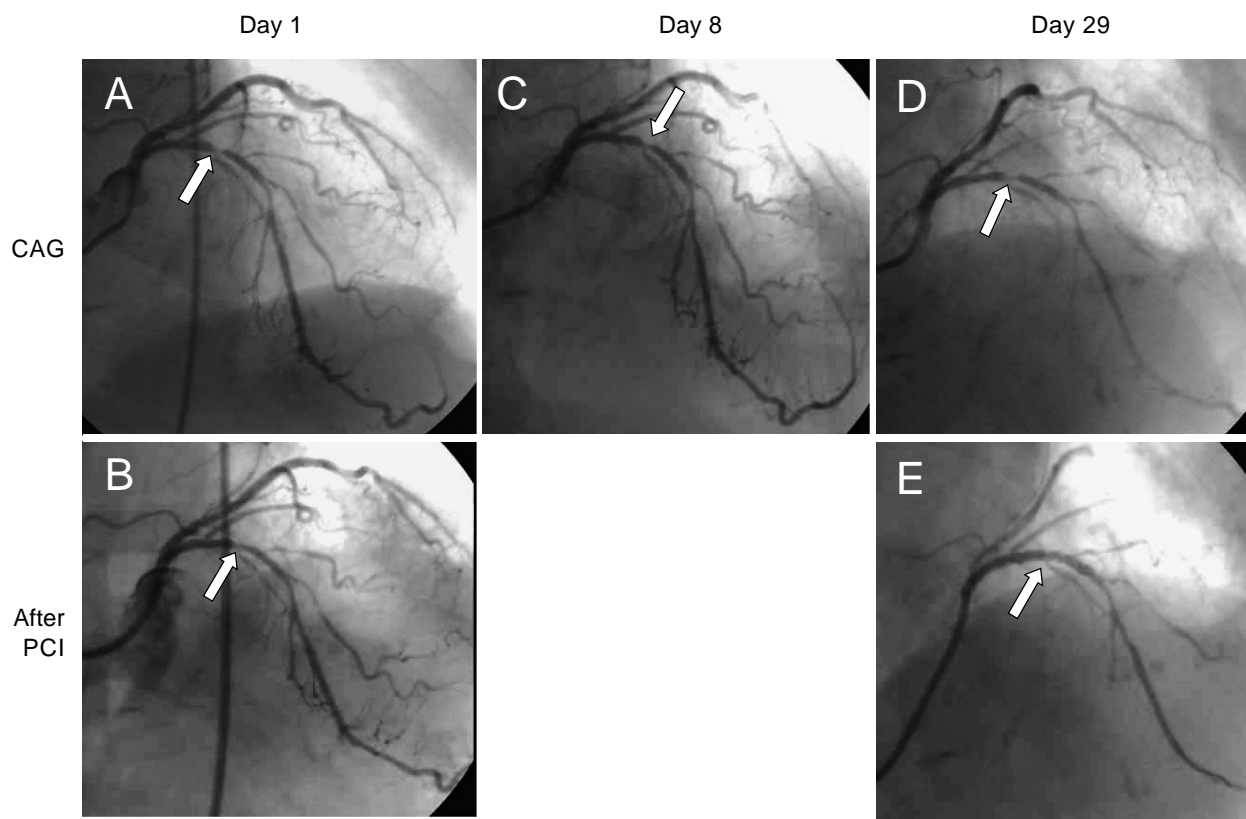


Fig. 2 Coronary angiograms of a patient with unstable angina

- A: Left CAG on admission showing the culprit lesion in segment 7 (arrow)
 B: CAG after plain old balloon angioplasty showing a 25% stenosis in segment 7 (arrow)
 C: Second left CAG showing a 50% restenosis in segment 7 (arrow)
 D: Third left CAG showing a 90% restenosis in segment 7 (arrow)
 E: CAG after stenting to segment 7 showing resolution of the stenosis (arrow) after stenting.
 PCI = percutaneous coronary intervention. Other abbreviation as in Fig. 1.

ture, she complained of chest pain at rest with the same ST-segment depression as before. Benidipine hydrochloride was added (8 mg/day) and the dose was increased (16 mg/day) the next day (Fig. 1). Chest symptoms occurred, but repeat coronary angiography showed no significant stenosis at the POBA site (50% restenosis; Fig. 2 - C). We did not choose re-POBA at this time, because we considered that coronary artery spasm was the major reason for the anginal attacks at rest. Even after increasing the dose of diltiazem hydrochloride to 180 mg, decreasing the dose of metoprolol to 30 mg, and adding 20 mg of nicorandil, she continued to complain of chest pain at rest.

Intravenous treatment with the Rho-kinase inhibitor fasudil (30 mg, three times every 8 hr) was then started. During the treatment with fasudil, no anginal attacks were noted (Fig. 1). However, the fasudil treatment was discontinued on day 5, because she did not like continuous intravenous administration. Three days later, she again had chest pain. Third coronary angiography showed a 90% restenotic lesion at the POBA site (Fig. 2 - D). Coronary stenting was performed at the lesion (Fig. 2 - E). After this procedure, no anginal attacks were noted.

DISCUSSION

The administration of the Rho-kinase inhibitor

fasudil was effective in controlling anginal attacks in the present patient with spastic angina, although we have no evidence that fasudil directly relieved coronary vasospasm in this patient. Rho-kinase is substantially involved in the molecular mechanisms of coronary artery spasm and fasudil suppresses the spasm in both humans and animals³⁻⁶). Rho-kinase inhibits myosin phosphatase activity by phosphorylating the myosin-binding subunit of the enzyme and thus augments vascular smooth muscle contraction at a given calcium concentration⁷). Increased calcium sensitization of vascular smooth muscle cells mediated by the activated Rho-kinase pathway is very important in coronary artery spasm^{2,8}). Fasudil hydrochloride is the only inhibitor of Rho-kinase that can be applied to humans⁹⁻¹²). It has a reasonable inhibitory effect on Rho-kinase, 10 times and 100 times more potent than on protein kinase C and myosin light chain kinase, respectively¹⁰). Importantly, fasudil attenuates only abnormally hyperconstrictive responses of spastic coronary arteries and does not affect those of normal coronary arteries^{4-6,8}). Rho-kinase inhibition suppresses cell migration and may have potential adverse effects on atherosclerotic progression³), although the present patient showed restenosis at the POBA site. The present case suggests that Rho-kinase is a new class of vasodilator for the treatment of spastic angina.

要 約

ファスジルによる Rho キナーゼ阻害が狭心症発作に有効であった 安静時狭心症の 1 例

廣木 潤子 福本 義弘 下川 宏明 廣岡 良隆 竹下 彰

症例は不安定狭心症で入院した 86 歳の女性。冠動脈造影上、左冠動脈前下行枝(分節 7)に 90% 狭窄を認め、同部位に冠動脈拡張術(POBA)を施行した。5 日後に心電図上 ST 低下を伴う安静時胸痛が出現し、Ca拮抗薬およびニコランジル投与下でも安静時胸痛が消失しなかったため、再度冠動脈造影を施行した。POBA 施行部に 50% 再狭窄を認めたが、安静時のみの症状であったため、冠動脈攣縮の関与を考慮し、この時点では冠動脈再拡張術を施行しなかった。Rho キナーゼ阻害薬であるファスジルの点滴投与することにより胸痛は消失したが、5 日間の投与後、患者の要望によりファスジルの中止した。その後、再び胸痛が出現するようになったため、冠動脈造影を施行し、POBA 部に 90% 再狭窄を認めたため、ステント留置術を行い、狭心痛の消失を得た。この症例により Rho キナーゼ阻害が攣縮性狭心症に対し有用であることが示唆された。

J Cardiol 2004 Oct; 44(4): 161 - 164

References

- 1) Libby P: Molecular bases of the acute coronary syndromes. *Circulation* 1995; **91**: 2844 - 2850
- 2) Shimokawa H: Cellular and molecular mechanisms of coronary artery spasm: Lessons from animal models. *Jpn Circ J* 2000; **64**: 1 - 12
- 3) Shimokawa H: Rho-kinase as a novel therapeutic target in treatment of cardiovascular diseases. *J Cardiovasc Pharmacol* 2002; **39**: 319 - 327
- 4) Masumoto A, Mohri M, Shimokawa H, Urakami L, Usui M, Takeshita A: Suppression of coronary artery spasm by the Rho-kinase inhibitor fasudil in patients with vasospastic angina. *Circulation* 2002; **105**: 1545 - 1547
- 5) Masumoto A, Hirooka Y, Shimokawa H, Hironaga K, Setoguchi S, Takeshita A: Possible involvement of Rho-kinase in the pathogenesis of hypertension in humans. *Hypertension* 2001; **38**: 1307 - 1310
- 6) Kandabashi T, Shimokawa H, Mukai Y, Matoba T, Kunihiro I, Morikawa K, Ito M, Takahashi S, Kaibuchi K, Takeshita A: Involvement of rho-kinase in agonists-induced contractions of arteriosclerotic human arteries. *Arterioscler Thromb Vasc Biol* 2002; **22**: 243 - 248
- 7) Somlyo AP, Somlyo AV: Signal transduction by G-proteins, rho-kinase and protein phosphatase to smooth muscle and non-muscle myosin. *J Physiol* 2000; **522**(Pt 2): 177 - 185
- 8) Kandabashi T, Shimokawa H, Miyata K, Kunihiro I, Kawano Y, Fukata Y, Higo T, Egashira K, Takahashi S, Kaibuchi K, Takeshita A: Inhibition of myosin phosphatase by upregulated rho-kinase plays a key role for coronary artery spasm in a porcine model with interleukin-1. *Circulation* 2000; **101**: 1319 - 1323
- 9) Uehata M, Ishizaki T, Satoh H, Ono T, Kawahara T, Morishita T, Tamakawa H, Yamagami K, Inui J, Maekawa M, Narumiya S: Calcium sensitization of smooth muscle mediated by a Rho-associated protein kinase in hypertension. *Nature* 1997; **389**: 990 - 994
- 10) Shimokawa H, Seto M, Katsumata N, Amano M, Kozai T, Yamawaki T, Kuwata K, Kandabashi T, Egashira K, Ikegaki I, Asano T, Kaibuchi K, Takeshita A: Rho-kinase-mediated pathway induces enhanced myosin light chain phosphorylations in a swine model of coronary artery spasm. *Cardiovasc Res* 1999; **43**: 1029 - 1039
- 11) Davies SP, Reddy H, Caivano M, Cohen P: Specificity and mechanism of action of some commonly used protein kinase inhibitors. *Biochem J* 2000; **351**: 95 - 105
- 12) Sward K, Dreja K, Susnjar M, Hellstrand P, Hartshorne DJ, Walsh MP: Inhibition of Rho-associated kinase blocks agonist-induced Ca²⁺ sensitization of myosin phosphorylation and force in guinea-pig ileum. *J Physiol* 2000; **522**(Pt 1): 33 - 49