

Entrapment of a Tined Lead by the Chiari Network With Preserved Atrial Sensing Ability in a Patient With Atrioventricular Block: A Case Report

Takahisa MARUYAMA, MD
Fumio KUROGOUCHI,

Abstract

An 82-year-old woman with 2: 1 atrioventricular block underwent a pacemaker implantation procedure, but a tined lead became entrapped by the Chiari network. All manipulations failed to achieve release of the electrode, by which the atrial electrical potential could be recorded. Tines equipped near the tip of a pacemaker lead are intended to prevent dislodgment, but entrapment of the tined tip by intracardiac structures is probable. Together with another screw-in ventricular lead, this entrapped tined lead could act as a dual chamber pacemaker in VDD mode.

J Cardiol 2004 Dec; 44(6): 251 - 254

Key Words

- Complications (entrapment)
- Pacemaker, artificial (tined lead)
- Heart defects, congenital (Chiari network)

INTRODUCTION

Entrapment of devices by intracardiac structures is a rare complication of invasive cardiac examinations or interventions¹⁻⁵. The tined type of pacemaker lead may carry increased risk of this complication because of the configuration of the tip. We treated a patient with atrioventricular block with a tined lead which became entrapped by the Chiari network, but the lead was available for sensing the atrial potential in VDD mode.

CASE REPORT

An 82-year-old woman with a history of hypertension and diabetes was referred to our hospital because of dizziness or near syncope on exercise. Her pulse rate was 40 beats/min. Electrocardiography demonstrated 2: 1 atrioventricular block and right bundle branch block. Chest radiography showed no pulmonary congestion. Transthoracic echocardiography did not show any intracardiac

tumorous lesion, abnormality of ventricular movements, or inter-atrial shunt flow. Emergent temporary pacing was performed, and her complaint disappeared thereafter.

Implantation of a dual chamber type of permanent pacemaker was performed on the third hospital day. A tined ventricular lead (Medtronic, 5054-52 cm, Medtronic Inc.) and a tined J-shaped atrial lead (Medtronic, 5554-45 cm) were passed through the left subclavian vein under local anesthesia. During the introduction of the first lead into the right ventricle, the tip of the lead became entrapped by an intraatrial structure, which seemed to be the Chiari network. All manipulations and the passage of various stylets failed to release the entrapped tip. Another tined J-shaped lead was also entrapped transiently, but was fortunately released soon after. We abandoned the extraction of the entrapped first lead, and decided to utilize that lead for atrial sensing because an intraatrial P wave potential of 0.6 to 1.2 mV could be recorded by the entrapped lead.

長野市民病院 循環器内科: 〒381-8551 長野県長野市富竹1333-1

Division of Cardiology, Nagano Municipal Hospital, Nagano

Address for correspondence: MARUYAMA T, MD, Division of Cardiology, Nagano Municipal Hospital, Tomitake 1333-1, Nagano, Nagano 381-8551; E-mail: maruyama@hospital.nagano.nagano.jp

Manuscript received March 4, 2004; revised May 27, 2004; accepted May 27, 2004

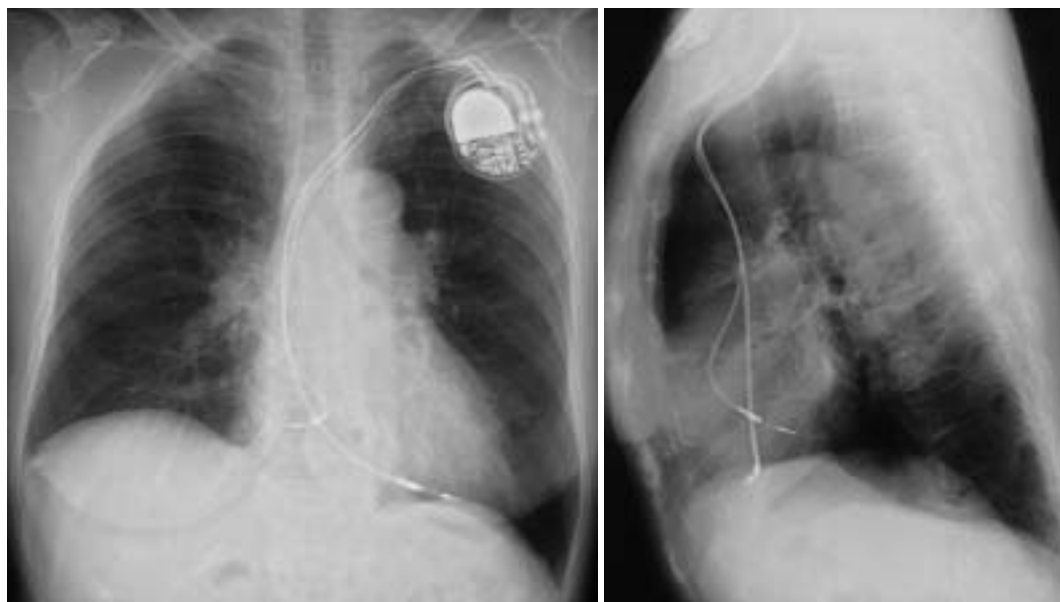


Fig. 1 Postoperative chest radiographs

Anterior view (left) and lateral view (right) showing the tip of the entrapped intraatrial lead is located posteriorly.

The tined J-shaped lead was withdrawn from the patient, and a new screw-in lead (Medtronic, Capsurefix, 5068-52 cm) was successfully introduced for right ventricular pacing and sensing without difficulty. The dual chamber pacemaker (Medtronic, Kappa, KDR721) was operated in VDD mode (60 to 120 pace/min) with the atrial sensitivity set to maximum (0.18 mV).

The lateral view of the postoperative radiography showed that the tip of the entrapped lead was situated toward the posterior wall of the right atrium (Fig. 1). Echocardiographic examination showed the entrapped atrial lead was thickened and appeared like a string of various sized beads, compared with the smooth appearance of the ventricular lead (Fig. 2). On electrocardiographic monitoring, the P-sensed ventricular pacing was prevalent, although under-sensing of the atrium with exclusive ventricular pacing was also recorded. Assessment of pacemaker function 1 week after the implantation showed the intraatrial P wave potential was 0.18 to 0.25 mV in the supine position and 0.30 to 0.50 mV in the sitting position.

The patient has suffered no events since discharge. Repeated assessment 5 months after showed the intraatrial P wave potential was 0.35 to 0.50 mV in all postures. During 5 months, the total number of paced ventricular beats was 13 million,

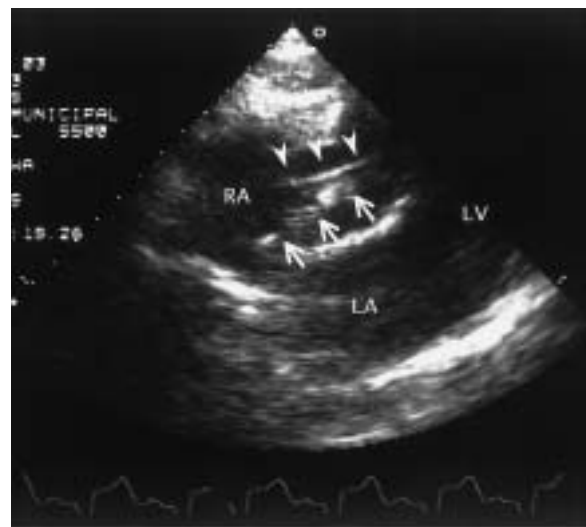

Fig. 2 Postoperative echocardiogram in the sub-xiphoid view

Compared with the smooth appearance of the ventricular lead (arrowheads) the entrapped atrial lead (arrows) is thickened and appears like a string of beads, suggesting entanglement by a filamentous and membranous structure.

RA = right atrium; LA = left atrium; LV = left ventricle.

whereas that of sensed atrial potential was eight and a half million, suggesting that P-sensed ventricular pacing amounted to about two thirds of all ventricular paced beats.

DISCUSSION

Endocardial leads of permanent pacemakers as well as implantable cardioverter defibrillators include some mechanisms to prevent dislodgement, one of which contains tines equipped near the tips⁶⁾. Tined leads may reduce the likelihood of perforation and cardiac tamponade, compared with screw-in leads, but have the potential disadvantage of increased probability of accidental entrapment by intracardiac structures. Difficult procedures to extract tined leads entrapped by the rim or the chordae of the tricuspid valve have previously been reported^{1,2)}. Lead entrapment by the Chiari network like the present case has not been reported, although a diagnostic catheter and a guide wire have been entrapped by the Chiari network^{3,4)}.

The Chiari network, together with the eustachian valve, is one of the congenital remnants of a membranous course in the embryo that directs oxygenated blood from the inferior vena cava across the foramen ovale. This remnant consists of a fine filamentous membrane attached to the coronary sinus⁷⁾. The Chiari network is present in 1.3% to 4% of autopsy cases and 2% of patients in transesophageal echocardiography series⁸⁾. In the present case, the observer (the first author) of the transthoracic echocardiography performed urgently at patient admission did not recognize the presence of the Chiari network. However, the following reasons led us to conclude that the structure entrapping the lead was the Chiari network. 1) Since the atrial electrical potential could be recorded, the tip of the lead was not located in the right ventricle but in the right atrium. 2) There was no tumorous lesion in

the right atrium. 3) The tip of the intraatrial lead was located posteriorly on the lateral view of the postoperative radiograph, so the structure entrapping the lead might be attached around the infero-posterior parts of the right atrium, such as the eustachian valve, crista terminalis, or thebesian valve. 4) Postoperative transthoracic echocardiography showed the thickened appearance of the entrapped lead, indicating a lead entangled by a filamentous or membranous structure. The patient refused transesophageal echocardiography, which might have shown some more information about the Chiari network.

The atrial electrical potential obtained from the entrapped lead was not constant, but depended on the patient's posture. However, we supposed that some under-sensing of the atrial potential would not significantly impair the exercise capacity of this elderly patient. We could also have introduced the third atrial lead and abandoned the entrapped lead. However, atrial pacing was not essential because her sinus node function was normal.

In general, the Chiari network is thought to be of little clinical significance, so observers of echocardiography may not pay very much attention to the Chiari network on routine examinations. However, the slight possibility of entrapment of intracardiac devices by the Chiari network during invasive examinations or interventions must be kept in mind. The present case suggests that if the Chiari network is recognized on echocardiography examination before the scheduled implantation of a permanent pacemaker or a cardioverter defibrillator, the operator should be prudent in selecting the type of leads and in manipulating their delivery. A screw-in lead might be preferable to a tined lead in such situations, otherwise the tined tip should not be turned infero-posteriorly in the right atrium.

要 約

ペースメーカー植え込みに際しキアリ網に捕捉されたタインド型リードを 心房電位の感知に利用した房室ブロックの1例

丸山 隆久 黒河内典夫

タインド型ペースメーカーリードは、その形状ゆえに心臓内の構造物に捕捉されてしまう可能性がまれながらある。症例は労作時のめまいを主訴とする82歳の女性。2:1の房室ブロックによる徐脈を認め、緊急一時ペーシングにより症状は消失した。永久ペースメーカー植え込み術の際に、タインド型の心室用リードが右房内でキアリ網に捕捉され抜去不可能となった。このリードから心

房電位を検出可能であったため、これを心房センシング専用とし、新たに挿入し留置したスクルーイン型の心室リードとともに、VDDモードでの作動とした。術後の経過は良好である。キアリ網の臨床的意義は一般には少ないが、術前評価においては心エコー図法でキアリ網の有無に注目すべきである。本例ではリード捕捉ののち、次善の合理的なペースングモードを選択しえた。

J Cardiol 2004 Dec; 44(6): 251 - 254

References

- 1) Parsonnet V, Bernstein AD, Omar AM, Rothbart ST, Schoenfeld R: Instantaneous lead entrapment: An unusual complication of nonthoracotomy implantation of an endocardial defibrillation lead. *Pacing Clin Electrophysiol* 1995; **18**: 2100 - 2102
- 2) Barakat K, Robinson NM, Dymond DS: Instantaneous lead entrapment: Successful percutaneous removal using the Cook Workstation. *Pacing Clin Electrophysiol* 1998; **21**(Pt): 774 - 775
- 3) Goldschlager A, Goldschlager N, Brewster H, Kaplan J: Catheter entrapment in a Chiari network involving an atrial septal defect. *Chest* 1972; **62**: 345 - 346
- 4) Shimoike E, Ueda N, Maruyama T, Kaji Y, Niho Y: Entrapment of a guide wire by the Chiari network in a patient with ablated idiopathic ventricular tachycardia. *J Interv Card Electrophysiol* 2001; **5**: 219 - 222
- 5) Sopher SM, Grace AA, Heald SC, Rowland E: Entrapment of an ablation catheter in the cardiac venous system: A case report. *Pacing Clin Electrophysiol* 1998; **21**: 1306 - 1308
- 6) Mond H, Sloman G: The small-tined pacemaker lead: Absence of dislodgment. *Pacing Clin Electrophysiol* 1980; **3**: 171 - 177
- 7) Armstrong WF, Feigenbaum H: Echocardiography: Anatomical variants. *in Heart Disease: A Textbook of Cardiovascular Medicine*(ed by Braunwald E, Zipes DP, Libby P), 6th Ed. WB Saunders, Philadelphia, 2001; p 164
- 8) Schneider B, Hofmann T, Justen MH, Meinertz T: Chiari network: Normal anatomic variant of risk factor for arterial embolic events? *J Am Coll Cardiol* 1995; **26**: 203 - 210