

Improved Septal Contraction and Coronary Flow Velocity After Cardiac Resynchronization Therapy Elucidated by Strain Imaging and Pulsed Wave Doppler Echocardiography

Hiroyuki KAYANO, MD
Hiroaki UEDA, MD
Tomoaki KAWAMATA, MD
Fumito MIYOSHI, MD
Tsutomu TOSHIDA, MD
Norikazu WATANABE, MD
Yuichi HIRANO, MD
Mitsuharu KAWAMURA, MD
Taku ASANO, MD
Shyhaku KOU, MD
Kaoru TANNO, MD
Masaki OZAWA, MD
Youichi KOBAYASHI, MD
Takashi KATAGIRI, MD, FJCC

Abstract

Objectives. The effects of cardiac resynchronization therapy (CRT) with various atrioventricular conduction delay settings were investigated on cardiac hemodynamic changes involved in coronary flow velocity using color and pulsed wave Doppler modalities and myocardial regional contractility using a novel echocardiographic technique (strain imaging).

Methods. Seven patients with advanced heart failure (left ventricular ejection fraction < 35%) and left bundle branch block (QRS \geq 140 msec) were treated with CRT. Color and pulsed wave Doppler imaging were performed from the apical four-chamber view to examine the cardiac functions such as stroke volume, cardiac output, mitral regurgitant volume and coronary flow velocity. Strain imaging was performed to quantify the asynchrony of both intraventricular and interventricular time delay between the septum and left ventricular free wall (posterior wall) and to assess the regional contractile function. Wall motion was also evaluated.

Results. Intraventricular and interventricular asynchrony were improved from 173 ± 18 to 60 ± 6 msec, and 69 ± 25 to 12 ± 3 msec, respectively. Stroke volume (55.2 ± 6.2 to 76.8 ± 10.8 ml; 39% up), cardiac output (3.9 ± 0.3 to 5.4 ± 0.5 l/min; 38% up) and coronary flow velocity (24 ± 3 to 36 ± 5 cm/sec; 50% up) were greatly increased and mitral regurgitant volume (59.7 ± 18.0 to 38.9 ± 11.3 ml; 35% down) was clearly decreased. Septal wall shortening was greatly increased from $10.2 \pm 2.3\%$ to $17.0 \pm 1.8\%$ and septal wall motion (radial thickening) was also improved simultaneously. Atrioventricular interval settings influenced all above parameters.

昭和大学医学部 第三内科: 〒142-8666 東京都品川区旗の台1-5-8

The Third Department of Internal Medicine, Showa University School of Medicine, Tokyo

Address for correspondence: KAYANO H, MD, The Third Department of Internal Medicine, Showa University School of Medicine, Hatanodai 1-5-8, Shinagawa-ku, Tokyo 142-8666

Manuscript received August 10, 2005; revised October 27, 2005; accepted November 7, 2005

Conclusions. CRT improved the cardiac hemodynamics involved in coronary flow significantly due to both resynchronization of inter and intra asynchrony, and improvement of the regional myocardial contraction in patients with severe congestive heart failure and complete left bundle branch block.

J Cardiol 2006 Feb; 47(2): 51-61

Key Words

■Cardiac surgery ■Doppler ultrasound (strain imaging, coronary flow velocity)
 ■Heart failure (cardiac resynchronization therapy) ■Myocardial contraction (regional)

INTRODUCTION

Cardiac resynchronization therapy (CRT) is a recent advance in non-pharmacological therapy for patients with severe heart failure with electro-mechanical delay. The principle of this therapy is to resynchronize the timing of the left ventricular wall contraction. Prior studies reported improved global left ventricular systolic function¹⁻⁴, reduced pulmonary capillary wedge pressure⁴, and decreased mitral regurgitation⁵. CRT also is effective in regressing left ventricular remodeling, diminishing energy cost, and is more powerful than medical therapy alone^{6,7}. As a result of contractile resynchronization, CRT improves the entire left ventricular systolic function, but whether left ventricular myocardial regional contractility and coronary flow velocity are improved or not, is unknown. Several studies^{8,9} concerned with the optimal settings for atrioventricular (AV) conduction delay rather than cardiac hemodynamic change have been reported, but no studies have discussed the relationship between AV conduction delay and coronary flow during CRT.

The present study investigated both hemodynamic changes involved in coronary flow velocity and myocardial regional contractility before and after CRT at various AV conduction delay settings.

SUBJECTS AND METHODS

Patients

Seven consecutive patients (three males and four females, mean age 81.0 ± 5.0 years) with an implanted bi-ventricular pacemaker were evaluated. All patients had severe heart failure characterized by left ventricular ejection fraction less than 35% and QRS wave complex duration longer than 140 msec with left bundle branch block pattern, and were still symptomatic (New York Heart Association class II or III). All patients underwent coronary angiography and none had coronary stenosis of greater than 50%. The etiologies of con-

gestive heart failure were ischemic heart disease in two patients, idiopathic dilated cardiomyopathy in two, hypertensive cardiomyopathy in two and amyloidosis cardiomyopathy in one. All patients were hospitalized for congestive heart failure at least twice in the year. Pharmacological management included diuretics, angiotensin receptor antagonists and beta-adrenergic blocking agents at the maximum tolerated doses in all patients, spironolactone in three and pimobendan in three. After recognizing clinical stability for at least 3 months, a bi-ventricular pacemaker was implanted and the average of the QRS complex duration significantly decreased from 167 ± 20 to 133 ± 10 msec ($p < 0.02$; **Table 1**).

Bi-ventricular pacemaker implantation

Pacemaker catheters were inserted through the subclavian vein and the right ventricle, and right atrium pacing leads were placed at the right atrial appendage to pace the right atrium and at the right ventricle apex to pace the right ventricle. The left ventricular pacing lead was inserted through the coronary sinus into the postero-lateral cardiac vein with the help of a venogram in all patients. The bi-ventricular devices used were PULSARTM MAX_DR, GUIDANT Japan K.K. in one patient, Actros DR, BIOTRONIK GmbH & Co. in four and Talent DR, ELA MEDICAL in two. After implantation, the AV interval (AV conduction delay: AV-) was changed based on the following four conditions, baseline (pacing off) and during CRT (AV-50, 100 and 150 msec).

Standard echocardiography

Standard echocardiography, including Doppler studies, was performed with a Vivid 7 (GE-YOKOKAWA medical system) equipped with a cardiac M3S (1.9/4.0 MHz) tissue harmonic transducer and a 7S (6.7 MHz) high frequency transducer. Left ventricular ejection fraction (LVEF; %) was assessed using the bi-planar Simpson's method, and left ventricular stroke volume (LVS)

Table 1 Clinical characteristics of the patients

Patient No.	Age (yr)	Sex	Diagnosis	LVEF (%)	QRS width (msec)	
					Before CRT	After CRT
1	79	Female	A	29	160 (CLBBB)	128
2	81	Male	Id	22	155 (CLBBB)	151
3	74	Male	I	18	197 (CLBBB)	160
4	89	Female	Id	19	182 (CLBBB)	116
5	86	Male	I	35	162 (CLBBB)	127
6	78	Female	H	25	159 (CLBBB)	120
7	80	Female	H	27	182 (CLBBB)	158
Mean ± SD	81 ± 5			25 ± 6	167 ± 20	133 ± 10*

* $p < 0.02$.

LVEF = left ventricular ejection fraction; CRT = cardiac resynchronization therapy; A = amyloidosis cardiomyopathy; I = ischemic heart disease; H = hypertensive cardiomyopathy; Id = idiopathic dilated cardiomyopathy; CLBBB = complete left bundle branch block.

; ml) and cardiac output (CO; l/min) were both assessed by pulsed wave Doppler echocardiography using the apical two-chamber view. The mitral regurgitation volume (MRV; ml) was also assessed by pulsed wave Doppler echocardiography using the apical four-chamber view. MRV is expressed as follows:

MRV (ml) = Left ventricular inflow volume per beat - LVSV

Left ventricular inflow volume per beat (ml) = $3.14 \times (Rm/2)^2 \times TVIm$

Where Rm (cm²) is the mitral ring diameter, and TVIm (cm) is the time velocity integral of the trans-mitral flow.

Coronary flow velocity (CFV; cm/sec) of the left anterior descending artery (LAD) was assessed by a transthoracic echo Doppler technique using a 7S high frequency transducer.

Strain imaging

Myocardial pulsed wave Doppler velocity profiles were recorded from the apical two-chamber view with adjustments to filter frequency, gain settings, pulse repetition frequency and color saturation and at the highest possible frame rate (≥ 100 frames/sec). The images were digitized and strain imaging (SI) was analyzed on line. SI is a novel technique that can calculate the compression and expansion of the myocardial regional length quantitatively. SI (%) is expressed as follows:

SI (%) = dX/X

Where dX is the changed myocardial length, and X is the original myocardial length.

Sample volumes (2 × 6 mm) were placed among

the basal segment of the interventricular septum (IVS), mid segment of the IVS and basal segment of the posterior. The strain curves of the three segments were examined and both peak systolic strain values and the time (msec) until the peak systolic strain from the QRS complex throughout a cardiac cycle were compared. Those values in other regions of the free wall were also evaluated, but there were no significant differences in the other regions compared with the posterior region. In this study, posterior values were used as representative of the free wall. At least 3 consecutive beats of sinus rhythm were measured in a blinded manner and an average value was obtained.

Study protocol

Investigations were performed just before discharge (mean period after CRT implantation; 9 ± 2 days) in all patients in stable condition. This study evaluated the following factors before and after CRT: intraventricular and interventricular mechanical delay; cardiac hemodynamic changes; and myocardial shortening and radial thickening of regional myocardium.

The intraventricular delay (msec) between the basal IVS and the basal posterior were evaluated as the time lag until peak systolic strain from the QRS complex. The interventricular delay between the left and right ventricular contractions were evaluated as the time lag until the peak velocity of each Doppler wave. Right ventricular ejection flow was assessed by pulsed wave Doppler echocardiography using the parasternal short-axis view of the aortic level.

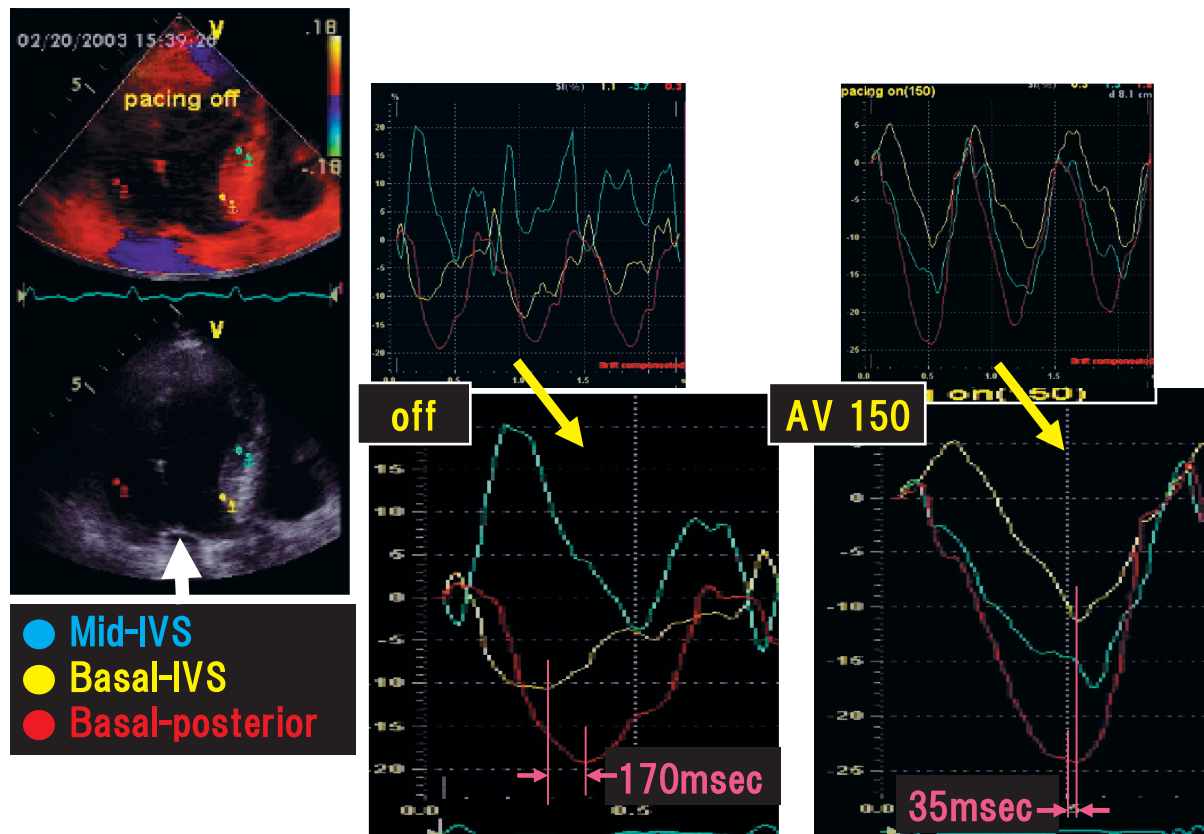


Fig. 1 Mechanical delay before and after cardiac resynchronization therapy

Typical images from the intraventricular delay measurements in the three myocardial regions (basal and mid IVS, basal posterior) using strain imaging before and during CRT (AV-150 msec). The time lag of the two regions (between basal IVS and posterior) until peak systolic strain during CRT (AV-150 msec ; 35 msec) shortened to less than the baseline value (170 msec). Wall motion of mid IVS was improved to hypokinesis from dyskinesis by CRT.

IVS = interventricular septum; AV = atrioventricular conduction delay. Other abbreviation as in Table 1.

All echocardiographic Doppler values such as LVSV, CO, LVEF, MRV and CFV were measured at baseline and during CRT (AV-50, 100 and 150 msec). The cardiac hemodynamic effect of the CRT was measured as a cardiac hemodynamic ratio (% ; CRT values/baseline value \times 100)

Myocardial shortening was evaluated as the peak systolic strain value. Radial myocardial contraction was evaluated by the M-mode method of the parasternal long-axis view as percentage wall thickening. The percentage wall thickening is expressed as follows:

$$\text{Percentage wall thickening} = \left(\frac{\text{EST} - \text{EDT}}{\text{EDT}} \right) \times 100$$

Where EST is the end-systolic thickness, and EDT is the end-diastolic thickness.

After continuation of the hemodynamic stability in each of the four conditions (baseline, AV-50, 100 and 150 msec) for at least 15 min, the results of

these examinations were studied. Informed consent was obtained from all patients and this study protocol was approved by the hospital's Ethics Committee.

Statistical analysis

Data are presented as mean \pm standard deviation (SD). Repeated analysis of variance (ANOVA) was used to compare cardiac hemodynamic (pulse Doppler) values, systolic strain values (%) and radial thickening (%) of both basal IVS and posterior wall at baseline and during CRT (AV-50, 100 and 150 msec). A *p* value < 0.05 was considered statistically significant.

RESULTS

Intraventricular and interventricular delays

Typical images from the intraventricular delay measurements in the three myocardial regions

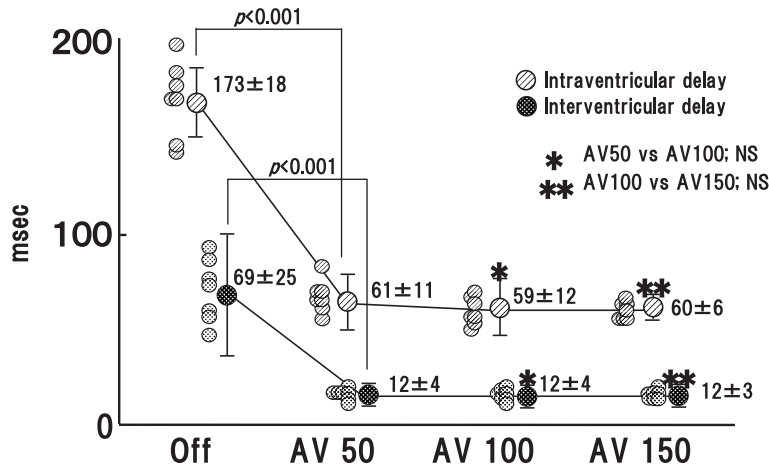


Fig. 2 Intraventricular and interventricular delays under the four conditions

Intraventricular delay improved significantly from the baseline value, as did interventricular delay. However, neither mechanical delay showed any significant differences between the three CRT conditions.

Abbreviations as in Table 1, Fig. 1.

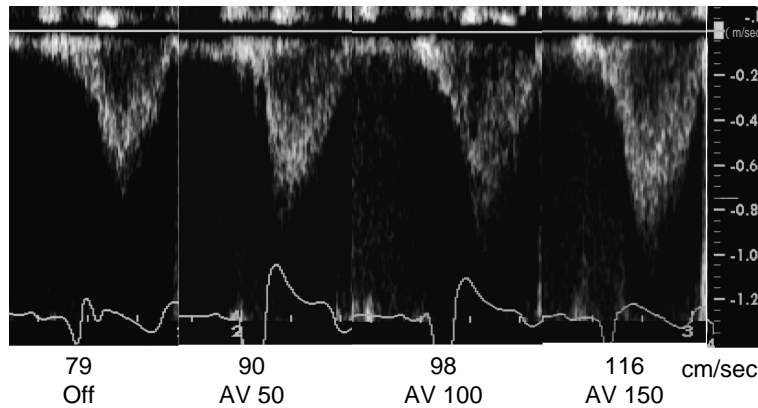


Fig. 3 Pulsed wave Doppler tracings at the left ventricular outflow tract

During CRT (AV-50, 100 and 150 msec), peak velocity accelerated gradually from 79 to 90, 98 and 116 cm/sec, respectively.

Abbreviations as in Table 1, Fig. 1.

(basal and mid IVS and basal posterior) using SI before and during CRT (AV-150 msec) are illustrated in **Fig. 1**. During CRT, wall motion of the mid-IVS improved to hypokinesis from dyskinesis. Intraventricular delay of the two regions (between the basal IVS and posterior) during CRT (AV-150 msec; 35 msec) shortened to less than the baseline value (170 msec).

Fig. 2 shows the intraventricular and interventricular delays of the two regions under the four conditions. CRT (AV-50, 100 and 150 msec) improved intraventricular delay significantly from a baseline value of 173 ± 18 to 61 ± 11 , 59 ± 12 and 60 ± 6 msec, respectively ($p < 0.001$), and also improved interventricular delay significantly from a baseline value of 69 ± 25 to 12 ± 4 , 12 ± 4 and 12 ± 3 msec, respectively ($p < 0.001$). However, neither mechanical delay showed any significant difference between the three CRT conditions.

Left ventricular systolic function

Fig. 3 shows a typical flow pattern of the left

ventricular outflow tract. During CRT (AV-50, 100 and 150 msec), peak velocity accelerated from 79 to 90, 98 and 116 cm/sec, respectively. **Fig. 4** shows a typical image of LVEF measurements using the bi-planar Simpson's method. During CRT (150 msec), LVEF increased from 28% to 40%. Wall motion of the mid-IVS improved to hypokinesis from dyskinesis after CRT (arrows).

Fig. 5 shows a graph of the hemodynamic change ratio. During CRT (AV-50 msec), LVSV, CO and LVEF increased significantly from their baseline values (55.2 ± 6.2 ml, 3.9 ± 0.3 l/min and $28 \pm 5\%$, respectively) to 68.5 ± 6.0 ml, 5.0 ± 0.4 l/min and $33 \pm 6\%$, respectively ($p < 0.01$, $p < 0.001$, $p < 0.001$, respectively). During CRT (AV-100 and 150 msec), the respective values of LVSV (74.1 ± 9.6 , 76.8 ± 10.8 ml), CO (5.4 ± 0.4 , 5.4 ± 0.5 l/min) and LVEF ($40 \pm 4\%$, $41 \pm 5\%$) showed greater improvement ($p < 0.05$, $p < 0.05$, respectively) over CRT (AV-50 msec). However, LVSV, CO and LVEF showed no significant differences between CRT (AV-100 msec) and CRT (AV-

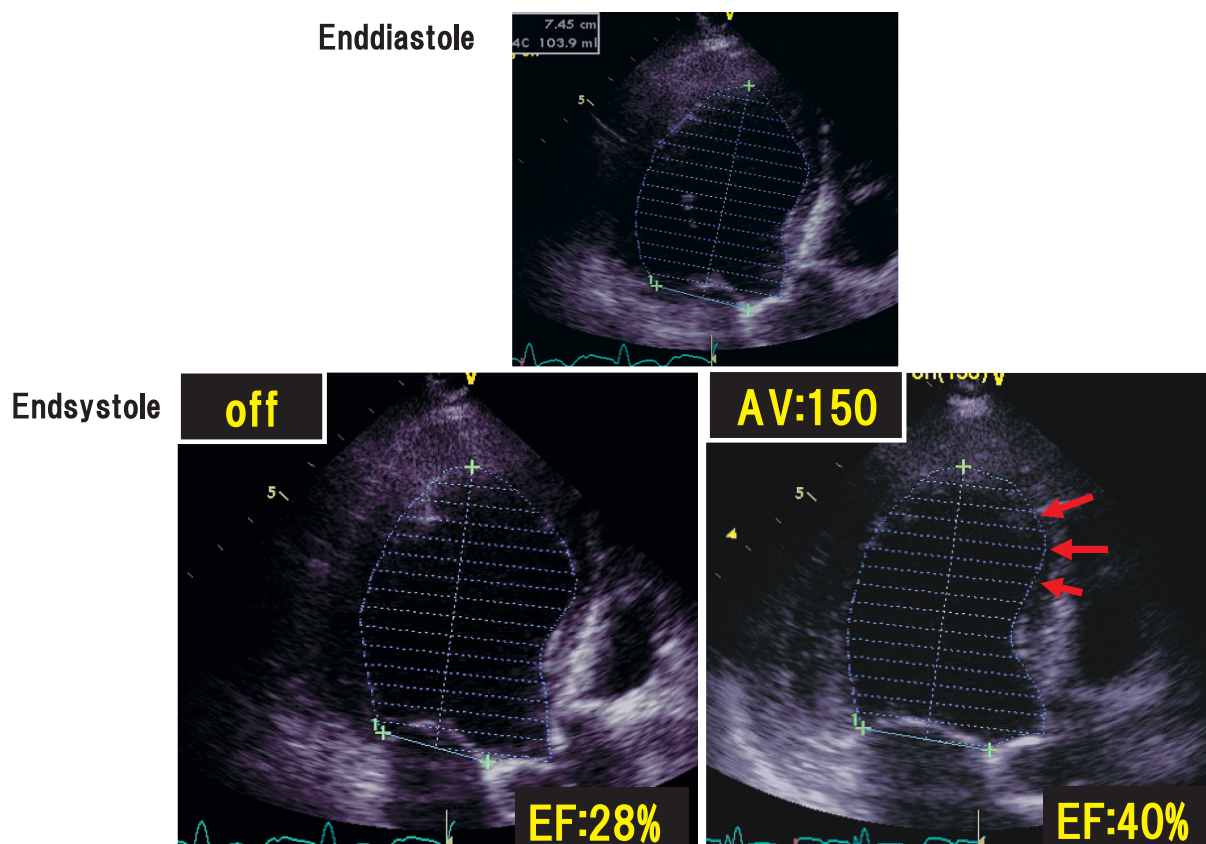


Fig. 4 Left ventricular ejection fraction using the bi-planar Simpson's method
 During CRT(150 msec), LVEF increased from 28% to 40%.
 Abbreviations as in Table 1, Fig. 1.

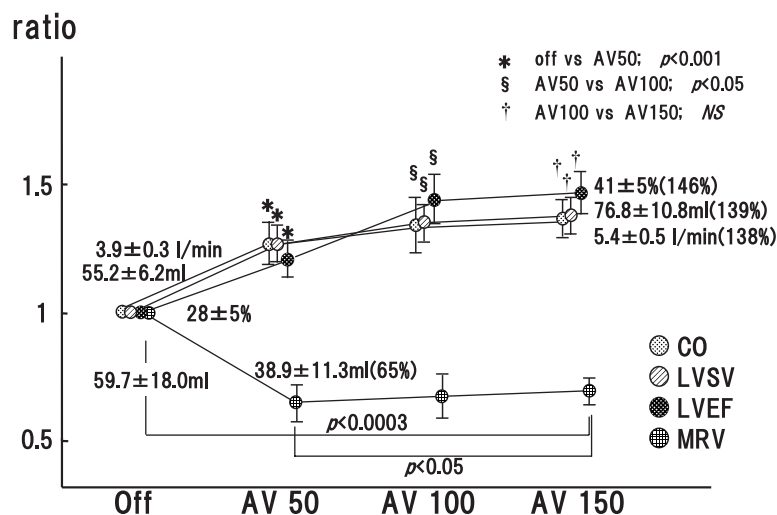


Fig. 5 Changes of cardiac hemodynamics before and during CRT

During CRT, LVSF, CO and LVEF increased significantly from their baseline values. During CRT (AV-100 and 150 msec), all values showed greater improvement over CRT(AV-50 msec). However, no significant differences were observed between CRT(AV-100 msec) and CRT(AV-150 msec). MRV during CRT(AV-50 msec) significantly decreased from the baseline value ($p < 0.0003$). However, no significant differences were observed between the three CRT conditions. LVSF = left ventricular stroke volume; CO = cardiac output; MRV = mitral regurgitation volume. Other abbreviations as in Table 1, Fig. 1.

150 msec)

On the other hand, MRV during CRT(AV-50 msec) significantly decreased from 59.7 ± 18.0 to 38.9 ± 11.3 ml ($p < 0.0003$). However, MRV showed no significant differences between the three

CRT conditions.

Coronary flow velocity in the left anterior descending artery

Typical images of color Doppler signals and

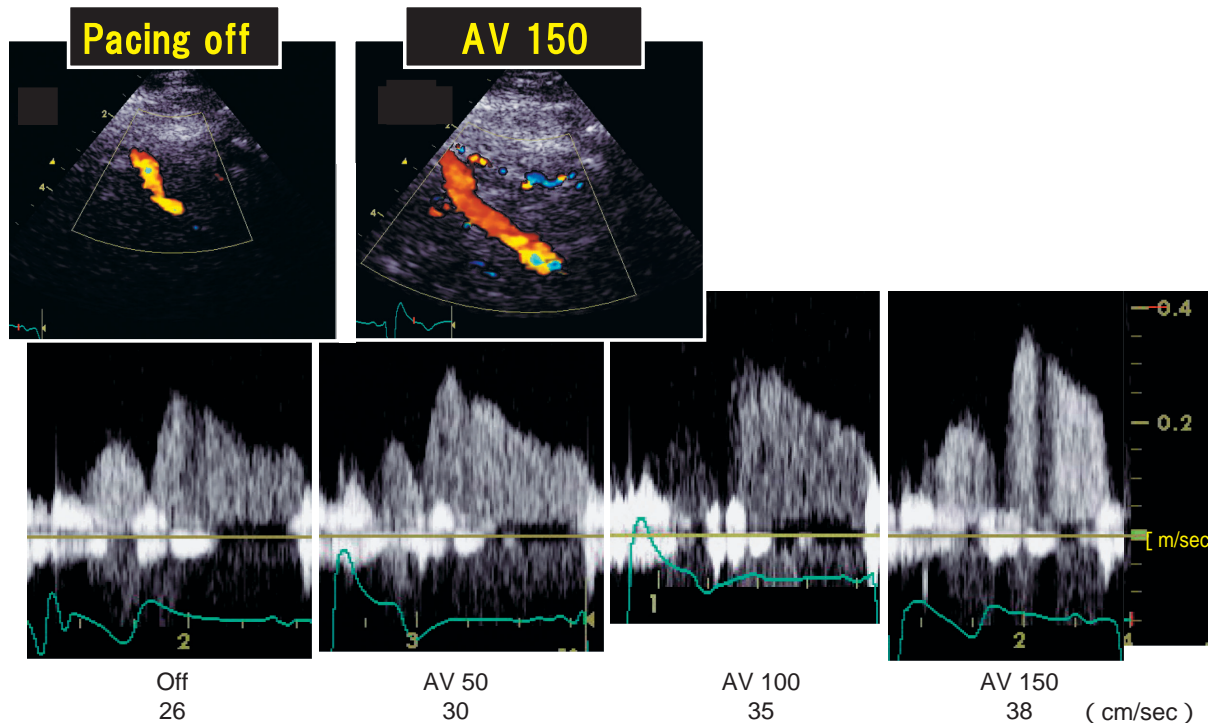


Fig. 6 Color Doppler signals and pulsed wave Doppler tracings in the left anterior descending coronary artery

Peak velocity during CRT(AV-50, 100 and 150 msec)accelerated from 26 to 30, 35 and 38 cm/sec, respectively.

Abbreviations as in Table 1, Fig. 1.

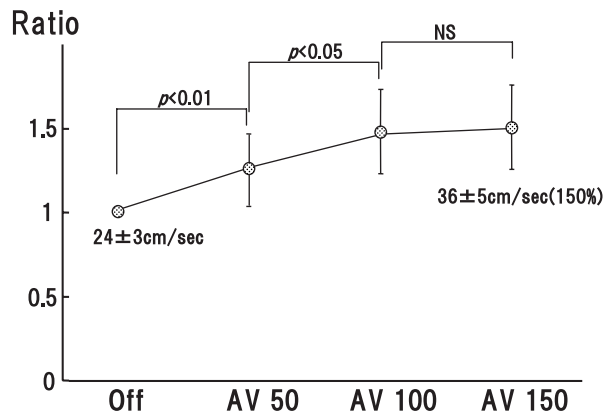


Fig. 7 Coronary flow velocity in the left anterior descending coronary artery

Coronary flow velocity increased significantly from the baseline values with CRT. CRT(AV-100 and 150 msec) showed greater improvement over CRT(AV-50 msec). However, no significant difference was observed between CRT(AV-100 msec)and CRT(AV-150 msec). Abbreviations as in Table 1, Fig. 1.

pulsed Doppler waves of LAD flow are shown in **Fig. 6**. Peak velocity during CRT(AV-50, 100 and 150 msec)accelerated from 26 to 30, 35, 38 cm/sec, respectively.

Fig. 7 shows the coronary flow velocity change ratio. During CRT(AV-50 msec), CFV increased significantly from their baseline values(24 ± 3 cm/sec)to 31 ± 4 cm/sec($p < 0.01$). During CRT (AV delay-100 and 150 msec), CFV(35 ± 5 , 36 ± 5 cm/sec, respectively)showed greater improvement over CRT(AV-50 msec). However, CFV showed no significant differences between CRT (AV-100 msec)and CRT(AV-150 msec).

Myocardial regional contraction

CRT improved both myocardial shortening and radial contraction. During CRT(AV-50 msec), myocardial shortening of the basal IVS improved significantly from the baseline value(10.2 ± 2.3) to 13.5 ± 3.0 ($p < 0.05$). During CRT(AV-100 and 150 msec), values of 16.7 ± 1.6 and 17.0 ± 1.8 , respectively, showed greater improvement over CRT(AV-50 msec)($p < 0.05$). However, no significant difference was observed between CRT(AV-

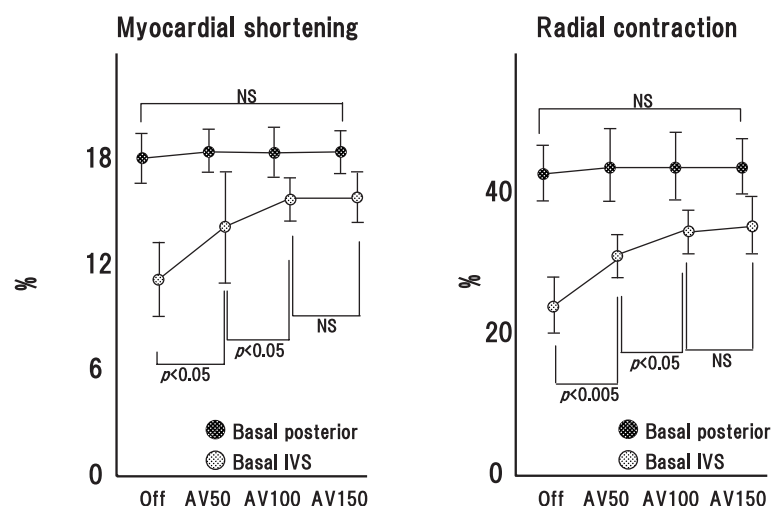


Fig. 8 Myocardial shortening and radial thickening

Left: Myocardial shortening of the basal IVS improved significantly from the baseline value with CRT. During CRT(AV-100 and 150msec), greater improvement was shown over CRT(AV-50 msec) ($p < 0.05$). However, a significant difference was observed between CRT(AV-100 msec) and CRT(AV-150 msec). Myocardial shortening of the basal posterior did not change with or without CRT, regardless of the AV conduction delay.

Right: Radial thickening of the basal IVS improved significantly from the baseline value with CRT. During CRT(AV-100 and 150msec), greater improvement was shown over during CRT(AV-50 msec) ($p < 0.001$). However, as with myocardial shortening, no significant difference was observed between CRT(AV-100 msec) and CRT(AV-150 msec). Radial thickening of the basal posterior also did not change with or without CRT, regardless of the AV conduction delay.

Abbreviations as in Table 1, Fig. 1.

100 msec) and CRT(AV-150 msec). Myocardial shortening of the basal posterior did not change with or without CRT, regardless of the AV conduction delay(**Fig. 8 - left**).

Similarly, during CRT(AV-50 msec), radial contraction of the basal IVS improved significantly from the baseline value(22.3 ± 3.5) to 30.0 ± 2.9 ($p < 0.005$). During CRT(AV-100 and 150 msec), values of 34.0 ± 2.5 and 34.3 ± 3.1 , respectively, also showed greater improvement over CRT(AV-50 msec) ($p < 0.05$). However, no significant difference was observed between CRT(AV-100 msec) and CRT(AV-150 msec). Radial thickening of the basal posterior also did not change with or without CRT, regardless of the AV conduction delay(**Fig. 8 - right**).

DISCUSSION

The mechanism by which CRT improves mechanical left ventricular function in patients with heart failure and ventricular asynchrony is not completely understood¹⁰). Our study was aimed at assessing the relationships between acute hemodynamic improvement and myocardial regional contraction after CRT at varying AV conduction delays

in patients with severe heart failure and complete left bundle branch block(CLBBB).

In this study, after CRT, all seven patients showed significant improvement in the electrical delay and mechanical delay and were consequently discharged. The degree and range of mechanical delay is the most powerful predictor^{11,12}) for cardiac functional improvement after CRT. The optimal pacing site is the most delayed wall¹³).

Our seven patients had left ventricular septal asynchrony over a wider range and myocardial viability, and whole cardiac pump function improved after CRT in all patients. Although many reports have evaluated the degree of the mechanical delay and improvement after CRT using the tissue Doppler imaging(TDI) method¹²⁻¹⁷), this study used the SI method that can evaluate the initiation of regional wall contraction directly and quantitatively regardless of cardiac translation and tethering¹⁸⁻²⁰). Due to these reasons, the SI method was superior for the detection of CRT candidates.

Cardiac hemodynamics in our patients demonstrated improvement in the LVSV, CO, and MRV by 30 - 40%. Previously, patients who responded to CRT to improve the cardiac function had improved

CO, pulmonary arterial wedge pressure, and MRV by 25 - 40%^{1-4,12}). Similar results were shown in this study. The cardiac output improves because of reduction or disappearance of diastolic mitral regurgitation when the pacing occurs just after the end of AV interval; 75 - 80 msec of atrial kick^{8,9}). We inferred that the cause of reduced CO during CRT (AV-50 msec) is the time phase at the middle of the left atrial kick and the filling volume is thus insufficient.

Coronary flow of the LAD was measured as an index for hemodynamics evaluation after CRT. Transthoracic evaluation of coronary flow correlates significantly with the value measured using a Doppler flow wire during coronary angiography and its reliability is thus high^{21,22}). In this study, the CFV improved equivalently to or more than the LVSV (150% vs 139% after CRT (AV-150 msec)). In an animal experiment in which a pacemaker was implanted to cause CLBBB reversely, the myocardial internal pressure gradient of the IVS changes and myocardial internal pressure during diastole increased equivalently to or more than that during systole in CLBBB. Also, the flow velocity of the septal branch of LAD decreases significantly ($p < 0.05$)⁵). In clinical patients with stenosis at the coronary artery of LAD ($\geq 50%$) with CLBBB, the ischemic detectable sensitivity of the LAD was favorable, but the specificity significantly decreased²³⁻²⁵ as compared to patients without CLBBB. CLBBB can disturb the coronary perfusion of the LAD through shortening of the diastolic flow duration²⁶). In the absence of stenosis at the coronary artery, the improvement of the coronary flow velocity is assumed to parallel the improvement of the LVSV as a rule. However, the improvement of the LAD flow velocity was equivalent to or more than the LVSV improvement in this study, possibly because the improvement of the IVS asynchrony may have normalized the septal myocardial internal pressure gradient and promoted the improvement of the LAD coronary flow.

Many studies have investigated wall motion quantitative analysis using strain imaging and strain rate imaging^{15-17,19,20}). We evaluated the left ventricular shortening using strain imaging and left ventricular radial thickening using M-mode method. Although the shortening and radial thickening of the basal IVS improved significantly by CRT, those of the basal posterior did not improve.

In the animal experiment with CLBBB the septal wall motion decreased significantly due to the change of myocardial internal pressure gradient at the CLBBB but the posterior wall motion did not change²³). In this study, we considered that the improvement of the asynchrony after CRT might normalize the collapse of the myocardial internal pressure gradient and improve the septal wall motion. Although CRT is reported not to improve myocardial contraction^{11,14}), cases were evaluated by the TDI method. However, the TDI method is influenced by cardiac translation, so small change of regional improvement cannot be evaluated directly. We considered that strain imaging can evaluate such small changes directly and this method evaluated the septal contraction accurately. The degree of wall motion improvement was significantly small during CRT (AV-50 msec), presumably because the left ventricular preload was so small due to the middle of the atrial kick that improvement of LVSV decreased, based on Laplace's theorem¹).

Limitations

This study evaluated only seven patients with apparent asynchrony (most delayed wall) of the IVS. Regional and whole cardiac function improved in all seven patients after CRT. However, patients who do not respond to CRT are present among patients with severe CHF associated with CLBBB. Additional investigations must be done at the other asynchrony site and different pacing sites. In this study, the acute effectiveness of cardiac hemodynamics and regional myocardial contractile function after CRT was evaluated, but the relationship between the improvement of the acute effectiveness and the long-term prognosis was not evaluated. Among the three AV conduction delays (50, 100 and 150 msec), cardiac hemodynamics with AV delays (100 and 150 msec) showed greater improvement than that of AV-50 msec in this study, but the optimal AV conduction delays in various patients will differ.

CONCLUSIONS

CRT improved cardiac hemodynamics involved in coronary flow significantly due to both resynchronization of inter and intra asynchrony, and improvement of regional myocardial contraction in patients with severe congestive heart failure and

CLBBB. However, the optimal AV conduction delay settings must be considered carefully.

Acknowledgments

The authors thank all staff in the Third Department of Internal Medicine, Showa University School of Medicine for scientific sug-

要 約

完全左脚ブロックを有する重症心不全の心臓再同期療法後に Strain エコー法を用いて評価した中隔心筋収縮と冠血流速度の改善

茅野 博行 上田 宏昭 川又 朋章 三好 史人 土至田 勉
渡辺 則和 平野 雄一 河村 満晴 浅野 拓 江 修博
丹野 郁 小澤 優樹 小林 洋一 片桐 敬

背景と目的: 薬剤抵抗性の重症心不全患者に心臓再同期療法(CRT)が広く臨床応用されている。最近では組織ドップラー法を用いてCRTの適応の決定や効果判定が行われているが、今回我々は、Strainエコー法やパルスドップラー法を用いてCRTの条件設定が心機能、冠血流、そして局所心筋収縮に及ぼす影響を検討する。

方 法: 対象は左脚ブロック(QRS幅 ≥ 140 msec)を有しCRTを行った重症心不全(左室駆出率 $< 35\%$)患者7例である。CRTにおける房室伝導時間の設定(50, 100, 150 msec)が心拍出量、僧帽弁逆流流量や左前下行枝冠血流速度に及ぼす変化をパルスドップラー法を用いて測定するとともに strain エコー法を用いて心室内と心室間の機械的な同期性および心筋局所収縮能に対する影響を検討した。

結 果: CRTにより心室内機械的遅延は 173 ± 18 msec から CRT後は 60 ± 6 msecへと有意に短縮し、心室間機械的遅延も同様に 69 ± 25 から 12 ± 3 msecへと有意に短縮した。CRT前に比較してCRT後最大で1回拍出量は 55.2 ± 6.2 から 76.8 ± 10.8 ml/へ、心拍出量は 3.9 ± 0.3 から 5.4 ± 0.5 l/min へ、左前下行枝冠血流速度は 24 ± 3 から 36 ± 5 cm/secへと有意に増加し、僧帽弁逆流流量は 59.7 ± 18.0 から 38.9 ± 11.3 ml/へと有意に減少した。また、CRT後最大で中隔心筋収縮率は $10.2 \pm 2.3\%$ から $17.0 \pm 1.8\%$ と有意に増大したが、後壁の収縮率に変化はなかった。房室伝導時間を変更することで中隔の局所心筋収縮能が改善し全体的な心機能も向上したうえ、冠血流速度も同様に改善した。

結 論: CRTは心臓全体のポンプ機能の効率を向上させるだけでなく、冠血流速度や局所心筋の収縮能も改善させることが示唆された。

J Cardiol 2006 Feb; 47(2): 51 - 61

References

- 1) Kass DA, Chen C-H, Curry C, Talbot M, Berger R, Fetcs B, Nevo E: Improved left ventricular mechanics from acute VDD pacing in patients with dilated cardiomyopathy and ventricular conduction delay. *Circulation* 1999; **99**: 1567 - 1573
- 2) Auricchio A, Stellbrink C, Block M, Sack S, Vogt J, Bakker P, Klein H, Kramer A, Ding J, Salo R, Tockman B, Pochet T, Spinelli J, for the Pacing Therapies for Congestive Heart Failure Study Group; The Guidant Congestive Heart Failure Study Group: Effect of pacing chamber and atrioventricular delay on acute systolic function of paced patients with congestive heart failure. *Circulation* 1999; **99**: 2993 - 3001
- 3) Leclercq C, Cazeau S, Le Breton H, Ritter P, Mabo P, Gras D, Pavin D, Lazarus A, Daubert J-C: Acute hemodynamic effects of biventricular DDD pacing in patients with end-stage heart failure. *J Am Coll Cardiol* 1998; **32**: 1825 - 1831
- 4) Blanc JJ, Etienne Y, Gilard M, Mansourati J, Munier S, Boschat J, Benditt DG, Lurie KG: Evaluation of different ventricular pacing sites in patients with severe heart failure: Results of an acute hemodynamic study. *Circulation* 1997; **96**: 3273 - 3277
- 5) Brecker SJ, Xiao HB, Sparrow J, Gibson DG: Effects of dual-chamber pacing with short atrioventricular delay in dilated cardiomyopathy. *Lancet* 1992; **340**: 1308 - 1312
- 6) Lau CP, Yu CM, Chau E, Fan K, Tse HF, Lee K, Tang MO, Wan S-H, Law T-C, Lee P-Y, Lam Y-M, Hill MR: Reversal of left ventricular remodeling by synchronous biventricular pacing in heart failure. *Pacing Clin Electrophysiol* 2000; **23**: 1722 - 1725
- 7) Nelson GS, Berger RD, Fetcs BJ, Talbot M, Hare JM,

- Kass DA, Spinelli JC: Left ventricular or biventricular pacing improves cardiac function at diminished energy cost in patients with dilated cardiomyopathy and left bundle-branch block. *Circulation* 2000; **102**: 3053 - 3059
- 8) Ishikawa T, Sumita S, Kimura K, Kikuchi M, Kosuge M, Kuji N, Endo T, Sugano T, Sigemasa T, Kobayashi I, Tochikubo O, Usui T: Prediction of optimal atrioventricular delay in patients with implanted DDD pacemakers. *Pacing Clin Electrophysiol* 1999; **22**: 1365 - 1371
 - 9) Ishikawa T, Sumita S, Kimura K, Kikuchi M, Matsushita K, Ohkusu Y, Nakagawa T, Kosuge M, Usui T, Umemura A: Optimization of atrioventricular delay and follow-up in patient with congestive heart failure and with bi-ventricular pacing. *Jpn Heart J* 2001; **42**: 781 - 787
 - 10) Abraham WT, Hayes DL: Cardiac resynchronization therapy for heart failure. *Circulation* 2003; **108**: 2596 - 2603
 - 11) Ansalone G, Giannantoni P, Ricci R, Trambaiolo P, Laurenti A, Fedele F, Santini M: Doppler myocardial imaging in patients with heart failure receiving biventricular pacing treatment. *Am Heart J* 2001; **142**: 881 - 896
 - 12) Yu CM, Fung WH, Lin H, Zhang Q, Sanderson JE, Lau CP: Predictors of left ventricular reverse remodeling after cardiac resynchronization therapy for heart failure secondary to idiopathic dilated or ischemic cardiomyopathy. *Am J Cardiol* 2002; **91**: 684 - 688
 - 13) Ansalone G, Giannantoni P, Ricci R, Trambaiolo P, Fedele F, Santini M: Doppler myocardial imaging to evaluate the effectiveness of pacing sites in patients receiving biventricular pacing. *J Am Coll Cardiol* 2002; **39**: 489 - 499
 - 14) Yu CM, Chau E, Sanderson JE, Fan K, Tang MO, Fung WH, Lin H, Kong S-L, Lam Y-M, Hill M, Lau C-P: Tissue Doppler echocardiographic evidence of reverse remodeling and improved synchronicity by simultaneously delaying regional contraction after biventricular pacing therapy in heart failure. *Circulation* 2002; **105**: 438 - 445
 - 15) Oki T, Tabata T, Mishiro Y, Yamada H, Abe M, Onose Y, Wakatsuki T, Iuchi A, Ito S: Pulsed tissue Doppler imaging of left ventricular systolic and diastolic wall motion velocities to evaluate differences between long and short axes in healthy subjects. *J Am Soc Echocardiogr* 1999; **12**: 308 - 313
 - 16) Uematsu M, Miyatake K, Tanaka N, Matsuda H, Sano A, Yamazaki N, Hirama M, Yamagishi M: Myocardial velocity gradient as a new indicator of regional left ventricular contraction: Detection by a two-dimensional tissue Doppler imaging technique. *J Am Coll Cardiol* 1995; **26**: 217 - 223
 - 17) Yamada H, Oki T, Tabata T, Mishiro Y, Abe M, Onose Y, Wakatsuki T, Iuchi A, Ito S: Assessment of the systolic left ventricular myocardial velocity profile and gradient using tissue Doppler imaging in patients with hypertrophic cardiomyopathy. *Echocardiography* 1999; **16**: 775 - 783
 - 18) Popovic ZB, Grimm RA, Perlic G, Chinchoy E, Geraci M, Sun JP, Donal E, XU X-F, Greenberg NL, Wilkoff BL, Thomas JD: Noninvasive assessment of cardiac resynchronization therapy for congestive heart failure using myocardial strain and left ventricular peak power as parameters of myocardial synchrony and function. *J Cardiovasc Electrophysiol* 2002; **13**: 1203 - 1208
 - 19) Weidemann F, Eyskens B, Jamal F, Mertens L, Kowalski M, D Hooge J, Bijinens B, Gewilling M, Rademakers F, Hatle L, Sutherland GR: Quantification of regional left and right ventricular radial and longitudinal function in healthy children using ultrasound-based strain rate and strain imaging. *J Am Soc Echocardiogr* 2002; **15**: 20 - 28
 - 20) Urheim T, Edvardsen H, Torp H, Angelsen B, Smiseth OA: Myocardial strain by Doppler echocardiography: Validation of a new method to quantify regional myocardial function. *Circulation* 2000; **102**: 1158 - 1164
 - 21) Hozumi T, Yoshida K, Ogata Y, Akasaka T, Asami Y, Takagi T, Morioka S: Noninvasive assessment of significant left anterior descending coronary artery stenosis by coronary flow velocity reserve with transthoracic color Doppler echocardiography. *Circulation* 1998; **97**: 1557 - 1562
 - 22) Caiati C, Montaldo C, Zedda N, Bina A, Iliceto S: New noninvasive method for coronary flow reserve assessment: Contrast-enhanced transthoracic second harmonic echo Doppler. *Circulation* 1999; **99**: 771 - 778
 - 23) Ono S, Nohara R, Kambara H, Okuda K, Kawai C: Regional myocardial perfusion and glucose metabolism in experimental left bundle branch block. *Circulation* 1992; **85**: 1125 - 1131
 - 24) DePuey EG, Guertler-Krawczynska E, Robbins WL: Thallium-201 SPECT in coronary artery disease patients with left bundle branch block. *J Nucl Med* 1988; **29**: 1479 - 1485
 - 25) Jazmati B, Sadaniantz A, Emaus SP, Heller GV: Exercise thallium-201 imaging in complete left bundle branch block and the prevalence of septal perfusion defects. *Am J Cardiol* 1991; **67**: 46 - 49
 - 26) Youn HJ, Park CS, Cho EJ, Jung HO, Jeon NK, Lee JM, Oh YS, Chung WS, Kim JH, Choi KB, Hong SJ: Left bundle branch block disturbs left anterior descending coronary artery flow: Study using transthoracic Doppler echocardiography. *J Am Soc Echocardiogr* 2005; **18**: 1093 - 1098