

## Method Analysis for Optimal Continuous Imaging Using Intravascular Optical Coherence Tomography

Koichiro ASAWA, MD  
Toru KATAOKA, MD  
Yoshiki KOBAYASHI, MD  
Takao HASEGAWA, MD  
Hiroki NISHIOKA, MD  
Hajime YAMASHITA, MD  
Zhaohui QIU, MD  
Shoichi EHARA, MD  
Makoto HIROSE, MD<sup>\*1</sup>  
Kimio KAMIMORI, MD<sup>\*1</sup>  
Kenei SHIMADA, MD, FJCC<sup>\*2</sup>  
Minoru YOSHIYAMA, MD, FJCC  
Junichi YOSHIKAWA, MD, FJCC\*

### Abstract

**Objectives.** Optical coherence tomography (OCT) is a high-resolution imaging method that can clearly visualize vessels through the displacement of blood with flushing agents. Continuous imaging methods have not been established. This study investigated optimal methods for continuous OCT imaging.

**Methods.** Thirty-four arteries with stent implantation (24 peripheral and 10 coronary arteries) in 14 pigs were examined using OCT with a motorized pullback device. Two imaging methods (flush alone by liquid substance and flush with occlusion) were compared. Adequate image acquisition was defined as the entire circumferential intimal layer being detectable within continuous segments. To investigate factors that could influence image quality, stented regions were divided into 4 - 5 mm segments.

**Results.** The flush with occlusion method provided better OCT images compared to flush alone (flush with occlusion: 60.9%, flush alone: 8.7%,  $p = 0.0002$ ). Using the flush with occlusion method, the rate of adequate image acquisition was 64.4% and visualization of > 75% intimal circumference was 83.5%. Intravascular ultrasound could detect all stented regions. Segmental analyses found more adequate images were detected in smaller vessels (adequate segment:  $3.8 \pm 0.4$  mm, inadequate segment:  $4.2 \pm 0.8$  mm,  $p < 0.0001$ ) or with centered image wire position (adequate segment: center 35%, inadequate segment: center 14%,  $p = 0.003$ ). In addition, side branches did not affect image quality.

**Conclusions.** To acquire continuous OCT images, the flush with occlusion method was more effective compared to flush alone. Moreover, image quality is affected by vessel size and imaging wire position. These results suggest that optimized OCT imaging can provide continuous vessel detection.

J Cardiol 2006 Mar; 47(3): 133-141

大阪市立大学大学院医学研究科 循環器病態内科学: 〒545-8585 大阪市阿倍野区旭町1-4-3; <sup>\*1</sup>東住吉森本病院 内科, 大阪; <sup>\*2</sup>大阪掖済会病院 心臓血管内科, 大阪

Department of Internal Medicine and Cardiology, Osaka City University Medical School, Osaka; <sup>\*1</sup>Department of Internal Medicine, Higashisumiyoshi Morimoto Hospital, Osaka; <sup>\*2</sup>Department of Cardiovascular Medicine, Osaka Ekisaikai Hospital, Osaka

**Address for correspondence:** KATAOKA T, MD, Department of Internal Medicine and Cardiology, Osaka City University Medical School, Asahimachi 1-4-3, Abeno-ku, Osaka 545-8585; E-mail: torukata@med.osaka-cu.ac.jp

Manuscript received July 13, 2005; revised October 13 and November 17, 2005; accepted November 17, 2005

**Key Words**

■Intravascular ultrasound (optical coherence tomography) ■Atherosclerosis  
 ■Cardiovascular disease ■Experimental medicine

**INTRODUCTION**

Optical coherence tomography (OCT) is a novel high-resolution imaging device, providing detailed cross-sectional images of vessel components. The resolution of OCT is approximately 10 to 20  $\mu\text{m}$ , which is 10 times that of intravascular ultrasound (IVUS)<sup>1,2</sup>. Several *in vitro* and *in vivo* studies using OCT have demonstrated detection of the architectural morphology of the atherosclerotic vessels, including thin fibrous cap, lipid pool, calcification, and macrophage accumulation<sup>1,3-5</sup>. However, displacing blood with flush agents is indispensable for clear visualization of OCT<sup>6</sup>. At present, the maximum duration of continuous OCT imaging after a single purge of flush agents is limited to only a few seconds, at most<sup>1,3</sup>. Information resulting from entire vessel examination using OCT would offer more valuable knowledge in the field of atherosclerosis and cardiovascular intervention. This study investigated the optimal methods for continuous intravascular OCT imaging.

**SUBJECTS AND METHODS****Experimental protocol**

Fourteen miniature pigs (average weight  $25.6 \pm 3.6$  kg) were used. The swine were anesthetized using thiopental (20 - 25 mg/kg), and supported with a ventilator. A 7F or 8F sheath introducer was placed into the femoral artery or carotid artery, and guide catheters were used. Thirty-nine commercially available metal stents were implanted in 34 arteries (14 femoral arteries, and 10 internal iliac arteries, and 10 coronary arteries). In 5 cases, 2 stents were implanted in the same femoral artery, so there were 19 stents in femoral arteries, 10 stents in internal iliac arteries, and 10 stents in coronary arteries. Various types of stents were used according to the vessel size. The stent diameter size was determined using a balloon: artery ratio (1.1 - 1.3) based on angiography data. Intravenous heparin (250 U/kg) was administered during the procedure. The procedural steps were performed in the following order: first angiogram, first IVUS, stent implantation, second angiogram, second IVUS, OCT and third angiogram. After stent implantation, all animals

were treated with ticlopidine (100 mg/day) for 4 weeks. The study protocol was reviewed by the ethics committee on animal research of our institution and was found to conform to the guidelines of animal care.

**OCT imaging system**

The OCT system used in the present study consisted of computer, display, patient interface unit and 0.014 inch imaging wire (LightLab, Inc.). A motorized pullback system at 1.0 mm/sec was used. OCT images were acquired at 15 frames per second, displayed with an inverse gray-scale lookup table, and digitally archived. The resolution capacity of the OCT system was 15  $\mu\text{m}$  in axial and 25  $\mu\text{m}$  in lateral views.

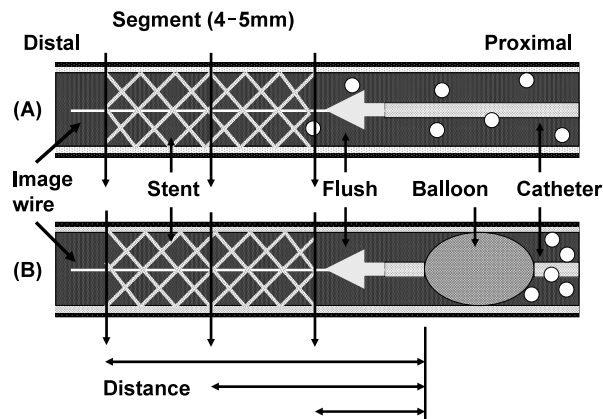
**OCT imaging methods**

In order to remove blood from the field of view and allow clear visualization of the vessel wall, OCT images were recorded during liquid substance flushes at the proximal site of regions of interest. To examine the optimal imaging methods, two methods were compared: flush alone (FA) using small catheter and flush with occlusion (FO) using small catheter with balloon (Fig. 1). For the FA method, a 5F straight catheter (Goodman Corp.) was used.

For the FO method, three catheters were available: a 5F catheter with balloon, the modified endoscope catheter (both Clinical Supply Inc.), a percutaneous transluminal angioplasty balloon catheter (Cordis Corp., Johnson and Johnson), and a balloon catheter that was under development for OCT (LightLab, Inc.). The appropriate catheter was selected based on vessel size and/or position of the target region. The flush material used was saline or a mixture of saline (50%) with a contrast agent (50%). The flush agents were injected manually. The average flow of flush agents was calculated as total amount of agents divided by imaging time. OCT images were acquired at all stented regions.

**IVUS imaging and analysis**

IVUS was performed immediately after stent implantation with a 2.5 F, 40-MHz single-element



**Fig. 1** Diagnosis showing the two methods to displace blood with flush agents for optical coherence tomography image acquisition

*A:* Flush alone using small catheter. Some blood cells could inflow into the target region.

*B:* Flush with occlusion using small catheter with balloon. After inflating the balloon, flush agent was injected. Many blood cells could not inflow into the target region. To investigate factors that could influence image quality, the stented region was divided into 4 - 5 mm segments. In each segment, distance from distal end of occlusion system to target segment was measured.

mechanical ultrasound catheter( Atlantis Pro, Boston Scientific Inc. ) IVUS was performed with motorized pullback devices at a rate of 1.0 mm/sec. All IVUS images were recorded on s-VHS videotape for offline analysis. Quantitative IVUS analysis was performed using commercially available planimetry software( TapeMeasure, Indec Inc. Mountain View ) Implanted stent length was measured at all stented regions.

#### Interpretation of OCT and IVUS images

Two well-trained observers reviewed all OCT and IVUS images. The methods of OCT image interpretation were based on previous reports<sup>1</sup>. Adequate image acquisition was defined as the entire circumferential intimal layer being detectable within a continuous segment( **Figs. 2 - C, D, F** ) In addition, almost adequate image acquisition was defined as visualization of > 75% intimal circumference. The optimal visualization was compared between OCT and IVUS images throughout the length of all stents. To investigate factors that could influence image quality, the stented region was divided into 4 - 5 mm segments. Target external elastic membrane diameter, distance from distal end of occlusion system to target segment, position

of image wire, side branch existence, and the degree of blood removal were examined at each segment( **Figs. 1, 2 - G, I** ) The target external elastic membrane diameter was calculated at the largest point within the segment, using the OCT image. However, if measurements could not be done due to poor OCT images, the IVUS image was used. The position of the image wire was defined as follows: center( image wire located closer to the lumen center than to the inner intimal border ), or not center( image wire located closer to the inner intimal border than to the lumen center ) ( **Figs. 2 - H, J** ) All side branches  $\geq 1.0$  mm in diameter were detected at each segment and listed by the diameter. Blood removal was classified into four stages: complete blood removal, partial blood flow with no problem for image interpretation, partial blood flow with problem for image interpretation, and blood removal failure.

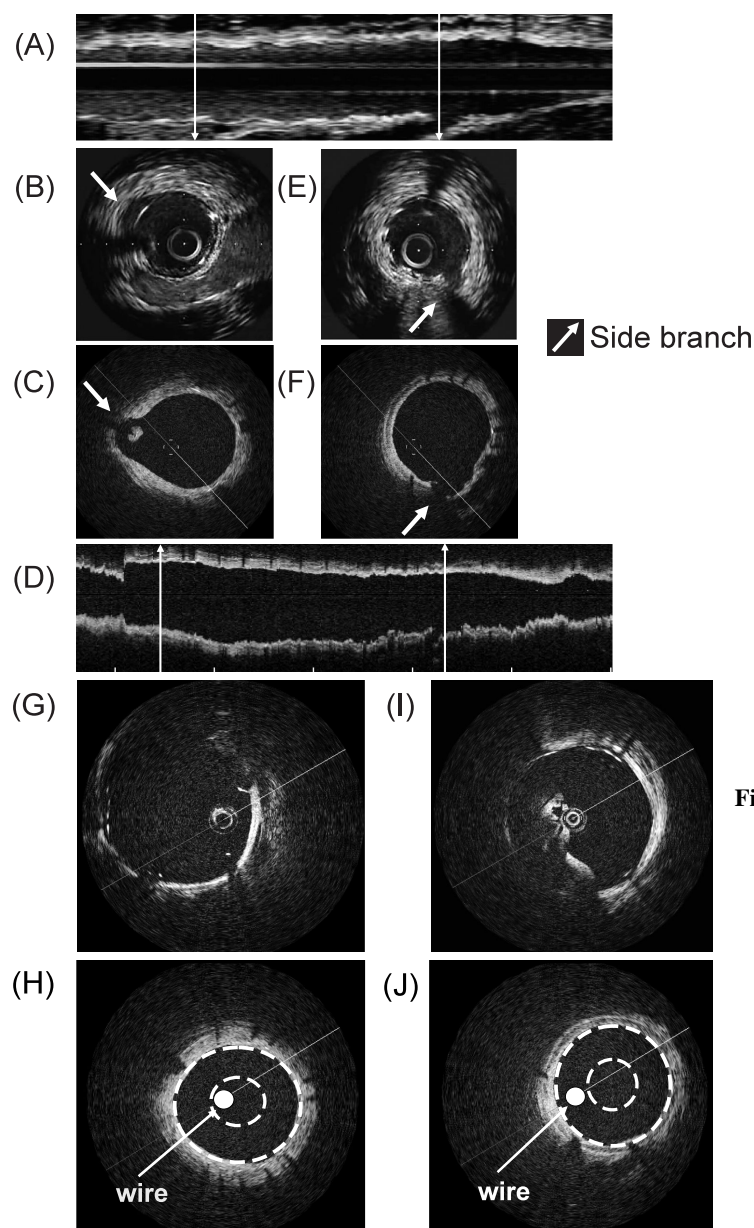
#### Statistical analysis

Quantitative data are presented as mean  $\pm$  SD, and qualitative data are presented as frequencies. Statistical analyses were performed with the StatView 5.0 software( SAS Institute ) For comparisons of continuous variables, the two-tailed unpaired *t*-test was used. Categorical data were compared with the chi-square or Fisher's exact test. Univariate and multivariate logistic regression analyses were used for the detection of independent predictors for adequate image acquisition. Statistical significance was defined as a threshold of  $p = 0.05$ .

## RESULTS

#### Optimal OCT image acquisition methods and flush agents

The two blood removal methods, FA and FO, were compared within OCT images of the same 24 segments in 6 stented regions. The FO method provided a high frequency of adequate image acquisition compared to the FA method ( FO : 60.9% vs FA : 8.7%,  $p = 0.0002$ ; **Fig. 3** ). In addition, the average observed continuous adequate image was longer in FO than FA( FO : 12.7 mm vs FA : 2.3 mm,  $p = 0.047$  ). The two types of flush agents were also compared, 1 ) saline and 2 ) mixture of saline( 50% ) and contrast agent( 50% ) in the 15 same stented regions using the FO method. Adequate images were acquired with both flush



**Fig. 2** Representative intravascular ultrasound (A, B, E) and optical coherence tomography (C, D, F) images recorded from the same left femoral artery

Cross-sectional images were obtained at identical arrow line points between intravascular ultrasound and optical coherence tomography (B and C; E and F, respectively). C and F are examples of adequate optical coherence tomography cross-sectional image acquisition.

G and I are examples of inadequate images. The wire position and large vessel size were responsible for the inadequate images in G, and incomplete blood removal in I. H is an example of wire center position, and J is an example of not center.

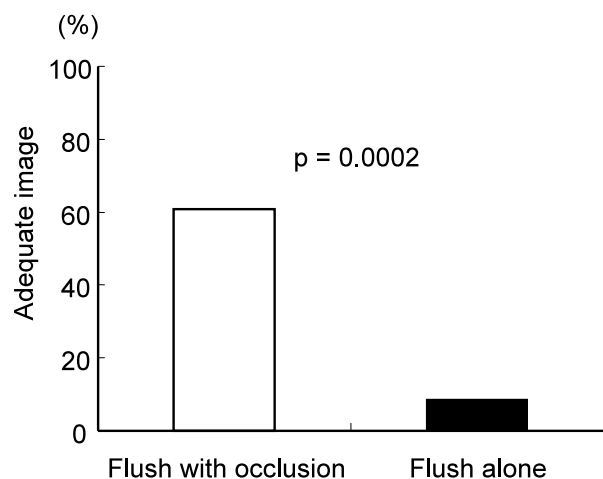
agents (saline: 60.0% vs mixture: 44.5%,  $p = 0.190$ ). After these analyses, the FO technique was used for all OCT imaging, using saline as the flush agent.

#### Imaging analysis

The average vessel diameter of the 39 stented arteries was  $4.02 \pm 0.66$  mm, with a stent diameter of  $3.24 \pm 0.77$  mm and stent length of  $18.14 \pm 5.80$  mm. Within all stented regions, adequate length of continuous OCT imaging was detected, so the optimal imaging rate was then calculated as adequate OCT imaging length divided by real stent

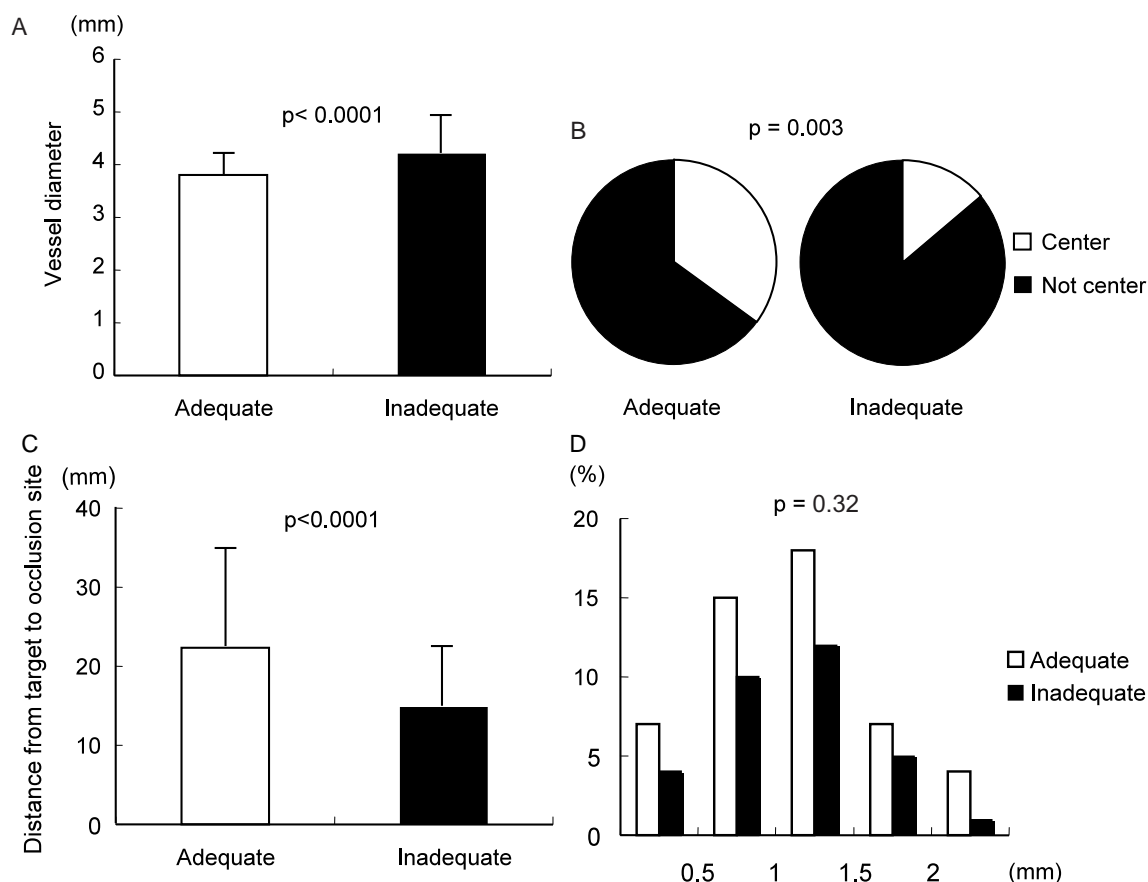
length. Using the FO method, the rate of adequate image acquisition was 64.4% and visualization of > 75% intimal circumference was 83.5%. Using IVUS, the rate was 100%. The average continuous imaging length was 11.2 mm, with average flow of flush agents of 0.85 ml/sec.

A total of 144 segments were imaged in 39 stents. The segments were divided into two categories, adequate OCT image acquisition ( $n = 71$ ) and inadequate OCT image acquisition ( $n = 73$ ). More optimal imaging was detected when the vessel was smaller (adequate segment:  $3.8 \pm 0.4$  mm, inadequate segment:  $4.2 \pm 0.8$  mm,  $p < 0.0001$ ;



**Fig. 3** Comparison of adequate image acquisition between flush with occlusion and flush alone methods.

**Fig. 4 - A** ). Furthermore, more adequate images were detected when the OCT wire was centered within the vessel (adequate segment: center 35%, inadequate segment: center 14%,  $p = 0.003$ ; **Fig. 4 - B** ). The distance from the distal end of occlusion system to the target segment was greater in adequate segments, compared to inadequate segments (adequate segment:  $22.3 \pm 12.2$  mm, inadequate segment:  $14.8 \pm 7.4$  mm,  $p < 0.0001$ ; **Fig. 4 - C** ). However, side branches in the segment did not affect the image acquisition. Between both segments, there was no significant difference in side branch existence (adequate segment: side branch 25%, inadequate segment: side branch 14%,  $p = 0.08$ ; **Fig. 4 - D** ). In addition, more adequate images were observed in sufficient blood removal segments than insufficient segments (complete removal: 70%, partial with no problem: 23%, partial with problem: 7%, failure: 0%,  $p = 0.03$  ).



**Fig. 4** Factors affecting image acquisition

- A: Comparison of average vessel diameter between adequate and inadequate image segments.
- B: Comparison of wire position between adequate and inadequate image segments.
- C: Comparison of distance from the distal end of occlusion system to target segment between adequate and inadequate image segments.
- D: Distribution of the number and size of side branches between adequate and inadequate image segments.

**Table 1 Univariate and multivariate regression analysis: adequate image acquired rate stratified by target vessel characteristics**

Variable	Odds ratio	95% confidence interval	p value
Univariate regression analysis			
Vessel size	0.377	0.209 - 0.678	0.001
Distance from target to occlusion site	1.077	1.035 - 1.120	0.001
Wire center position	0.333	0.148 - 0.748	0.008
Blood removal	2.562	1.278 - 5.138	0.008
Side branch	1.902	0.819 - 4.415	0.135
Multivariate regression analysis			
Vessel size	0.203	0.079 - 0.523	0.001
Distance from target to occlusion site	1.071	1.026 - 1.118	0.002
Wire center position	0.239	0.085 - 0.669	0.006

**Table 2 Complications: optical coherence tomography**

Artery	Imaging procedure	ST change	Vessel injury	Arrhythmia	Death
Coronary	52	9( 17.3% )	0	5( 7.7% )	1( 1.9% )
Peripheral	406	0	0	0	0
Total	458	9( 2.0% )	0	5( 1.1% )	1( 0.2% )

**Table 3 Complications: arrhythmia due to optical coherence tomography**

Case	Arrhythmia	Coronary	Catheter used
1	Ventricular fibrillation	Left circumflex	Endoscope
2	Ventricular fibrillation	Left circumflex	Balloon
3	Ventricular fibrillation	Right coronary artery	Endoscope
4	Ventricular fibrillation	Right coronary artery	Balloon
5	Bradycardia	Right coronary artery	Balloon

Balloon: Balloon catheter under development for optical coherence tomography. Endoscope: Modified endoscope catheter.

**Figs. 2 - A - F** shows representative OCT and IVUS images at the same stented artery.

Univariate analysis of target vessel characteristics related to adequate image acquisition is shown in **Table 1**. Vessel size, wire position, distance from target to occlusion site, and blood removal were significant factors for adequate image acquisition. Multivariate logistic regression analysis is shown in **Table 1**. Wire position, vessel size, and distance from target to occlusion site were all independent predictors.

#### Safety during imaging procedure

There were few complications using OCT imaging in this study( **Tables 2, 3** ). There were no adverse effects( 0% )among 406 peripheral OCT

imaging procedures. The most frequently encountered event among 52 coronary OCT procedures was ischemic ST segment change on the electrocardiogram after flushing material into the coronary artery following proximal occlusion. The major adverse events were: one death caused by ventricular fibrillation( 1.9% ), three ventricular fibrillations ( 5.8% )and one bradycardia( 1.9% ). Except for the one death, the other arrhythmias were successfully treated. In addition, after OCT imaging, there was no dissection or irreversible spasm at the occlusion site, and no dissection caused by flush agents, confirmed by angiography or IVUS.

#### DISCUSSION

Compared to other vascular imaging modalities,

OCT has the potential for precise investigation of atherosclerosis severity, and can identify plaque composition, rupture, and vulnerability with the detection of lipid pool or thin fibrous cap. The advantages of OCT are mainly due to its high-resolution imaging capacity (approximately 10 to 20  $\mu\text{m}$ ). However, since infrared light is reflected by blood cells, the OCT light cannot reach the target without blood removal. Thus, clear continuous longitudinal visualization using OCT requires constant blood displacement with flush agents. This study provides the first evidence that an optimized OCT imaging method enables continuous complete vessel examination of  $\geq 60\%$  and almost complete examination of  $\geq 80\%$  of target segments.

### Optimal imaging methods and safety

In this study, two OCT imaging methods were compared, either flush with occlusion or flush alone. The flush with occlusion method was superior to remove the blood, which contributed to 7 times longer continuous imaging compared to flush alone. Previous animal and clinical studies reported that the duration of continuous OCT imaging was approximately 2 - 3 sec, using the FA method<sup>1,5</sup>). Compared to previous results, this optimized imaging method shows the possibility of whole vessel detection by OCT.

In the segmental study, adequate OCT image acquisition was achieved when the target vessel was smaller or with the centered image wire position, which was probably attributable to the penetration depth of OCT image light. These results correspond to those of previous clinical OCT studies<sup>3,5</sup>). In the near future, the development of high penetration light source and image wire centering systems, similar to intracoronary radiation therapy, will overcome this limitation. In addition, side branches at the target segment seemed to interrupt blood removal. However, in this study, the existence of side branches did not influence the image acquisition, even with low flow rates of flush agents (0.85 ml/sec). For this reason, it appears that stented segments had no stenosis and collateral flow. One possible explanation is that the optimal proximal occlusion and flush prevented any inflow from both distal and proximal side branches. Furthermore, at relatively far segments from the occlusion site, optimal images were acquired compared to those from closer segments. Possible explanations for this result include: more proximal

vessel sites may be larger in size, resulting in insufficient balloon occlusion or weak light reflection beyond the penetration depth of OCT light; or the concentration of flush agents might be higher at distal segments than proximal segments. As the regression analysis showed, vessel size and wire position were independent factors for optimal imaging, but blood removal was not. This suggests that the image light penetration depth might influence the image acquisition after sufficient blood removal.

However, the FO method may potentially produce several clinical problems. One involves the relatively long ischemic time downstream of the target artery, especially for the coronary artery, compared to the FA method. In this study, only one animal died following ventricular fibrillation after balloon inflation in the left circumflex coronary artery. The ventricular fibrillation was probably due to left main coronary artery occlusion for image detection of the proximal left circumflex segment. In this case in particular, we performed numerous long time balloon inflations. After this case, the inflation time was shortened, and repeated balloon inflation and left main occlusion were avoided. As a result, there were no more deaths in this study. Moreover, the percentage of ventricular fibrillation or tachycardia (5.8%) was high compared to clinical angiography using the same flush with occlusion method (0.3 - 1.4%)<sup>1</sup>). On the other hand, in OCT imaging with flush alone methods, no life-threatening arrhythmia was reported in 10 human coronary cases. Porcine coronary artery ischemia is more prone to cause life-threatening events compared to human coronary artery ischemia. Accordingly, in the clinical setting, arrhythmia following distal ischemia might not become an important problem, compared with the porcine experiments.

Another concern was vessel injury at the occlusion site or injury caused by flush agents. In this study, to decrease vessel injury, minimal balloon inflation pressure was tested at each vessel, and then sufficient occlusion was confirmed by contrast injection. Furthermore, the flow of flush agents (0.85 ml/sec) was slow, compared to previous clinical studies using the single pouring flush agent method (8 - 10 ml)<sup>3,5</sup>), suggesting the need to investigate the optimal flow of flush agents using the auto injector. Consequently, this study did not reveal any adverse effects at the occlusion site or flushing zone except for reversible vascular spasm.



### Clinical implication

This study reports an optimal method for continuous OCT imaging that might allow whole vessel examination. This finding will contribute to several clinically relevant issues. First, continuous OCT imaging will evolve to become guidance for vascular intervention, including vessel size or lesion length, similar to IVUS. Second, detection of vulnerable plaque or macrophages within the plaque of the entire coronary artery system could lead to the prevention of coronary artery disease or further examination of atherosclerosis<sup>8,9</sup>). Finally, detailed intimal examination following drug-eluting stent implantation will provide pivotal evidence, as late thrombosis and re-endothelialization are still important issues in this drug-eluting stent era<sup>10</sup>). In this study, the optimal imaging method enabled much improved continuous long time OCT detection. In the near future, more advanced OCT systems equipped with high-speed image wire rotation, well-developed occlusion devices, and special flush agents protecting the myocardium will contribute to shorter imaging time, adequate blood removal, and prevention of distal ischemia, resulting in an intravascular OCT imaging system with greater patient safety and providing invaluable intravascular data.

### Limitations

The results of this study should be interpreted within the context of several limitations. First, all

data of this study were obtained in an animal model, which might not correspond to the human clinical setting completely. Second, inadequate images were obtained at adequate blood removal sites probably due to the large target vessel or not centralized wire position, or possibly target vessels involving peripheral arteries (29/39; 74%). Third, the injection method of flush agents should be investigated using an auto regulated injector for the analysis of optimal image acquisition. Finally, even this optimized OCT imaging method could not offer complete continuous visualization compared to IVUS. Thus, further investigation with more advanced OCT systems should be conducted in the near future.

### CONCLUSIONS

To acquire continuous adequate OCT imaging, the flush with occlusion method was more effective compared to flush alone. Moreover, image quality might be affected by vessel size and position of the image wire. These results suggest that an optimized OCT imaging method could provide continuous vessel detection.

### Acknowledgments

We thank Heidi N. Bonneau, RN, MS (Highlands Consulting Inc.) for her expert review of the manuscript, and Dr. Tetsuaki Li Tanimura (LightLab Inc.) and Mr. Toru Ohashi (Goodman Corp.) for their experimental support.

## 要 約

### Optical Coherence Tomographyによる血管内連続観察方法の検討

浅輪浩一郎 片岡 亨 小林 芳樹 長谷川隆生 西岡 弘樹  
山下 啓 邱 朝暉 江原 省一 広瀬 真 紙森 公雄  
島田 健永 葭山 稔 吉川 純一

目 的: Optical coherence tomography (OCT)は高度画像分解能を有する血管内イメージング法である。しかし、有効な画像を得るためには血液を排除しなければならず、連続観察の方法はいまだ確立されていない。本研究の目的は血管内を連続観察するための至適方法を検討することである。

方 法: ミニブタ14頭における下肢動脈(24本)と冠動脈(10本)の34血管にステントを留置し、自動牽引装置を用いてOCTを施行した。主に生理食塩水によるフラッシュのみとバルーンによる血流遮断後にフラッシュする2つの方法を比較した。有効な画像は測定区間で常に全周内膜観察可能であることとした。使用したステント長が異なるため、4-5mmのセグメントに分割し、有効な画像の獲得に影響を与える因子を検討した。

結 果: 血流遮断後にフラッシュする方法ではフラッシュのみの方法と比べ有効な画像が得られた(フラッシュ+血流遮断: 60.9%, フラッシュ単独: 8.7%,  $p = 0.0002$ )。血流遮断後にフラッシュ



する方法では良好な画像は64.4%の割合で得られ、セグメントごとの観察では小さな血管においてより有効な画像が得られ(有効画像セグメント:  $3.8 \pm 0.4\text{mm}$ , 無効画像セグメント:  $4.2 \pm 0.8\text{mm}$ ,  $p < 0.0001$ ), またワイヤーが中心にあるほうが有効な画像が得られた(有効画像セグメント: 中心部35%, 無効画像セグメント: 中心部14%,  $p = 0.003$ ). しかし側枝は画像には影響を与えなかった.

結論: 有効な連続画像を得るためには, 血流を遮断しながらフラッシュする方法がフラッシュのみの方法と比べ効果的であった. 有効な画像の獲得は血管径とワイヤーの位置に影響を受けることが示唆された.

—J Cardiol 2006 Mar; 47(3): 133 - 141—

## References

- 1) Jang IK, Bouma BE, Kang DH, Park SJ, Park SW, Seung KB, Choi KB, Shishkov M, Schlendorf K, Pomerantsev E, Houser SL, Aretz HT, Tearney GJ: Visualization of coronary atherosclerotic plaques in patients using optical coherence tomography: Comparison with intravascular ultrasound. *J Am Coll Cardiol* 2002; **39**: 604 - 609
- 2) Fitzgerald PJ, St Goar FG, Connolly AJ, Pinto FJ, Billingham ME, Popp RL, Yock PG: Intravascular ultrasound imaging of coronary arteries: Is three layers the norm? *Circulation* 1992; **86**: 154 - 158
- 3) Tearney GJ, Jang IK, Kang DH, Aretz HT, Houser SL, Brady TJ, Schlendorf K, Shishkov M, Bouma BE: Porcine coronary imaging in vivo by optical coherence tomography. *Acta Cardiol* 2000; **55**: 233 - 237
- 4) Yabushita H, Bouma BE, Houser SL, Aretz HT, Jang IK, Schlendorf KH, Shishkov M, Kang DH, Halpern EF, Tearney GJ: Characterization of human atherosclerosis by optical coherence tomography. *Circulation* 2002; **106**: 1640 - 1645
- 5) Bouma BE, Tearney GJ, Yabushita H, Shishkov M, Kauffman CR, DeJoseph Gauthier D, MacNeill BD, Houser SL, Aretz HT, Halpern EF, Jang IK: Evaluation of intracoronary stenting by intravascular optical coherence tomography. *Heart* 2003; **89**: 317 - 320
- 6) Brezinski M, Saunders K, Jesser C, Li X, Fujimoto J: Index matching to improve optical coherence tomography imaging through blood. *Circulation* 2001; **103**: 1999 - 2003
- 7) Feld S, Ganim M, Carell ES, Kjellgren O, Kirkeeide RL, Vaughn WK, Kelly R, McGhie AI, Kramer N, Loyd D, Anderson HV, Schroth G, Smalling RW: Comparison of angioscopy, intravascular ultrasound imaging and quantitative coronary angiography in predicting clinical outcome after coronary intervention in high risk patients. *J Am Coll Cardiol* 1996; **28**: 97 - 105
- 8) MacNeill BD, Jang IK, Bouma BE, Iftimia N, Takano M, Yabushita H, Shishkov M, Kauffman CR, Houser SL, Aretz HT, DeJoseph D, Halpern EF, Tearney GJ: Focal and multi-focal plaque macrophage distributions in patients with acute and stable presentations of coronary artery disease. *J Am Coll Cardiol* 2004; **44**: 972 - 979
- 9) Tearney GJ, Yabushita H, Houser SL, Aretz HT, Jang IK, Schlendorf KH, Kauffman CR, Shishkov M, Halpern EF, Bouma EF: Quantification of macrophage content in atherosclerotic plaques by optical coherence tomography. *Circulation* 2003; **107**: 113 - 119
- 10) McFadden EP, Stabile E, Regar E, Cheneau E, Ong AT, Kinnaird T, Suddath WO, Weissman NJ, Torguson R, Kent KM, Pichard AD, Satler LF, Waksman R, Serruys PW: Late thrombosis in drug-eluting coronary stents after discontinuation of antiplatelet therapy. *Lancet* 2004; **364**: 1519 - 1521