

## Preventive Effect of an Antiallergic Drug, Pemirolast Potassium, on Restenosis After Stent Placement: Quantitative Coronary Angiography and Intravascular Ultrasound Studies

Hidefumi OHSAWA, MD, FJCC  
Hirofumi NOIKE, MD  
Masahito KANAI, MD  
Takashi HITSUMOTO, MD  
Kaneyuki AOYAGI, MD  
Takeshi SAKURAI, MD  
Yuhkoh SUGIYAMA, MD  
Kunio YOSHINAGA, MD  
Michihisa KAKU, MD  
Jun MATSUMOTO, MD  
Takuo IIZUKA, MD  
Kazuhiro SHIMIZU, MD  
Mao TAKAHASHI, MD  
Takanobu TOMARU, MD  
Hiroshi SAKURAGAWA,

MD

### Abstract

**Objectives.** The preventive effect of pemirolast against restenosis after coronary stent placement was evaluated.

**Methods.** Eighty-four patients with 89 de novo lesions who underwent successful coronary stenting were assigned to the pemirolast group (40 patients, 45 lesions) and the control group (44 patients, 44 lesions). Administration of pemirolast (20 mg/day) was initiated from the next morning after stenting and continued for 6 months of follow-up. Quantitative coronary angiography was performed immediately after stenting and at follow-up. Angiographic restenosis was defined as diameter stenosis  $\geq 50\%$  at follow-up. Intravascular ultrasound study conducted at follow-up angiography was used to measure vessel cross-sectional area (CSA), stent CSA, lumen CSA, neointima CSA (stent CSA - lumen CSA), and percentage neointima CSA (neointima CSA/stent CSA  $\times 100\%$ ) at the minimal lumen site.

**Results.** There were no significant differences in baseline characteristics between the two groups. Restenosis rate was significantly lower in the pemirolast group than in the control group (15.0% vs 34.1% of patients, 13.3% vs 34.1% of lesions,  $p < 0.05$ , respectively). The intravascular ultrasound study at follow-up (36 lesions in the pemirolast group, 33 in the control group) found no significant differences in vessel CSA and stent CSA between the two groups ( $17.3 \pm 2.2$  vs  $16.8 \pm 2.4$  mm<sup>2</sup>,  $8.6 \pm 1.9$  vs  $8.4 \pm$

東邦大学医学部付属佐倉病院 循環器センター：〒285-0841 千葉県佐倉市下志津564-1  
Cardiovascular Center, Sakura Hospital, Toho University School of Medicine, Chiba

**Address for correspondence:** OHSAWA H, MD, FJCC, Cardiovascular Center, Sakura Hospital, Toho University School of Medicine, Shimoshizu 564-1, Sakura, Chiba 285-0841

Manuscript received November 15, 2002; revised January 8 and March 31, 2003; accepted March 31, 2003

1.7 mm<sup>2</sup>, respectively). However, lumen CSA was significantly larger in the pemirolast group than in the control group (5.5 ± 1.3 vs 4.4 ± 1.1 mm<sup>2</sup>,  $p < 0.05$ ). Moreover, neointima CSA and percentage neointima CSA were significantly smaller in the pemirolast group (3.1 ± 1.1 vs 4.0 ± 1.2 mm<sup>2</sup>,  $p < 0.05$  and 36.2 ± 15.9% vs 47.4 ± 15.6%,  $p < 0.01$ ).

**Conclusions.** Pemirolast has a preventive effect against restenosis after stent placement, possibly by inhibiting neointimal hyperplasia.

*J Cardiol 2003 Jul; 42(1): 13-22*

## Key Words

■ Intravascular ultrasound    ■ Coronary artery disease    ■ Prevention (restenosis)  
 ■ Drug therapy (pemirolast potassium)    ■ Stent

## INTRODUCTION

Coronary restenosis remains a major limitation of percutaneous coronary intervention (PCI) and has become a major complication in developed countries. Stenting has reduced restenosis by preventing pathologic vascular remodeling<sup>1,2</sup>, but the proliferation of vascular smooth muscle cells, one of the causes of restenosis, is commonly observed after stent placement<sup>3</sup>. Almost 80% of contemporary PCI procedures are performed with the use of coronary stents, so strategies aimed at eradicating neointimal hyperplasia are a current focus of research.

We previously found that pemirolast potassium<sup>4-8</sup>, an antiallergic agent, markedly inhibits migration and proliferation of vascular smooth muscle cells<sup>9</sup>. Pemirolast inhibits intimal hyperplasia in animal experiments<sup>10</sup>. Furthermore, we recently confirmed that pemirolast prevents coronary restenosis after plain old balloon angioplasty (POBA)<sup>11</sup> by the mechanism of inhibiting neointimal hyperplasia rather than pathological remodeling, as shown by angiographic and intravascular ultrasound (IVUS) studies<sup>12</sup>.

The present clinical prospective randomized study investigated the preventive effect of pemirolast on restenosis after coronary stent placement.

## SUBJECTS AND METHODS

### Study population

This study included 88 patients with symptomatic ischemic heart disease due to de novo lesions of the native coronary artery treated between January 1998 and March 1999. Patients with acute myocardial ischemia, left ventricular ejection fraction of ≤ 40% or renal failure were excluded. The angiographic criteria for exclusion were the presence of type C lesions<sup>13</sup> such as chronic total occlusions (≥ 3 months old), ostial lesions, left main

trunk lesions, lesions in coronary vessels of < 2.5 mm caliber and diffuse lesions requiring 2 or more stents. Coronary stenting was performed in patients with suboptimal results such as dissection or elastic recoil immediately after balloon angioplasty. The general exclusion criteria for stenting were contraindications for anticoagulant and antiplatelet therapies.

Before the study, a thorough explanation was given to patients and their families about the potential risks and benefits involved in this study, and written informed consent was obtained. The patients were assigned to the group receiving pemirolast (pemirolast group), or the group not receiving pemirolast (control group) by the prospective randomization technique.

### Drug treatments

The pemirolast group received pemirolast (20 mg/day), the standard dose as an antiallergic drug, from the morning after stenting until follow-up angiography at 6 months. All patients in both groups received aspirin (162 mg/day) and ticlopidine (200 mg/day) from 1 week before the procedure until the time of follow-up angiography. Drugs for treating complications such as hypertension, hyperlipidemia, and diabetes mellitus were used at the discretion of attending physicians, but the use of other antiallergic drugs was prohibited.

### Stent implantation

Immediately before PCI, patients received an initial bolus injection of heparin (8,000 to 10,000 U) and intracoronary administration of 200 µg nitroglycerin. PCI was performed by POBA, followed by implantation of stents. Either a slotted tube stent (Palmaz-Schatz) or a coil stent (Wiktor or gfx) was selected according to the lesion characteristics and coronary vessel morphology. The Palmaz-Schatz stent was placed either by the stent delivery system

or was mounted on the balloon used for pre-dilation. After successful stent delivery, balloon dilation at high pressure was added to achieve the optimal result, which was defined as residual stenosis of less than 10% of the luminal diameter without complications ( death, myocardial infarction, coronary artery bypass surgery ). Heparin and nitroglycerin infusions were continued for 24 hours after stenting.

### Follow-up

All treated patients were monitored for at least 6 months. Adverse effects attributable to pemirolast were monitored at fixed periods ( 1 day, 2 weeks, 1 month, 3 months and 6 months after the procedure ) by interview as well as laboratory examinations. IVUS measurements and follow-up coronary angiography were conducted 6 months after stenting. If ischemic symptoms recurred within 6 months after stenting, coronary angiography was performed earlier. If no definite restenosis was found, follow-up angiography was repeated 6 months later.

### Quantitative coronary angiography

Coronary angiograms obtained before, immediately after, and at 6 months after stenting, were reviewed by an unbiased angiographer without knowledge of group randomization. For quantitative analysis, end-diastolic cine-frames were selected from the angiographic views demonstrating the maximal degree of stenosis and were matched before, immediately after and at follow-up. The selected cine-frames were digitalized with a cine-video converter, and were analyzed using a quantitative coronary angiography system ( Heart analysis database system, Medical Soft Support Center Corp. ). The guiding and diagnostic catheters were used as the calibration standard to measure the reference diameter, minimal lumen diameter and percentage diameter stenosis. Acute gain was defined as the increase in minimal lumen diameter immediately after stenting, late loss as the decrease in minimal lumen diameter at follow-up ( post-procedure minimal lumen diameter minus follow-up minimal lumen diameter ), and net gain as the difference between acute gain and late loss. The loss index was the ratio of late loss to acute gain. Angiographic restenosis was defined as stenosis of  $\geq 50\%$  diameter at the end of follow-up.

### Quantitative intravascular ultrasound

IVUS study was performed at follow-up angiography. IVUS examinations were performed with a 30-MHz, 3.2 F mechanical ultrasound catheter ( Boston Scientific, UltraCross ) and were always preceded by intracoronary administration of nitroglycerin ( 0.1 mg ). The IVUS catheter was advanced distal to the stenting site and then was manually pulled back. The ultrasound images were recorded onto super-VHS videotape for off-line analysis, with a detailed running audio commentary describing the location of the ongoing IVUS interrogation. Moreover, some angiographic images were recorded during pullback so that the location of the IVUS transducer was known.

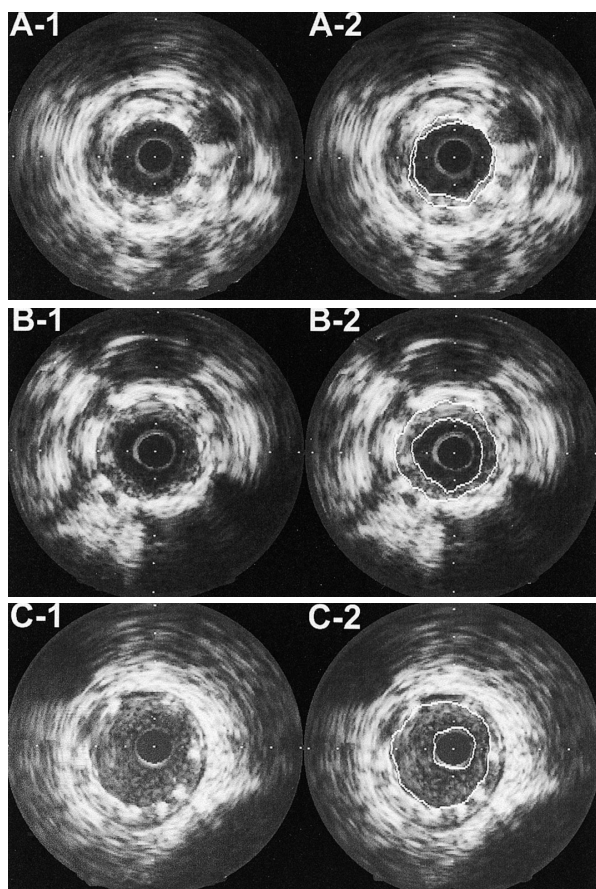
Angiographic and IVUS data were analyzed side by side. First, stent cross-sectional area ( CSA ), lumen CSA, neointima CSA ( stent CSA - lumen CSA ) and percentage neointima CSA ( neointima CSA / stent CSA  $\times 100\%$  ) were measured on a cross-sectional image with the minimal lumen ( Fig. 1 ). Second, the mean data of these parameters were calculated and were compared between the pemirolast group and the control group.

### Statistical analysis

Student's *t*-test was used to assess differences in continuous variables between the two groups. The results are expressed as mean  $\pm$  SD. Categorical variables, which are presented as rates, were compared by the chi-square test. Statistical significance was defined as  $p < 0.05$ .

## RESULTS

Four of the 88 patients were excluded because of deviation from the protocol ( 2 patients in the pemirolast group ), or lack of follow-up angiography ( 1 patient in each group ). During follow-up, neither symptoms nor significant aggravation of laboratory findings attributable to pemirolast were observed in the pemirolast group. Thus, the final angiographic study group contained 84 patients ( 89 lesions ), with 40 patients ( 45 lesions ) in the pemirolast group and 44 patients ( 44 lesions ) in the control group. Baseline clinical characteristics are shown in **Table 1**, and baseline angiographic and procedure-related characteristics are shown in **Table 2**. There were no significant differences in baseline characteristics between the two groups.



**Fig. 1 Quantitative intravascular ultrasound measurements at follow-up**

Case A (46-year-old, male, pemirolast group): Palmaz-Schatz stent 3.0 mm.

A-1: Mild neointimal hyperplasia (no restenosis).

A-2: Stent CSA: 7.3 mm<sup>2</sup>, lumen CSA: 5.7 mm<sup>2</sup>, percentage neointima CSA: 21.9%.

Case B (53-year-old, male, control group): Palmaz-Schatz stent 3.5 mm.

B-1: Moderate neointimal hyperplasia (no restenosis).

B-2: Stent CSA: 9.3 mm<sup>2</sup>, lumen CSA: 5.3 mm<sup>2</sup>, percentage neointima CSA: 43.0%.

Case C (61-year-old, female, control group): Palmaz-Schatz stent 3.5 mm.

C-1: Severe neointimal hyperplasia (restenosis).

C-2: Stent CSA: 9.5 mm<sup>2</sup>, lumen CSA: 1.6 mm<sup>2</sup>, percentage neointima CSA: 83.2%.

CSA = cross-sectional area.

### Angiographic results

Luminal dimensions at baseline, immediately after stenting, and at follow-up are shown in **Table 3**. There were no differences between the two groups in baseline reference diameter and minimal lumen diameter. Immediately after stenting, there were no differences in minimal lumen diameter and

acute gain between the two groups. At follow-up, the pemirolast group had a smaller mean reduction in minimal lumen diameter (late loss:  $0.75 \pm 0.74$  vs  $1.17 \pm 0.92$  mm, loss index:  $0.33 \pm 0.29$  vs  $0.52 \pm 0.36$ ,  $p < 0.05$ , respectively) and larger net gain ( $1.50 \pm 0.72$  vs  $1.03 \pm 0.83$  mm,  $p < 0.05$ ), resulting in a larger minimal lumen diameter ( $2.11 \pm 0.72$  vs  $1.68 \pm 0.90$  mm,  $p < 0.05$ ). Restenosis rates were significantly lower in the pemirolast group than in the control group (patients: 15.0% vs 34.1%, lesions: 13.3% vs 34.1%,  $p < 0.05$ , respectively). In patients, restenosis of the Palmaz-Schatz stent in the pemirolast group was as low as 9.1%. There were no significant differences in the incidence of target lesion revascularization between the two groups (11.1% vs 27.3%).

### Intravascular ultrasound results

Twenty of the lesions investigated by follow-up angiography were not investigated by IVUS for the following reasons: The IVUS catheter failed to cross either at proximal or stenting sites because of proximal bend point or severe restenosis in 17 lesions (pemirolast group: 8, control group: 9), and the risk of IVUS study was too great in 3 lesions (pemirolast group: 1, control group: 2). Thus the IVUS study group contained 69 lesions, 36 lesions (restenosis in 4) in the pemirolast group and 33 lesions (restenosis in 9) in the control group.

Vessel CSA (pemirolast group:  $17.3 \pm 2.2$  vs control group:  $16.8 \pm 2.4$  mm<sup>2</sup>) and stent CSA ( $8.6 \pm 1.9$  vs  $8.4 \pm 1.7$  mm<sup>2</sup>) showed no differences between the two groups. Lumen CSA was significantly larger in the pemirolast group than in the control group ( $5.5 \pm 1.3$  vs  $4.4 \pm 1.1$  mm<sup>2</sup>,  $p < 0.05$ ). Moreover, neointima CSA and percentage neointima CSA were significantly smaller in the pemirolast group (neointima CSA:  $3.1 \pm 1.1$  vs  $4.0 \pm 1.2$  mm<sup>2</sup>,  $p < 0.05$ , percentage neointima CSA:  $36.2 \pm 15.9\%$  vs  $47.4 \pm 15.6\%$ ,  $p < 0.01$ ; **Fig. 2**).

### DISCUSSION

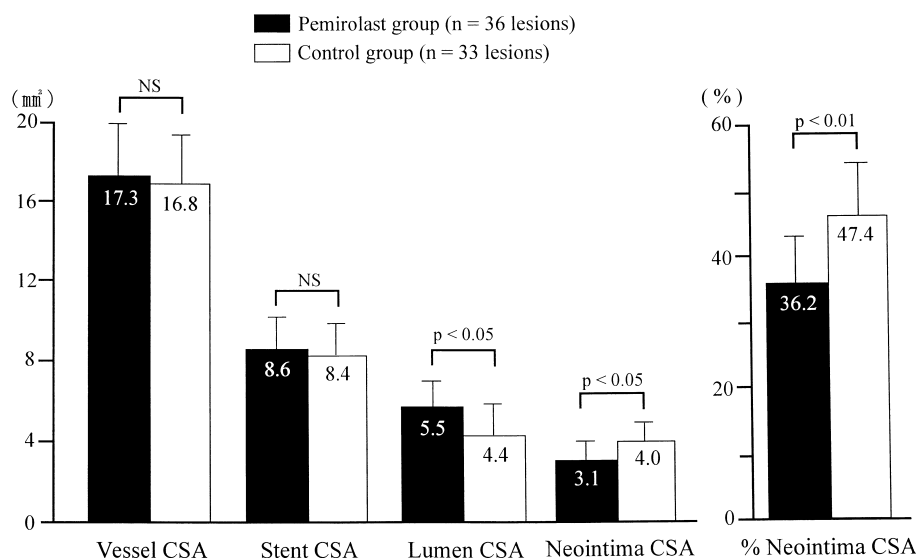
The techniques of PCI have changed from early POBA to more recent stenting, which can eliminate acute coronary occlusion and negative vascular remodeling. However, in-stent restenosis remains unresolved. In recent years, IVUS studies to examine the restenosis process following stent placement have determined that neointimal hyperplasia is



**Table 3** Quantitative coronary angiographic analysis

	Pemirolast group	Control group	<i>p</i> value
Number of lesions	45	44	
Reference diameter( mm )	3.01 ± 0.42	3.03 ± 0.25	NS
Minimal luminal diameter( mm )			
Pre stent	0.61 ± 0.28	0.65 ± 0.34	NS
Post stent	2.86 ± 0.28	2.93 ± 0.25	NS
Follow-up	2.11 ± 0.72	1.68 ± 0.90	< 0.05
Acute gain( mm )	2.25 ± 0.38	2.28 ± 0.39	NS
Late loss( mm )	0.75 ± 0.74	1.17 ± 0.92	< 0.05
Net gain( mm )	1.50 ± 0.72	1.03 ± 0.83	< 0.05
Loss index	0.33 ± 0.29	0.52 ± 0.36	< 0.05
<hr/>			
Patient restenosis( % of patients )	6/40( 15.0 )	15/44( 34.1 )	< 0.05
Lesion restenosis( % of lesions )	6/45( 13.3 )	15/44( 34.1 )	< 0.05
Tube stent( Palmaz-Schatz )	2/22( 9.1 )	8/26( 30.8 )	0.06
Coil stent( Wiktor or gfx )	4/23( 17.4 )	7/18( 38.9 )	NS
Target lesion revascularization( % of lesions )	5/45( 11.1 )	12/44( 27.3 )	NS

Continuous values are mean ± SD. ( ) %.



**Fig. 2** Quantitative intravascular ultrasound analysis of a cross-sectional image with the minimal lumen area at follow-up

Abbreviation as in Fig. 1.

solely responsible for in-stent restenosis<sup>3,14</sup>). Moreover, intimal hyperplasia is more common after stenting than POBA. Therefore, neointimal hyperplasia, or proliferation of vascular smooth muscle cells, must be prevented to avoid in-stent restenosis.

Previously, we confirmed by molecular biology study that the antiallergic agent, pemirolast,

markedly inhibits vascular smooth muscle cell proliferation induced by platelet-derived growth factor, angiotensin or endothelin. In addition, we found that pemirolast suppresses membrane inositol phospholipid turnover at an early stage of the intracellular signal-transduction system, suggesting that this is one of the mechanisms by which the agent inhibits vascular smooth muscle cell proliferation<sup>9</sup>).

Furthermore, our prospective randomized comparative study found that pemirolast reduces not only the angiographic restenosis rate but also late cardiac events after POBA<sup>11)</sup>. In addition, our IVUS study showed that pemirolast does not prevent vascular remodeling but does prevent neointimal hyperplasia in patients treated with POBA<sup>12)</sup>. These results suggest that pemirolast has pharmacological properties useful in preventing restenosis following PCI. Consequently, concomitant therapy by stenting with pemirolast may be more useful for preventing restenosis.

In the present study, the in-stent restenosis rate in the control group was 34.1% (Palmaz-Schatz stent: 30.8%, coil stent: 38.9%), which was slightly higher compared with the results of the BENESTENT<sup>1)</sup> and STRESS<sup>2)</sup> (22% and 31.6%). In our study, 41% of lesions were treated with coil stents, whereas only the Palmaz-Schatz stent was used in the BENESTENT and STRESS. On the other hand, the in-stent restenosis rate of the pemirolast group was 13.3% (Palmaz-Schatz stent: 9.1%, coil stent: 17.4%), which was significantly lower than that of control group (13.3% vs 34.1%). These angiographic results strongly suggested the preventive effect of pemirolast against restenosis. Moreover, the IVUS study found no difference in vessel area or stent area at the follow-up stage between the two groups. However, the lumen area was significantly larger, and the neointima area and percentage neointima area were significantly smaller in the pemirolast group. These results suggest that pemirolast has clinical effectiveness to inhibit the proliferation of vascular smooth muscle cells.

The exact mechanisms by which pemirolast inhibits vascular smooth muscle cell proliferation after stenting are not known. In-stent restenoses result from excessive fibroproliferative and inflammatory responses to insults to the arterial wall<sup>15,16)</sup>. Growth factors, cytokines and vasoregulatory molecules trigger the proliferation of vascular smooth muscle cells<sup>17)</sup>. In-stent lesions contain macrophages, histiocytes, eosinophils and T lymphocytes<sup>15,16)</sup>. Immunocomponent cells are predominantly detected around stent struts, which suggests a local immune response and inflammatory reaction to foreign material<sup>15)</sup>. Therefore, the inflammatory response and development of restenosis may be increased by a contact-allergic reaction to metal compounds released from stainless-steel stents. Recently, a delayed hypersensitivity reaction to

nickel and molybdenum was proposed as a triggering factor in in-stent restenosis<sup>18)</sup>. Therefore, pemirolast may inhibit this contact-allergic reaction to metal compounds released from stainless-steel stents. However, the mechanism still remains unexplained, since the association between allergic reactions to stent components and the occurrence of in-stent restenosis was not investigated in our study. If this hypothesis is correct, preprocedural administration of pemirolast may be likely to be more effective than postprocedural administration. Another possibility is that pemirolast may inhibit the activity of mast cells which secrete an angiotensin-forming enzyme, namely chymase<sup>19, 21)</sup>. Experimental studies have shown that angiotensin promotes the proliferation of vascular smooth muscle cells and extracellular matrix<sup>22,23)</sup>. Injury to the intima of the carotid artery in dogs leads to an increase in the number of mast cells in the adventitia and fibrotic outgrowth as well as intimal hyperplasia. Moreover, an increase in angiotensin level and a chymase level exceeding the angiotensin-converting enzyme level were demonstrated in the injured vascular wall<sup>21)</sup>. Accordingly, further studies should be performed to elucidate the effects of pemirolast on the chymase-dependent angiotensin-forming pathway.

Before our study, the results of small placebo-controlled angiographic trials showed a statistically and clinically significant reduction in restenosis after POBA with tranilast<sup>24,25)</sup>, which is an antiallergic and antikeloid drug. In a concurrent controlled study, patients who were treated with only stent placement were compared with those who received concomitant therapy by stenting and tranilast, showing a reduction in angiographic restenosis from 45% to 26% ( $p < 0.05$ )<sup>6)</sup>. These trials were limited in scope and could not demonstrate statistical differences in clinical outcomes. Therefore, the Prevention of REStenosis with Tranilast and its Outcomes (PRESTO) trial was conducted to evaluate the effects of tranilast on major adverse cardiovascular events as well as quantitative angiographic and IVUS end points. However, this multicenter, large, randomized clinical trial, found that administration of tranilast in 2 different doses for 2 different durations was associated with no improvement in either angiographic or clinical restenosis compared with administration of placebo<sup>27)</sup>. Although we found that pemirolast more strongly inhibits the proliferation of vascular smooth muscle cells com-

pared with tranilast (unpublished data), the differences in mechanisms or potential for preventing in-stent restenosis between pemirolast and tranilast still remain unknown.

In recent years, many studies have examined the prevention of restenosis by using drugs. The polymer coated stent has been developed as a stent-based pharmacologic strategy which could be effective to increase the biocompatibility of metal stents to human body as well as enable local delivery of drugs. Drug-eluting stents, which could maintain an effective drug concentration in the target tissue over a certain period of time, were also developed and are currently under investigation. Clinical studies of stents eluting sirolimus (rapamycin) or paclitaxel are already underway in Europe and U.S., and the effectiveness will soon be known<sup>28,29</sup>. The pemirolast-eluting stent will also be investigated in more detail.

### Study limitations

This study has a few important limitations. The major limitations are the small number of patients in each group and the open-label study design. Therefore, a double-blind study with a large number of patients is needed. Twenty (22%) of all 89

lesions which were subjected to angiographic analysis at follow-up could not be included in the IVUS study, so the patients with the worst results such as severe restenosis at follow-up were excluded, and the effects of pemirolast might not be completely assessed. This IVUS study was recorded by manual pullback method of IVUS catheter, and was a comparative study of the neointima area at only the minimal lumen with two-dimensional IVUS, so the neointima hyperplasia measurement might not be accurate. Therefore, a comparative study to examine in-stent neointima volume using the auto pullback method and three-dimensional IVUS is necessary. All of the stents used in this study were from the first generation, so further study to examine whether pemirolast can lower the risk of restenosis in patients treated by current stents is expected.

### CONCLUSIONS

The results of the present randomized comparative study suggest that the administration of pemirolast inhibits vascular smooth muscle cell proliferation after coronary stenting, and is useful in the clinical setting to prevent in-stent restenosis.

## 要 約

### 抗アレルギー薬であるペミロラストのステント再狭窄に及ぼす予防効果:

#### 定量的冠動脈造影と血管内エコー法による検討

大澤 秀文 野池 博文 金井 正仁 櫃本 孝志  
 青柳 兼之 櫻井 岳史 杉山 祐公 吉永 国土  
 賀来美千久 松本 淳 飯塚 卓夫 清水 一寛  
 高橋 真生 東丸 貴信 櫻川 浩 徳弘 圭一

背景: 我々は抗アレルギー薬であるペミロラストカリウムが内膜増殖抑制作用により経皮的冠動脈拡張術後の再狭窄を減少させることを報告したが, ステント再狭窄に関する有効性についてはいまだ不明である.

目的: ペミロラストがステント再狭窄を予防するか否かを明らかにする.

方法: 初回待機的ステント留置術の成功84例を無作為にペミロラスト投与群(ペミロラスト群: 40例, 45病変)と対照群(44例, 44病変)に振り分け, ペミロラスト群には術翌朝よりペミロラスト20mg/dayの経口投与した. 定量的冠動脈造影はステント直後および6ヵ月後に行い, 再狭窄の定義は6ヵ月後の定量的冠動脈造影で狭窄度が50%以上とした. 血管内エコー法は6ヵ月後に行い, ステント内の最小血管内腔部における血管断面積(VA), 血管内腔面積(LA), ステント面積(SA), 新生内膜面積( $NA = SA - LA$ ),  $\%NA[(SA - LA)/SA \times 100]$ を計測・算出し, これらの指標の平均値を2群間(ペミロラスト群: 38病変, 対照群: 33病変)で比較検討した.

結果: 両群間に患者, 病変, 手技背景に差異はなかった. 患者および病変再狭窄率はペミロラ



スト群が対照群に比べて有意に低率であった(15.0% vs 34.1%, 13.3% vs 34.1%, 各  $p < 0.05$ )。血管内エコー法では、遠隔期のVAおよびSAはともに両群間で差異を認めなかったが( $17.3 \pm 2.2$  vs  $16.8 \pm 2.4$  mm<sup>2</sup>,  $8.6 \pm 1.9$  vs  $8.4 \pm 1.7$  mm<sup>2</sup>), NAおよび%NAはペミロラスト群が対照群に比べて有意に小さく(NA:  $3.1 \pm 1.1$  vs  $4.0 \pm 1.2$  mm<sup>2</sup>,  $p < 0.05$ ; %NA:  $36.2 \pm 15.9\%$  vs  $47.4 \pm 15.6\%$ ,  $p < 0.01$ ), それに伴い遠隔期のLAはペミロラスト群で有意に大であった( $5.5 \pm 1.3$  vs  $4.4 \pm 1.1$  mm<sup>2</sup>,  $p < 0.05$ )。

結 語: ペミロラストは新生内膜増殖を抑制することによりステント後再狭窄を予防することが示唆された。

*J Cardiol* 2003 Jul; 42(1): 13 - 22

## References

- 1) Serruys PW, de Jaegere P, Kiemeneij F, Macaya C, Rutsch W, Heyndrickx G, Emanuelsson H, Marco J, Legrand V, Materne P, Belardi J, Sigwart V, Colombo A, Goy JJ, Heuvel P, Delcan J, Morel M, Benestent Study Group: A comparison of balloon-expandable-stent implantation with balloon angioplasty in patients with coronary artery disease. *N Engl J Med* 1994; **331**: 489 - 495
- 2) Fischman DL, Leon MB, Baim DS, Schatz RA, Savage MP, Penn I, Detre K, Veltri L, Ricci D, Nobuyoshi M, Cleman M, Heuser R, Almond D, Teirstein PS, Fish RD, Colombo A, Brinker J, Moses J, Shaknovich A, Hirshfeld J, Bailey S, Ellis S, Rake R, Goldberg S, Stent Restenosis Study Investigators: A randomized comparison of coronary-stent placement and balloon angioplasty in the treatment of coronary artery disease. *N Engl J Med* 1994; **331**: 496 - 501
- 3) Hoffmann R, Mintz GS, Dussaillant GR, Popma JJ, Pichard AD, Satler LF, Kent KM, Griffin J, Leon MB: Patterns and mechanisms of in-stent restenosis: A serial intravascular ultrasound study. *Circulation* 1996; **94**: 1247 - 1254
- 4) Yanagihara Y, Kasai H, Shida T: Immunopharmacological studies on TBX, a new antiallergic drug(2): Inhibitory effects on histamine release from peritoneal mast cells and lung fragments of rats. *Jpn J Pharmacol* 1988; **48**: 103 - 112
- 5) Fujimiya H, Nakashima S, Miyata H, Nizawa Y: Effect of a novel antiallergic drug, pemirolast, on activation of rat peritoneal mast cells: Inhibition of exocytotic response and membrane phospholipid turnover. *Int Arch Allergy Appl Immunol* 1991; **96**: 62 - 67
- 6) Kawashima T, Sato Y, Aiba T, Omura S, Kasai H: Inhibitory effect of pemirolast potassium(TBX) on release of histamine and leukotriene D4 and B4 and on production of platelet-activating factor. *Pharmacometrics* 1993; **46**: 265 - 271
- 7) Fujimiya H, Nakashima S, Kumada T, Nakamura Y, Miyata H, Nizawa Y: An antiallergic drug, pemirolast potassium, inhibits inositol 1, 4, 5-trisphosphate production and Ca<sup>2+</sup> mobilization in antigen-stimulated rat basophilic leukemia(RBL-2H3) cells. *Jpn J Allergol* 1994; **43**: 142 - 151
- 8) Yoshida S, Tomioka H, Takishima T, Kobayashi S, Makino S, Miyamoto T, Takahashi S, Kishimoto S, Nagano J: Clinical evaluation of an orally antiallergic agent, TBX, in adult bronchial asthma: Multi-center double-blind study in comparison with tranilast. *Jpn Pharmacol Ther* 1989; **17**: 933 - 981
- 9) Kanai M: Effects of a novel antiallergic drug, pemirolast potassium, on the proliferation and migration of cultured smooth muscle cells from rat aorta. *J Jpn Atheroscler Soc* 1996; **23**: 707 - 713
- 10) Miyazawa N, Umemura K, Mizuno A, Kondo K, Nakashima M: Inhibitory effect of pemirolast, anti-allergic drug, on neointimal thickening after arterial injury in the rat. *Jpn J Pharmacol* 1996; **71**(Suppl 1): 233
- 11) Ohsawa H, Noike H, Kanai M, Yoshinuma M, Mineoka K, Hitsumoto T, Aoyagi K, Sakurai T, Sato S, Uchi T, Kawamura K, Tokuhiko K, Uchida Y, Tomioka H: Preventive effects of an antiallergic drug, pemirolast potassium, on restenosis after percutaneous transluminal coronary angioplasty. *Am Heart J* 1998; **136**: 1081 - 1087
- 12) Yoshinuma M: Preventive mechanisms and effects of pemirolast potassium on restenosis after percutaneous transluminal coronary angioplasty: Serial coronary angiography and intravascular ultrasound studies. *J Cardiol* 1999; **33**: 81 - 88(in Jpn with Eng abstr)
- 13) Ryan TJ, Bauman WB, Kennedy JW, Kereiakes DJ, King SB, McCallister BD, Smith SC, Ulliyot DJ: Guidelines for percutaneous transluminal coronary angioplasty: A report of the American College of Cardiology/American Heart Association Task Force on Assessment of Diagnostic and Therapeutic Cardiovascular Procedures(Committee on Percutaneous Transluminal Coronary Angioplasty) *J Am Coll Cardiol* 1993; **22**: 2033 - 2054
- 14) Mintz GS, Popma JJ, Hong MK, Pichard AD, Kent KS, Satler LF, Leon MB: Intravascular ultrasound to discern device-specific effects and mechanisms of restenosis. *Am J Cardiol* 1996; **78**(Suppl 3A): 18 - 22
- 15) Kornowski R, Hong MK, Tio FO, Bramwell O, Wu H, Leon MB: In-stent restenosis: Contributions of inflammatory responses and arterial injury to neointimal hyperplasia. *J Am Coll Cardiol* 1998; **31**: 224 - 230
- 16) Farb A, Sangiorgi G, Carter AJ, Walley VM, Edwards WD, Schwartz RS, Virmani R: Pathology of acute and chronic coronary stenting in humans. *Circulation* 1999; **99**: 44 - 52
- 17) Ross R: Atherosclerosis: An inflammatory disease. *N Engl J Med* 1999; **340**: 115 - 126
- 18) Koster R, Vieluf D, Kiehn M, Sommerauer M, Kahler J, Baldus S, Meinerz T, Hamm CW: Nickel and molybdenum contact allergies in patients with coronary in-stent

- restenosis. *Lancet* 2000; **356**: 1895 - 1897
- 19) Urata H, Kinoshita A, Misono KS, Bumpus FM, Husain A: Identification of a highly specific chymase as the major angiotensin -forming enzyme in the human heart. *J Biol Chem* 1990; **265**: 22348 - 22357
  - 20) Kinoshita A, Urata H, Bumpus FM, Husain A: Multiple determinants for the high substrate specificity of an angiotensin -forming chymase from human heart. *J Biol Chem* 1991; **266**: 19192 - 19197
  - 21) Shiota N, Okunishi H, Fukamizu A, Sakonjo H, Kikumori M, Nishimura T, Nakagawa T, Murakami K, Miyazaki M: Activation of two angiotensin-generating systems in the balloon-injured artery. *FEBS Lett* 1993; **323**: 239 - 242
  - 22) Jason EK, Garrison JC: Renin and angiotensin. *in Goodman & Gilman's the Pharmacological Basis of Therapeutics* (ed by Limbird LE, Gilman AG) McGraw-Hill, New York, 1996; p 733
  - 23) Dzau VI: Local expression and pathophysiological role of renin-angiotensin in the blood vessels and heart. *in Angiotensin and Heart* (ed by Grobecker H) Springer-Verlag, New York, 1993; p 1
  - 24) Tamai H, Katoh O, Suzuki S, Fujii K, Aizawa T, Takase S, Kurogane H, Nishikawa H, Sone T, Sakai K, Suzuki T: Impact of tranilast on restenosis after coronary angioplasty: Tranilast restenosis following angioplasty trial (TREAT). *Am Heart J* 1999; **138**: 968 - 975
  - 25) Tamai H, for the Treated Group: Inhibitory effect of tranilast on restenosis after percutaneous transluminal coronary angioplasty (PTCA): A phase multicenter randomized double blind placebo-controlled trial. *J Clin Ther Med* 1996; **12**: 65 - 85
  - 26) Hsu YS, Tamai H, Lleda K, Ueda K, Ono S, Kosuga K, Tanaka S, Matsui S, Motohara S, Uehata H: Efficacy of tranilast on restenosis after coronary stenting. *Circulation* 1996; **94** (Suppl ): -620 (abstr)
  - 27) Holmes DR Jr, Savage M, LaBlanche JM, Grip L, Serruys PW, Fitzgerald P, Fischman D, Goldberg S, Brinker JA, Zeiher AM, Shapiro LM, Willerson J, Davis BR, Ferguson JJ, Popma J, King SB, Lincoff AM, Tcheng JE, Chan R, Granett JR, Poland M: Results of Prevention of REStenosis with Tranilast and its Outcomes (PRESTO) trial. *Circulation* 2002; **106**: 1243 - 1250
  - 28) Degertekin M, Serruys PW, Foley DP, Tanabe K, Regar E, Vos J, Smits PC, van der Giessen WJ, van den Brand M, de Feyter P, Popma JJ: Persistent inhibition of neointimal hyperplasia after sirolimus-eluting stent implantation: Long-term (up to 2 years) clinical, angiographic, and intravascular ultrasound follow-up. *Circulation* 2002; **106**: 1610 - 1613
  - 29) Kataoka T, Grube E, Honda Y, Morino Y, Hur SH, Bonneau HN, Colombo A, Di Mario C, Guagliumi G, Hauptmann KE, Pitney MR, Lansky AJ, Sertzer SH, Yock PG, Fitzgerald PJ, for the SCORE Investigators: 7-hexanoytaxol-eluting stent for prevention of neointimal growth: An intravascular ultrasound analysis from the Study to COmpare REstenosis rate between QueST and QuaDS-QP2 (SCORE). *Circulation* 2002; **106**: 1788 - 1793