

Thiazolidinedione Treatment Attenuates Diffuse Neointimal Hyperplasia in Restenotic Lesions After Coronary Stent Implantation in Type 2 Diabetic Patients: An Intravascular Ultrasound Study

Tsutomu TAKAGI, MD, FJCC
Atsushi YAMAMURO, MD*
Koichi TAMITA, MD*
Minako KATAYAMA, MD*
Shigefumi MORIOKA, MD, FJCC*

Abstract

Objectives. Thiazolidinedione treatment reduces neointimal tissue proliferation after coronary stent implantation in diabetic patients. However, in-stent restenosis still persists in patients treated with thiazolidinedione. The effect of thiazolidinedione treatment on the pattern of in-stent restenosis remains unclear. This study investigated whether thiazolidinedione treatment attenuates diffuse neointimal hyperplasia in restenotic lesions after coronary stent implantation in diabetic patients.

Methods. Volumetric intravascular ultrasound was performed at 6 months after coronary stent implantation in 76 patients with restenotic lesions who received either conventional anti-diabetic treatment (control group, $n = 56$) or thiazolidinedione treatment (thiazolidinedione group, $n = 20$).

Results. There were no significant differences between the two groups in stent volume (99 ± 32 vs 90 ± 20 mm³, respectively, $p = 0.26$) or in minimal lumen area in the sten (1.4 ± 0.6 vs 1.6 ± 0.5 mm², respectively, $p = 0.11$). However, there were significant reductions in neointimal volume (56 ± 25 vs 36 ± 11 mm³, respectively, $p < 0.01$) and neointimal index ($56 \pm 11\%$ vs $41 \pm 8\%$, respectively, $p < 0.01$) in the thiazolidinedione group. Coefficient of variation of neointimal tissue accumulation was greater in the thiazolidinedione group (45.5%) than in the control group (25.2%).

Conclusions. Intravascular ultrasound study demonstrated that together with reduction of overall neointimal tissue proliferation, thiazolidinedione treatment caused greater point-to-point heterogeneity in the neointimal tissue accumulation in restenotic lesions after coronary stent implantation. This finding strongly suggests that thiazolidinedione treatment attenuates diffuse in-stent restenosis in diabetic patients.

J Cardiol 2005 Apr; 45(4): 139-147

Key Words

■Diabetes mellitus (thiazolidinedione)
■Stent

■Restenosis

■Intravascular ultrasound

INTRODUCTION

Diabetes mellitus is a powerful determinant of in-stent neointimal hyperplasia and diffuse in-stent restenosis (ISR) after coronary stent implantation¹⁻⁴.

Recent intravascular ultrasound (IVUS) studies have demonstrated that troglitazone and pioglitazone, anti-diabetic thiazolidinedione agents, reduce neointimal hyperplasia after coronary stent implantation in patients with type 2 diabetes mellitus⁵⁻⁷.

高木循環器科診療所: 〒604-8811 京都市中京区壬生賀陽御所町3-3; *神戸市立中央市民病院 循環器内科, 神戸 Takagi Cardiology Clinic, Kyoto; *Division of Cardiology, Kobe General Hospital, Kobe

Address for correspondence: TAKAGI T, MD, FJCC, Takagi Cardiology Clinic, Mibu Kayogoshicho 3-3, Nakagyo-ku, Kyoto 604-8811; E-mail: tcardiol@qb4.so-net.ne.jp

Manuscript received September 27, 2004; revised January 14 and 31, 2005; accepted January 31, 2005

However, angiographic ISR still persisted in 19% to 23% of the stented lesions in patients treated with thiazolidinedione^{6,7}). The pattern of ISR may convey prognostic information about subsequent target vessel revascularization. Previous studies showed a high recurrence rate after treating diffuse ISR^{1,8-10}).

The present study investigated whether thiazolidinedione treatment attenuates diffuse neointimal hyperplasia in restenotic lesions after coronary stent implantation in diabetic patients.

SUBJECTS AND METHODS

Study patients and protocol

This prospective, randomized trial in Kobe General Hospital evaluated the effects of troglitazone and pioglitazone on neointimal tissue proliferation after coronary stent implantation in patients with type 2 diabetes mellitus^{5,7}). Quantitative angiographic assessments were done at baseline, post-stenting and at 6-month follow-up using CMS (Medis Medical Imaging Systems). Measurements from multiple projections were performed and the least favorable findings were recorded. ISR was defined as $\geq 50\%$ diameter stenosis within the stent at follow-up. The Kobe General Hospital IVUS-diabetes mellitus registry contains 184 stented lesions, of which 76 lesions with angiographic ISR at a 6-month follow-up were selected for the current analysis. There were 20 lesions in the thiazolidinedione group and 56 lesions in the control group. All patients gave written informed consent before randomization as previously reported⁵⁻⁷). The study protocol was approved by the institutional ethic committee.

Intravascular ultrasound imaging and analysis

IVUS was performed at a 6-month follow-up. Images were acquired using commercially available imaging systems with 30 MHz mechanical transducers (CVIS/Boston Scientific Corporation) with automated transducer pullback (0.5 mm/sec) after administration of intracoronary isosorbide dinitrate (1 to 2 mg). IVUS at 6-month follow-up was obtained before repeat coronary intervention for the ISR.

Quantitative analysis was performed with validated, commercially available planimetry software (Tapemeasure, IndecSystem, Inc.). Cross-sectional measurements of stent and lumen area were performed manually every 1 mm throughout the stent.

Simpson's method was used to calculate stent, lumen, and neointimal (= stent - lumen) volumes. Neointimal volume index was calculated as neointimal volume divided by stent volume. Neointimal area index was calculated as neointimal area divided by stent area at the image slice with minimal lumen area. The axial variability of neointimal accumulation was assessed by calculating the coefficient of variation (CV) of the increase in neointimal proliferation by dividing the standard deviation (SD) of the neointimal area by the mean neointimal area¹¹).

Statistical analysis

Continuous data are presented as mean \pm SD, and categorical data are presented as frequencies. Continuous variables were compared using the Mann-Whitney *U*-test. Categorical variables were compared using the Fisher exact probability test. Results of IVUS measurements, clinical, angiographic and procedural characteristics were determined using lesion-based assessments. A two-sided value of $p < 0.05$ was considered significant.

RESULTS

As shown in **Table 1**, there were no significant differences in patient characteristics between the two groups. Glucose levels at baseline and at 6-month follow-up were equivalent in both groups. As shown in **Table 2**, there were no significant differences between the two groups in medical treatment except the use of alpha-glucosidase inhibitors was more frequent in the control group. **Table 3** summarizes angiographic and procedural characteristics. There were no significant differences in angiographic and procedural characteristics between the two groups. **Fig. 1** shows the results of quantitative coronary angiographic analysis. There were no significant differences between the two groups in minimal lumen diameter at baseline, post-stenting, or 6-month follow-up.

As shown in **Fig. 2**, volumetric IVUS analysis demonstrated that there was no significant difference in stent volume between the two groups (99 ± 32 vs 90 ± 20 mm³, $p = 0.26$). However, lumen volume in the thiazolidinedione group was significantly greater than in the control group. Neointimal volume and index in the thiazolidinedione group were significantly smaller than in the control group (56 ± 25 vs 36 ± 11 mm³, $p < 0.01$; $56 \pm 11\%$ vs $41 \pm 8\%$, $p < 0.01$). As shown in **Fig. 3**, IVUS

Table 1 Patient characteristics

	Thiazolidinedione (n = 20)	Control (n = 56)	p value
Age (yr)	66 ± 10	64 ± 9	0.21
Sex (male/female)	13/7	40/16	0.58
BMI-baseline (kg/m ²)	24.8 ± 2.1	25.7 ± 2.8	0.13
Systolic BP (mmHg)	136 ± 15	131 ± 18	0.28
Diastolic BP (mmHg)	72 ± 10	71 ± 10	0.94
FBS-baseline (mg/dl)	134 ± 25	138 ± 38	0.46
FBS-follow-up (mg/dl)	122 ± 30	125 ± 26	0.53
HbA _{1c} -baseline (%)	6.8 ± 1.0	6.8 ± 1.4	0.61
HbA _{1c} -follow-up (%)	6.4 ± 0.9	6.4 ± 1.3	0.41

Continuous values are mean ± SD.

BMI = body mass index ; BP = blood pressure ; FBS = fasting blood sugar ; HbA_{1c} = hemoglobin A_{1c}.

Table 2 Medical treatments

	Thiazolidinedione (n = 20)	Control (n = 56)	p value
ACE inhibitor	15 (75)	44 (79)	0.76
Angiotensin receptor blocker	0	0	NA
Calcium channel blocker	2 (10)	8 (14)	> 0.99
Beta-blocker	14 (70)	38 (68)	> 0.99
Statins	12 (60)	34 (61)	> 0.99
Probucol	0	2 (4)	> 0.99
Aspirin	20 (100)	56 (100)	NA
Ticlopidine	20 (100)	56 (100)	NA
Cilostazol	2 (10)	4 (7)	0.65
Alpha-glucosidase inhibitors	3 (15)	35 (63)	< 0.01
Sulfonylurea	9 (45)	23 (41)	0.80
Insulin	4 (20)	7 (13)	0.47

() %.

ACE = angiotensin converting enzyme ; NA = no account.

measurement of the image slice with minimal lumen area showed no significant difference in stent area, lumen area (1.4 ± 0.6 vs 1.6 ± 0.5 mm², $p = 0.11$), neointimal area, or neointimal area index between the two groups. We assessed the axial variability in neointimal proliferation in the two groups by calculating the CV of the neointimal area (CV = SD of neointimal area/mean neointimal area). The CV of neointimal area was significantly greater in the thiazolidinedione group than in the control group (45.5% vs 25.2%, $p < 0.01$; **Fig. 4**). **Fig. 5** shows representative cases of the two groups, to demonstrate the axial distribution of the neointimal area standardized by the mean neointimal area. Greater point-to-point variability of

neointimal area was seen in the thiazolidinedione group.

DISCUSSION

The present IVUS study demonstrated that together with the reduction of overall neointimal hyperplasia, thiazolidinedione treatment caused greater point-to-point heterogeneity in neointimal accumulation in restenotic lesions after coronary stent implantation.

The mechanism of ISR is the result of neointimal hyperplasia^{12,13}. Histological studies in humans have demonstrated that early thrombus formation and acute inflammation are followed by neointimal tissue proliferation in the chronic stage after coro-

Table 3 Angiographic characteristics

	Thiazolidinedione (n = 20)	Control (n = 56)	p value
LAD/LCX/RCA	13/3/4	37/6/13	0.69
Lesion classification			
A/B/C	2/14/4	4/41/8	0.65
Reference diameter(mm)	2.7 ± 0.2	2.8 ± 0.4	0.27
MLD-baseline(mm)	0.8 ± 0.3	0.8 ± 0.3	0.74
Lesion length(mm)	11.9 ± 3.2	12.3 ± 3.7	0.81
Stent			
MultiLink/NIR/Terumo	12/8/0	42/13/1	0.16
Stent length(mm)	15.9 ± 3.3	16.8 ± 4.4	0.38
Balloon diameter(mm)	2.8 ± 0.3	2.9 ± 0.4	0.15
Balloon pressure(atm)	11.5 ± 1.7	11.8 ± 2.1	0.62

Continuous values are mean ± SD.

LAD = left anterior descending artery; LCX = left circumflex artery; RCA = right coronary artery; MLD = minimal lumen diameter.

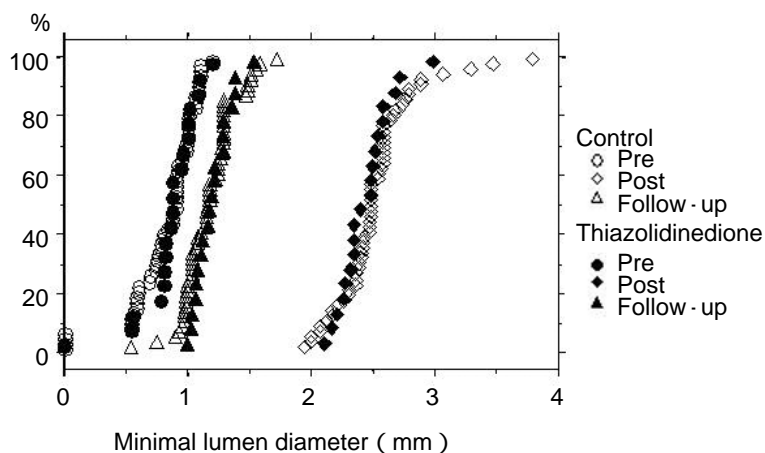


Fig. 1 Quantitative coronary angiographic analysis demonstrating no significant differences between the two groups in minimal lumen diameter at baseline, post-stent, or 6-month follow-up

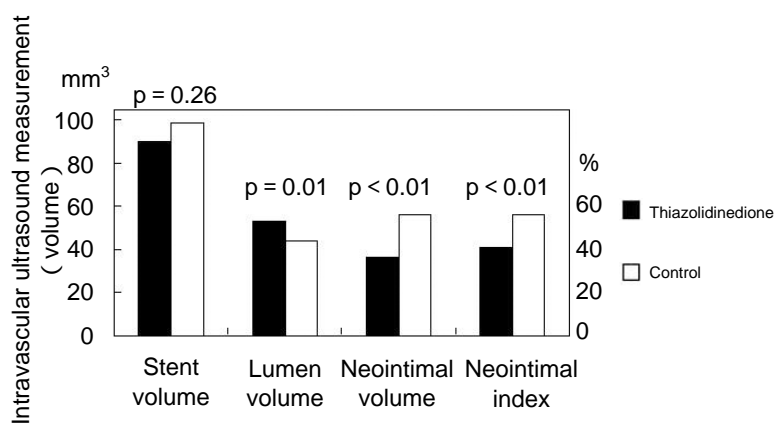


Fig. 2 Volumetric intravascular ultrasound analysis demonstrating no significant difference between the two groups in stent volume
Lumen volume in the thiazolidinedione group was significantly greater than in the control group, and neointimal volume and index in the thiazolidinedione group were significantly smaller than in the control group.

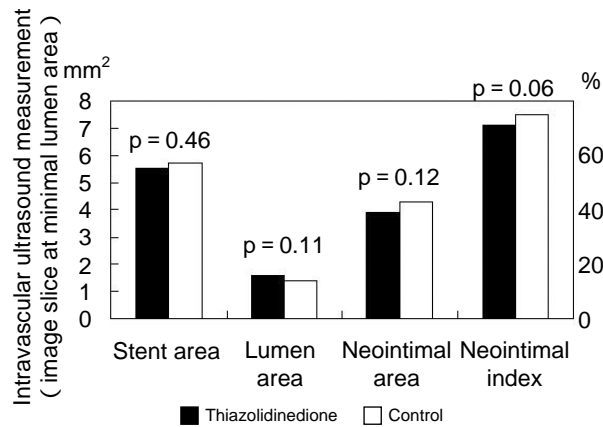


Fig. 3 Intravascular ultrasound measurement at image slice with minimal lumen area showing no significant differences in stent area, lumen area, neointimal area, or neointimal area index between the two groups

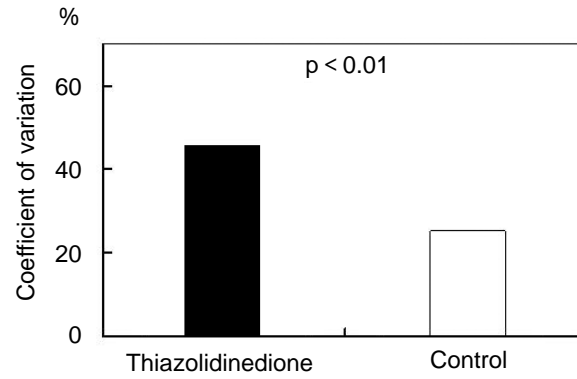


Fig. 4 Heterogeneity in neointimal accumulation

The coefficient of variance of the neointimal area was significantly greater in the thiazolidinedione group than in the control group.

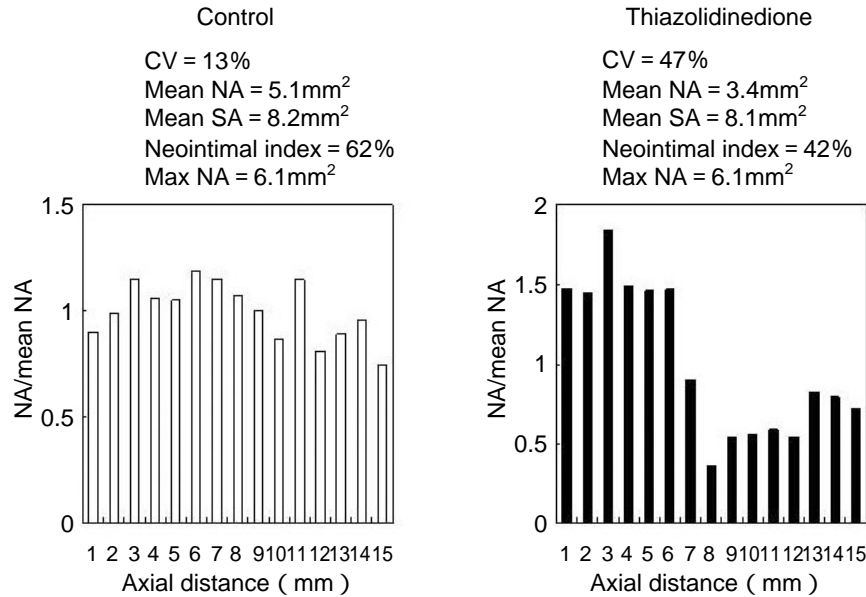


Fig. 5 Representative cases demonstrating the axial distribution of neointimal tissue accumulation

Both panels demonstrate axial distribution of neointimal area standardized by mean neointimal area. There were no significant differences between the two cases in stent length, mean stent area or maximal neointimal area. The right panel shows greater point-to-point variability of neointimal area in the thiazolidinedione treated case.

CV = coefficient of variation; NA = neointimal area; SA = stent area; Max NA = maximal neointimal area.

nary stent implantation^{14,15}). Analysis of directional atherectomy specimens of early ISR tissue showed predominantly smooth muscle cells. The lesion cellularity decreases with time over weeks or months, and extra-cellular matrix (proteoglycans and collagen) becomes the predominant component of restenotic lesions¹⁶). ISR is predominantly affected

by local conditions at the site of coronary stenting, such as vessel size, stent type, and stent length¹⁷). Several IVUS studies have reported that greater pre- or post-interventional plaque burden is associated with greater neointimal tissue proliferation after stent implantation¹⁸⁻²⁰). Postmortem histologic analysis of ISR demonstrated that neointimal thick-

ness at stent strut sites was greatest at sites of medial injury¹⁵). These local conditions may contribute to the focal ISR or point-to-point heterogeneity of neointimal tissue accumulation even in diabetic patients with thiazolidinedione treated. The presence of diabetes mellitus accelerates the process of neointimal tissue proliferation and promotes the development of diffuse ISR. Diabetes mellitus results in increased inflammation, increased platelet activation, impaired fibrinolysis, and abnormal coagulation. Patients with type 2 diabetes mellitus have increased inflammation as indicated by increased generation of reactive oxygen species by mononuclear cells²¹). Patients with diabetes mellitus also have elevated levels of interleukin-6, tumor necrosis factor- α , and C-reactive protein^{22,23}). Type 2 diabetes mellitus enhances the synthesis of plasminogen activator inhibitor type 1 (PAI-1)²⁴). PAI-1 inhibits endogenous intravascular fibrinolysis, and increased PAI-1 levels lead to impaired fibrinolysis and thus the prothrombotic state²⁵). PAI-1 is also implicated in the inhibition of proteolysis, which allows for increased deposition of extracellular matrix, an important component of restenotic lesions in diabetic patients²⁶). Increased smooth muscle cell proliferation with exaggerated neointimal hyperplasia has also been demonstrated in diabetic animal models^{26,27}).

The thiazolidinedione agents are a family of peroxisome proliferator activated receptor- γ ligands, and form a new class of pharmacological agents for the treatment of type 2 diabetes mellitus²⁸⁻³⁰). Thiazolidinedione has potential protective effects on cardiovascular function. These drugs inhibit growth factor-induced proliferation of vascular smooth muscle cells, inhibit smooth muscle cell migration, and attenuate the development of neointimal hyperplasia after balloon-induced vascular injury in animal models³¹⁻³⁶). Recent studies have demonstrated that pioglitazone enhances apoptosis in balloon-induced vascular injury, and reduces coronary vascular inflammation in an animal model^{37,38}). Thiazolidinedione reduces PAI-1 and C-reactive protein concentration in diabetic patients³⁹⁻⁴²). Rosiglitazone reduces ISR after coronary stent implantation in diabetic patients. Rosiglitazone also reduces high-sensitivity C-reactive protein concentration in diabetic patients⁴³). These studies suggest that thiazolidinedione treatment attenuates the accelerated process of neointimal hyperplasia and causes greater point-to-point

heterogeneity in neointimal accumulation in ISR via several mechanisms: anti-inflammatory effects, down-regulation of PAI-1 expression, inhibition of cellular tissue growth, and enhancing regression of developed neointimal tissue after coronary stent implantation. Further study is required to evaluate whether the effect of thiazolidinedione on high-sensitivity C-reactive protein levels or PAI-1 expression is associated with reduction of neointimal tissue proliferation after coronary stent implantation in diabetic patients.

Clinical implications

The present study suggests that thiazolidinedione treatment attenuates diffuse ISR in diabetic patients. The pattern of ISR gives prognostic information about subsequent target vessel revascularization. Diffuse ISR is associated with high recurrence rate after repeat coronary intervention¹⁻⁴). Therefore, thiazolidinedione treatment may provide subsequent benefits for diabetic patients who undergo repeat coronary intervention. Further studies are warranted to determine whether thiazolidinedione treatment reduces subsequent restenosis after repeat coronary intervention for the ISR.

Study limitations

The present study had some intrinsic limitations. This study was a single center, non-placebo-controlled study with a small number of patients, raising the possibility of selection bias and low statistical power. IVUS cannot be used to measure lumen dimensions smaller than the imaging catheter. When the tissue encompassed the IVUS catheter, the lumen was assumed to be the physical size of the IVUS catheter. Therefore, 1.0 mm was the smallest minimal lumen diameter, and 0.8 mm² was the smallest cross-sectional lumen area that could be measured before re-intervention. This limitation may underestimate the late lumen loss or neointimal tissue proliferation in severely restenotic lesions. In addition, because of the finite resolution of IVUS, very thin neointimal proliferation on the stent struts could not be differentiated by quantitative IVUS analysis. A previous angiographic study classified diffuse ISR into three classes, diffuse intra-stent ISR, diffuse proliferative ISR, and diffuse ISR with total occlusion²). The rate of subsequent revascularization after repeat interventional treatment in diffuse proliferative ISR and diffuse ISR with total occlusion was greater than in diffuse

intra-stent ISR²⁾. Because totally occluded diffuse ISR was difficult to cross with the IVUS catheter before repeat intervention, diffuse ISR with total occlusion was not included in the current IVUS analysis. In addition, because IVUS images were obtained within the stent, quantitative IVUS analysis might underestimate diffuse proliferative ISR.

CONCLUSIONS

Together with the reduction of overall neointimal hyperplasia, thiazolidinedione treatment causes greater point-to-point heterogeneity in neointimal accumulation. This finding strongly suggests that thiazolidinedione treatment attenuates diffuse ISR after coronary stent implantation in diabetic patients.

要 約

2型糖尿病患者においてThiazolidinedione治療はステント内再狭窄病変における び慢性新生内膜増殖を抑制する: 血管内エコー法を用いた検討

高木 力 山室 淳 民田 浩一 片山美奈子 盛岡 茂文

背景: 2型糖尿病患者においてチアゾリジン誘導体(thiazolidinedione)が冠動脈ステント留置後のステント内新生内膜増殖を抑制することが報告されている。しかしながら, thiazolidinedione治療を行った患者においてもステント再狭窄が残存する。

目的: 本研究の目的は, そのようなステント再狭窄例において, thiazolidinedioneがび慢性ステント内新生内膜増殖を抑制するか否かを検討することである。

方法: 対象は神戸市立中央市民病院で血管内エコー検査(IVUS)-糖尿病レジストリーに登録された186病変中, 慢性期の冠動脈造影でステント再狭窄を認めた76病変である。対象をthiazolidinedione治療群20病変, 対照群(通常治療群)56病変を2群に分け, 全例について, 再冠動脈形成術実施前のIVUS画像について定量的IVUS解析を実施した。

結果: 対照群とthiazolidinedione治療群の定量的IVUS解析の結果では, ステント容積(99 ± 32 vs 90 ± 20 mm³, $p = 0.26$)やステント内最小血管面積(1.4 ± 0.6 vs 1.6 ± 0.5 mm², $p = 0.11$)について両群間に有意差を認めなかった。しかし, ステント内新生内膜容積(56 ± 25 vs 36 ± 11 mm³, $p < 0.01$)や新生内膜インデックス($56 \pm 11\%$ vs $41 \pm 8\%$, $p < 0.01$)については対照群と比較してthiazolidinedione治療群で有意に小さかった。ステント内新生内膜増殖の不均一性を検討するため新生内膜増殖のcoefficient of variationについて両群間で比較検討した。Coefficient of variationは対照群(25.2%)と比較してthiazolidinedione治療群(45.5%)で有意に大きく, thiazolidinedione治療群においてより不均一な新生内膜増殖を認めた。

結論: ステント再狭窄病変の定量的IVUS解析により, 対照群ではステント全体に均一な新生内膜増殖を認めるのに対して, thiazolidinedione治療群ではより不均一なステント内新生内膜増殖を認めることが判明した。このことから, thiazolidinedione治療が2型糖尿病患者におけるび慢性ステント再狭窄を予防する可能性が示唆された。

J Cardiol 2005 Apr; 45(4): 139 - 147

References

- 1) Mehran R, Dangas G, Abizaid AS, Mintz GS, Lansky AJ, Satler LF, Pichard AD, Kent KM, Stone GW, Leon MB: Angiographic patterns of in-stent restenosis: Classification and implications for long-term outcome. *Circulation* 1999; **100**: 1872 - 1878
- 2) Kornowski R, Mintz GS, Kent KM, Pichard AD, Satler LF, Bucher TA, Hong MK, Popma JJ, Leon MB: Increased restenosis in diabetes mellitus after coronary interventions is due to exaggerated intimal hyperplasia: A serial intravascular ultrasound study. *Circulation* 1997; **95**: 1366 - 1369
- 3) Abizaid A, Kornowski R, Mintz GS, Hong MK, Abizaid AS, Mehran R, Pichard AD, Kent KM, Satler LF, Wu H, Popma JJ, Leon MB: The influence of diabetes mellitus on acute and late clinical outcomes following coronary stent implantation. *J Am Coll Cardiol* 1998; **32**: 584 - 589

- 4) Lee SG, Lee CW, Hong MK, Park HK, Kim JJ, Park SW, Park SJ: Predictors of diffuse-type in-stent restenosis after coronary stent implantation. *Catheter Cardiovasc Interv* 1999; **47**: 406 - 409
- 5) Takagi T, Akasaka T, Yamamuro A, Honda Y, Hozumi T, Morioka S, Yoshida K: Troglitazone reduces neointimal tissue proliferation after coronary stent implantation in patients with non-insulin dependent diabetes mellitus: A serial intravascular ultrasound study. *J Am Coll Cardiol* 2000; **36**: 1529 - 1535
- 6) Takagi T, Yamamuro A, Tamita K, Yamabe K, Katayama M, Morioka S, Akasaka T, Yoshida K: Impact of troglitazone on coronary stent implantation using small stents in patients with type 2 diabetes mellitus. *Am J Cardiol* 2002; **89**: 318 - 322
- 7) Takagi T, Yamamuro A, Tamita K, Yamabe K, Katayama M, Mizoguchi S, Ibuki M, Tani T, Tanabe K, Nagai K, Shiratori K, Morioka S, Yoshikawa J: Pioglitazone reduces neointimal tissue proliferation after coronary stent implantation in patients with type 2 diabetes mellitus: An intravascular ultrasound scanning study. *Am Heart J* 2003; **146**: E5
- 8) Reimers B, Moussa I, Akiyama T, Tucci G, Ferraro M, Martini G, Blengino S, Di Mario C, Colombo A: Long-term clinical follow-up after successful repeat percutaneous intervention for stent restenosis. *J Am Coll Cardiol* 1997; **30**: 186 - 192
- 9) vom Dahl J, Radke PW, Haager PK, Koch KC, Kastrau F, Reffelmann T, Janssens U, Hanrath P, Klues HG: Clinical and angiographic predictors of recurrent restenosis after percutaneous transluminal rotational atherectomy for treatment of diffuse in-stent restenosis. *Am J Cardiol* 1999; **83**: 862 - 867
- 10) Bossi I, Klersy C, Black AJ, Cortina R, Choussat R, Cassagneau B, Jordan C, Laborde JC, Laurent JP, Bernies M, Fajadet J, Marco J: In-stent restenosis: Long-term outcome and predictors of subsequent target lesion revascularization after repeat balloon angioplasty. *J Am Coll Cardiol* 2000; **35**: 1569 - 1576
- 11) Morino Y, Limpijankit T, Honda Y, Lansky AJ, Waksman R, Bonneau HN, Yock PG, Mintz GS, Fitzgerald PJ: Late vascular response to repeat stenting for in-stent restenosis with and without radiation: An intravascular ultrasound volumetric analysis. *Circulation* 2002; **105**: 2465 - 2468
- 12) Hoffmann R, Mintz GS, Dussaillant GR, Popma JJ, Pichard AD, Satler LF, Kent KM, Griffin J, Leon MB: Patterns and mechanisms of in-stent restenosis: A serial intravascular ultrasound study. *Circulation* 1996; **94**: 1247 - 1254
- 13) Dussaillant GR, Mintz GS, Pichard AD, Kent KM, Satler LF, Popma JJ, Wong SC, Leon MB: Small stent size and intimal hyperplasia contribute to restenosis: A volumetric intravascular ultrasound analysis. *J Am Coll Cardiol* 1995; **26**: 720 - 724
- 14) Komatsu R, Ueda M, Naruko T, Kojima A, Becker AE: Neointimal tissue response at site of coronary stenting in human: Macroscopic, histological, and immunohistochemical analyses. *Circulation* 1998; **98**: 224 - 233
- 15) Farb A, Sangiorgi G, Carter AJ, Walley VM, Edwards WD, Schwartz RS, Virmani R: Pathology of acute and chronic coronary stenting in humans. *Circulation* 1999; **99**: 44 - 52
- 16) Chung IM, Gold HK, Schwartz SM, Ikari Y, Reidy MA, Wight TN: Enhanced extracellular matrix accumulation in restenosis of coronary arteries after stent deployment. *J Am Coll Cardiol* 2002; **40**: 2072 - 2081
- 17) Kastrati A, Mehilli J, Dirschinger J, Pache J, Ulm K, Schühlen H, Seyfarth M, Schmitt C, Blasini R, Neumann FJ, Schomig A: Restenosis after coronary placement of various stent types. *Am J Cardiol* 2001; **87**: 34 - 39
- 18) Prati F, Di Mario C, Moussa I, Reimers B, Mallus MT, Parma A, Liroy E, Colombo A: In-stent neointimal proliferation correlates with the amount of residual plaque burden outside the stent: An intravascular ultrasound study. *Circulation* 1999; **99**: 1011 - 1014
- 19) Endo A, Hirayama H, Yoshida O, Arakawa T, Akima T, Yamada T, Nanasato M: Arterial remodeling influences the development of intimal hyperplasia after stent implantation. *J Am Coll Cardiol* 2001; **37**: 70 - 75
- 20) Sahara M, Kirigaya H, Oikawa Y, Yajima J, Ogasawara K, Satoh H, Nagashima K, Hara H, Nakatsu Y, Aizawa T: Arterial remodeling patterns before intervention predict diffuse in-stent restenosis: An intravascular ultrasound study. *J Am Coll Cardiol* 2003; **42**: 1731 - 1738
- 21) Orié NN, Zidek W, Tepe M: Increased intracellular generation of reactive oxygen species in mononuclear leukocytes from patients with diabetes mellitus type 2. *Exp Clin Endocrinol Diabetic* 2000; **108**: 175 - 180
- 22) Kern PA, Ranganathan S, Li C, Wood L, Ranganathan G: Adipose tissue tumor necrosis factor and interleukin-6 expression in human obesity and insulin resistance. *Am J Physiol Endocrinol Metab* 2001; **280**: E745 - E751
- 23) Pickup JC, Mattock MB, Chusney GD, Burt D: NIDDM as a disease of the innate immune system: Association of acute-phase reactants and interleukin-6 with metabolic syndrome X. *Diabetologia* 1997; **40**: 1286 - 1292
- 24) McGill JB, Schneider DJ, Arfken CL, Lucre CL, Sobel BE: Factors responsible for impaired fibrinolysis in obese subjects and NIDDM patients. *Diabetes* 1994; **43**: 104 - 109
- 25) Sobel BE, Woodcock-Mitchell J, Schneider DJ, Holt RE, Marutsuka K, Gold H: Increased plasminogen activator inhibitor type 1 in coronary artery atherectomy specimens from type 2 diabetic compared with nondiabetic patients: A potential factor predisposing to thrombosis and its persistence. *Circulation* 1998; **97**: 2213 - 2221
- 26) Moreno PR, Fallon JT, Murcia AM, Leon MN, Simosa H, Fuster V, Palacios IF: Tissue characteristics of restenosis after percutaneous transluminal coronary angioplasty in diabetic patients. *J Am Coll Cardiol* 1999; **34**: 1045 - 1049
- 27) Kawano M, Koshikawa T, Kanzaki T, Morisaki N, Saito Y, Yoshida S: Diabetes mellitus induces accelerated growth of aortic smooth muscle cells: Association with overexpression of PDGF beta-receptors. *Eur J Clin Invest* 1993; **23**: 84 - 90
- 28) Kanzaki T, Shinomiya M, Ueda S, Morisaki N, Saito Y, Yoshida S: Enhanced arterial intimal thickening after balloon catheter injury in diabetic animals accompanied by PDGF beta-receptor overexpression of aortic media. *Eur J Clin Invest* 1994; **24**: 377 - 381
- 29) Iwamoto Y, Kosaka K, Kuzuya T, Akanuma Y, Shigeta Y, Kaneko T: Effects of troglitazone: A new hypoglycemic agent in patients with NIDDM poorly controlled by diet therapy. *Diabetes Care* 1996; **19**: 151 - 156

- 30) Aronoff S, Rosenblatt S, Braithwaite S, Egan JW, Mathisen AL, Schneider RL, for the Pioglitazone 001 Study Group: Pioglitazone hydrochloride monotherapy improves glycemic control in the treatment of patients with type 2 diabetes: A 6-month randomized placebo-controlled dose-response study. *Diabetes Care* 2000; **23**: 1605 - 1611
- 31) Miyazaki Y, Mahankali A, Matsuda M, Glass L, Mahankali S, Ferrannini E, Cusi K, Mandarino LJ, DeFronzo RA: Improved glycemic control and enhanced insulin sensitivity in type 2 diabetic subjects treated with pioglitazone. *Diabetes Care* 2001; **24**: 710 - 719
- 32) Law RE, Meehan WP, Xi XP, Graf K, Wuthrich DA, Coats W, Faxon D, Hsueh WA: Troglitazone inhibits vascular smooth muscle cell growth and intimal hyperplasia. *J Clin Invest* 1996; **98**: 1897 - 1905
- 33) Shinohara E, Kihara S, Ouchi N, Funahashi T, Nakamura T, Yamashita S, Kameda-Takemura K, Matsuzawa Y: Troglitazone suppresses intimal formation following balloon injury in insulin-resistant Zucker fatty rats. *Atherosclerosis* 1998; **136**: 275 - 279
- 34) Yasunari K, Kohno M, Kano H, Yokokawa K, Minami M, Yoshikawa J: Mechanisms of action of troglitazone in the prevention of high glucose-induced migration and proliferation of cultured coronary smooth muscle cells. *Circ Res* 1997; **81**: 953 - 962
- 35) Yoshimoto T, Naruse M, Shizume H, Naruse K, Tanabe A, Tanaka M, Tago K, Irie K, Muraki T, Demura H, Zardi L: Vasculo-protective effects of insulin sensitizing agent pioglitazone in neointimal thickening and hypertensive vascular hypertrophy. *Atherosclerosis* 1999; **145**: 333 - 340
- 36) Igarashi M, Hirata A, Yamaguchi H, Tsuchiya H, Ohnuma H, Tominaga M, Daimon M, Kato T: Characterization of an inhibitory effect of pioglitazone in balloon-injured vascular smooth muscle cell growth. *Metabolism* 2001; **50**: 955 - 962
- 37) de Dios ST, Bruemmer D, Dilley RJ, Ivey ME, Jennings GL, Law RE, Little PJ: Inhibitory activity of clinical thiazolidinedione peroxisome proliferator activating receptor-gamma ligands toward internal mammary artery, radial artery, and saphenous vein smooth muscle cell proliferation. *Circulation* 2003; **107**: 2548 - 2550
- 38) Aizawa Y, Kawabe J, Hasebe N, Takehara N, Kikuchi K: Pioglitazone enhances cytokine-induced apoptosis in vascular smooth muscle cells and reduces intimal hyperplasia. *Circulation* 2001; **104**: 455 - 460
- 39) Ishibashi M, Egashira K, Hiasa K, Inoue S, Ni W, Zhao Q, Usui M, Kitamoto S, Ichiki T, Takeshita A: Antiinflammatory and antiarteriosclerotic effects of pioglitazone. *Hypertension* 2002; **40**: 687 - 693
- 40) Fonseca VA, Reynolds T, Hemphill D, Randolph C, Wall J, Valiquet TR, Graveline J, Fink LM: Effect of troglitazone on fibrinolysis and activated coagulation in patients with non-insulin-dependent diabetes mellitus. *J Diabetes Complications* 1998; **12**: 181 - 186
- 41) Haffner SM, Greenberg AS, Weston WM, Chen H, Williams K, Freed MI: Effect of rosiglitazone treatment on nontraditional markers of cardiovascular disease in patients with type 2 diabetes mellitus. *Circulation* 2002; **106**: 679 - 684
- 42) Satoh N, Ogawa Y, Usui T, Tagami T, Kono S, Uesugi H, Sugiyama H, Sugawara A, Yamada K, Shimatsu A, Kuzuya H, Nakao K: Antiatherogenic effect of pioglitazone in type 2 diabetic patients irrespective of the responsiveness to its antidiabetic effect. *Diabetes Care* 2003; **26**: 2493 - 2499
- 43) Choi D, Kim SK, Choi SH, Ko YG, Ahn CW, Jang Y, Lim SK, Lee HC, Cha BS: Preventative effects of rosiglitazone on restenosis after coronary stent implantation in patients with type 2 diabetes. *Diabetes Care* 2004; **27**: 2654 - 2660